



<https://www.youtube.com/c/vikramdeshpandePathology>

**@Vik\_Deshpande**



MASSACHUSETTS  
GENERAL HOSPITAL



HARVARD  
MEDICAL SCHOOL

# **GISTs and All Thing Mesenchymal in the Gastrointestinal Tract**

***Vikram Deshpande, M.D.***

***Professor of Pathology***

***Harvard Medical School***

**Pathologist**

**Director of GI pathology**

**Beth Israel Deaconess Medical Center**

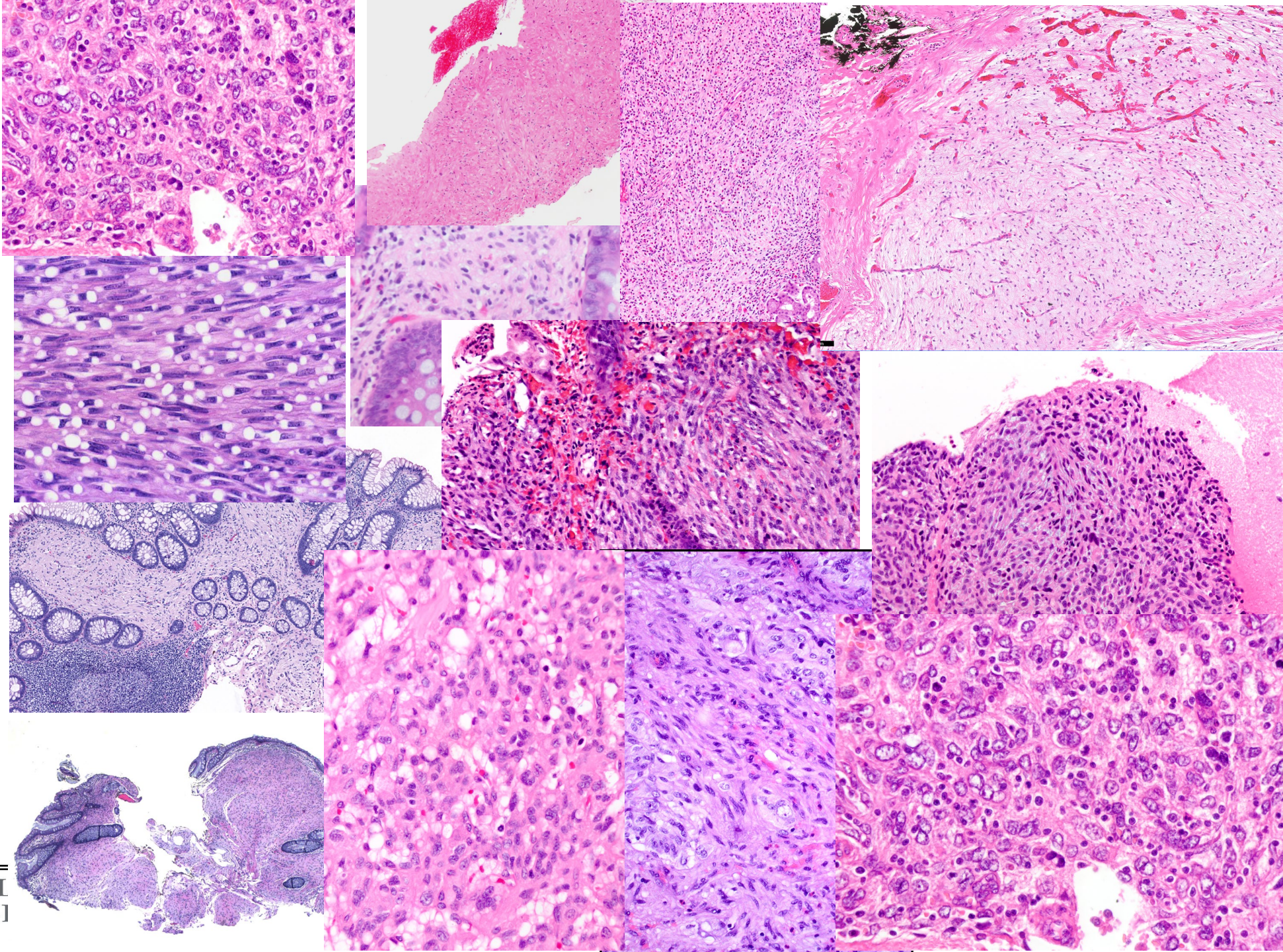
**Editor-in-Chief**

**Journal of Clinical Pathology**

**[vikramdirdeshpande@gmail.com](mailto:vikramdirdeshpande@gmail.com)**









Location

Location

Location



# Esophagus

**Mucosa**

Granular cell tumor  
Melanoma

Leiomyoma

**Submucosa**

**Muscularis**

Leiomyoma  
GIST

**Serosa**



# Stomach

**Mucosa**

Melanoma

**Submucosa**

Inflammatory fibroid polyp

**Muscularis**

GIST, Glomus, plexiform fibromyxoma, Schwannoma, gastroblastoma  
Gastrointestinal clear cell sarcoma / malignant gastrointestinal  
neuroectodermal tumor

**Serosa**

# Small Bowel

**Mucosa**

Melanoma

**Submucosa**

Gangliocytic paraganglioma (CoGNET)

Inflammatory fibroid polyp

**Muscularis**

GIST

Gastrointestinal clear cell sarcoma / malignant gastrointestinal neuroectodermal tumor

**Serosa**

Fibromatosis, sclerosing mesenteritis, IgG4-related disease, inflammatory myofibroblastic tumor

# Colon

**Mucosa**

Schwann cell hamartoma, Perineurioma, Ganglioneuroma, melanoma

Leiomyoma

**Submucosa**

Inflammatory fibroid polyp

**Muscularis**

GIST  
Gastrointestinal clear cell sarcoma / malignant gastrointestinal neuroectodermal tumor

**Serosa**

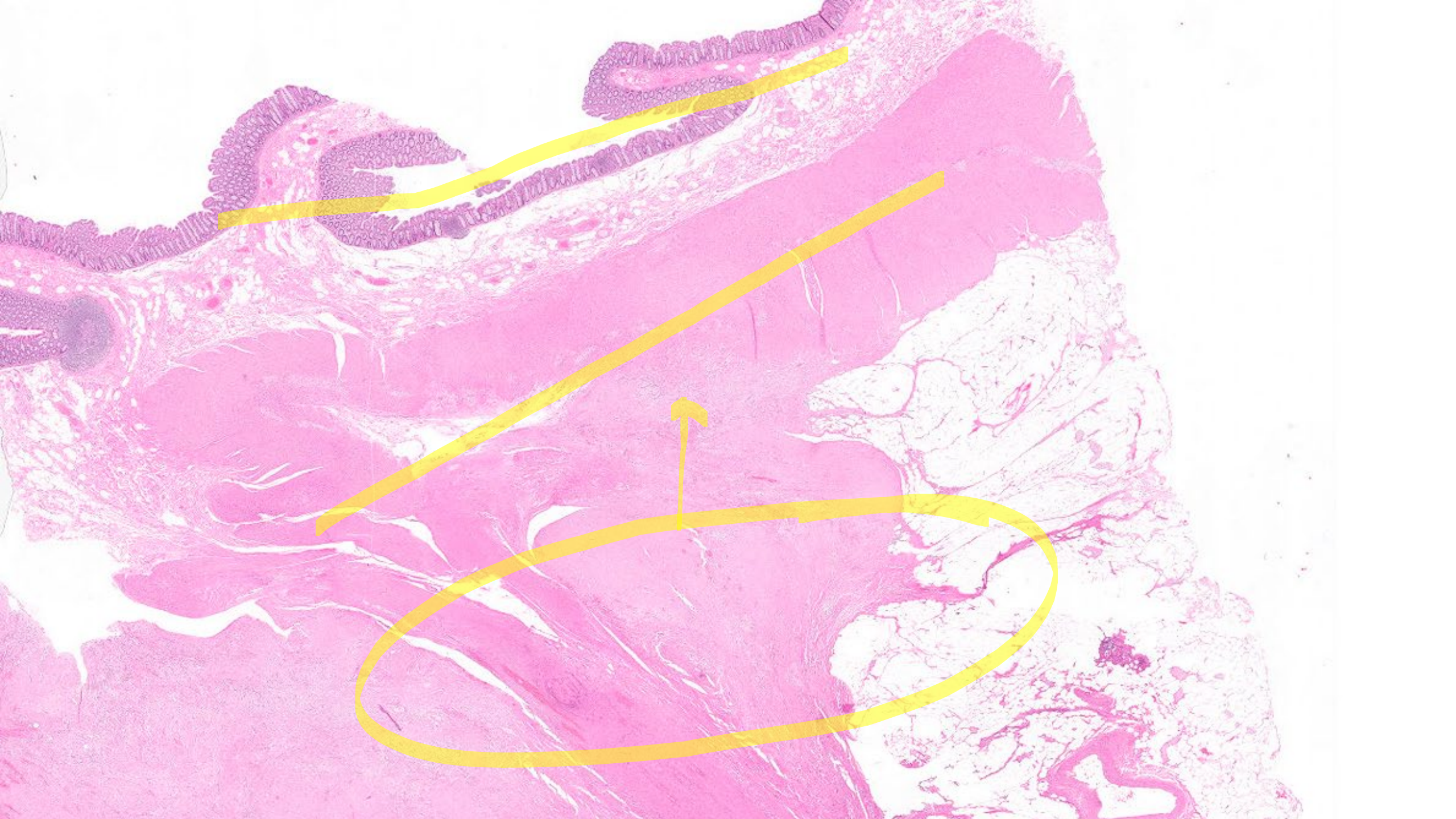Fibromatosis, sclerosing mesenteritis, IgG4-related disease, inflammatory myofibroblastic tumor

# Serosal-based

With or without involvement of the muscularis  
propria

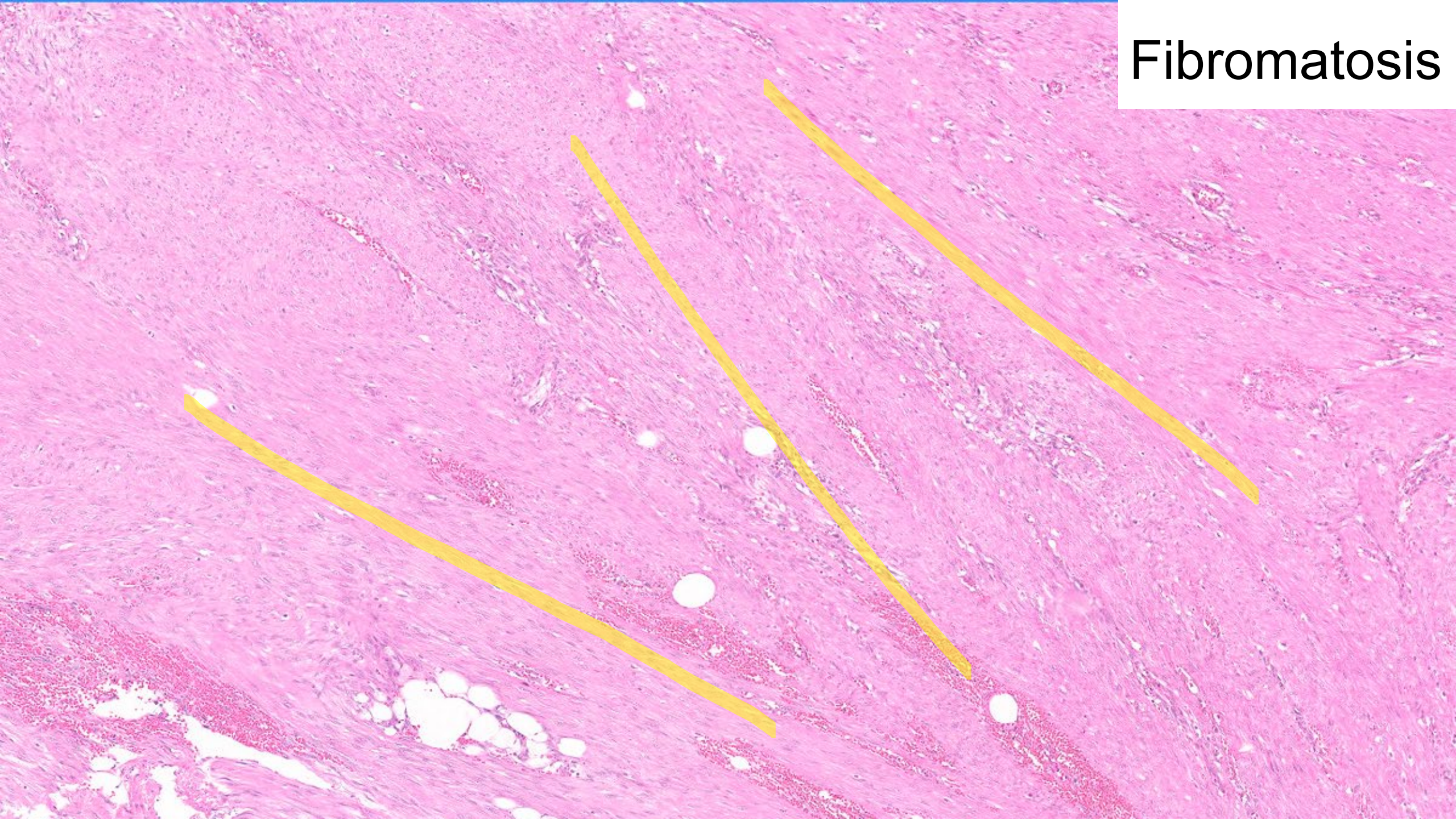






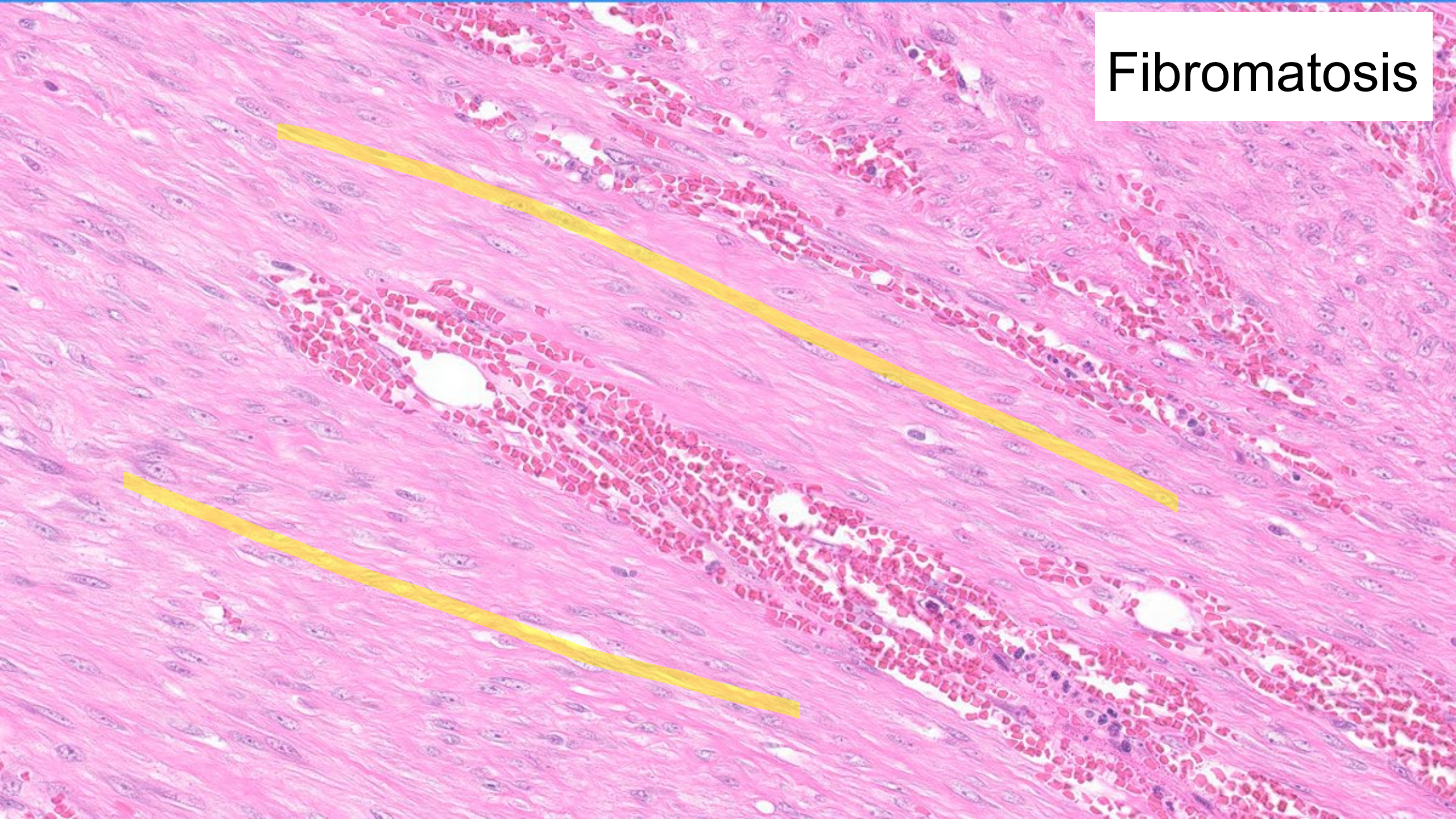


# Fibromatosis





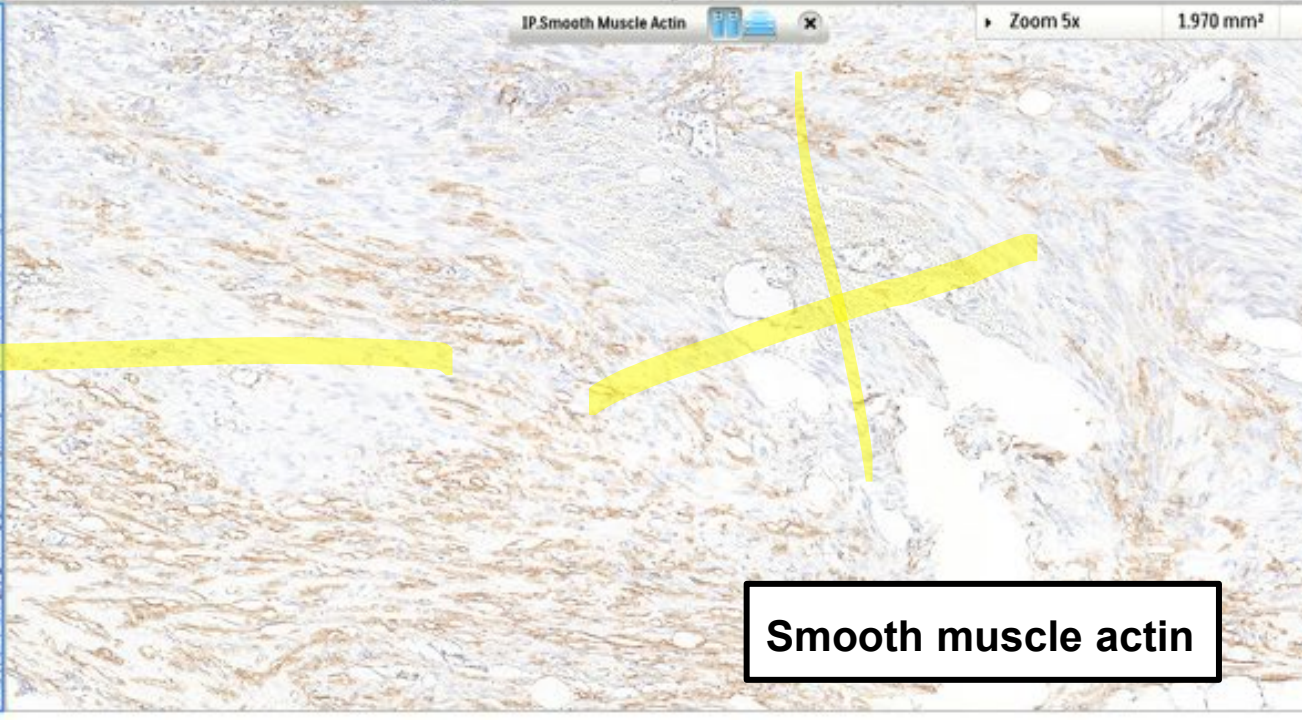

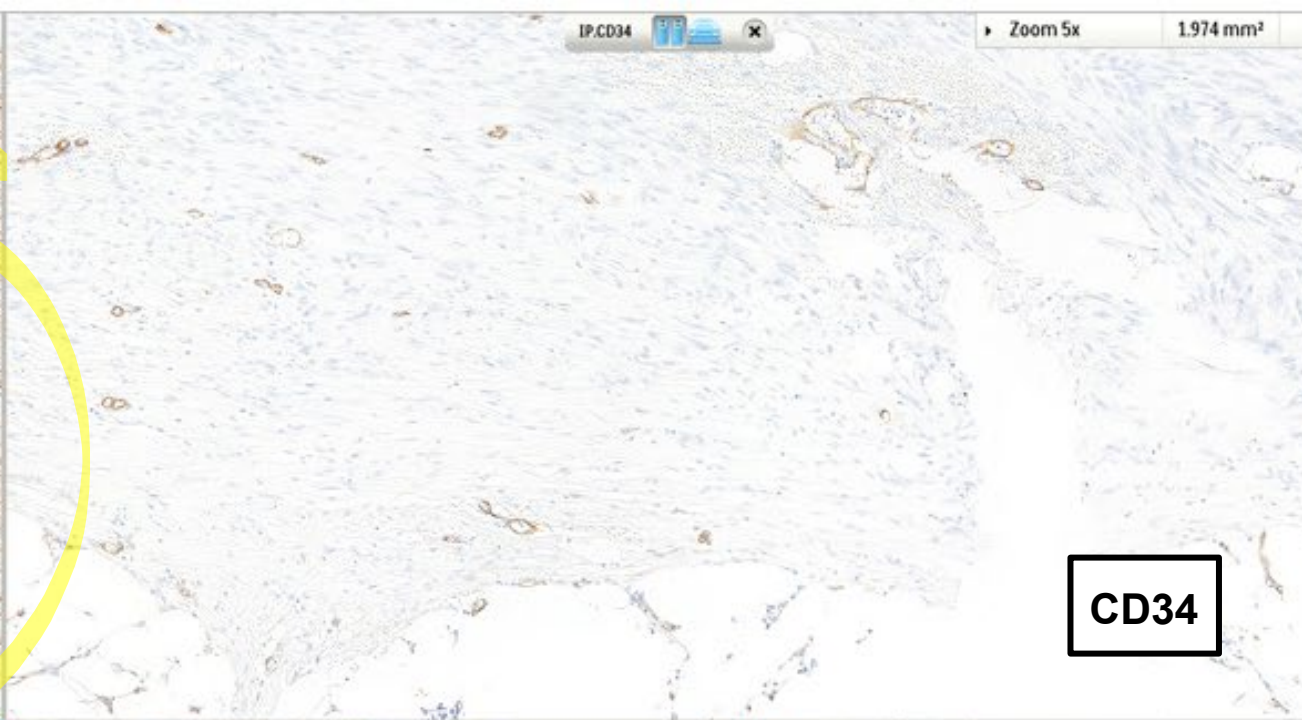
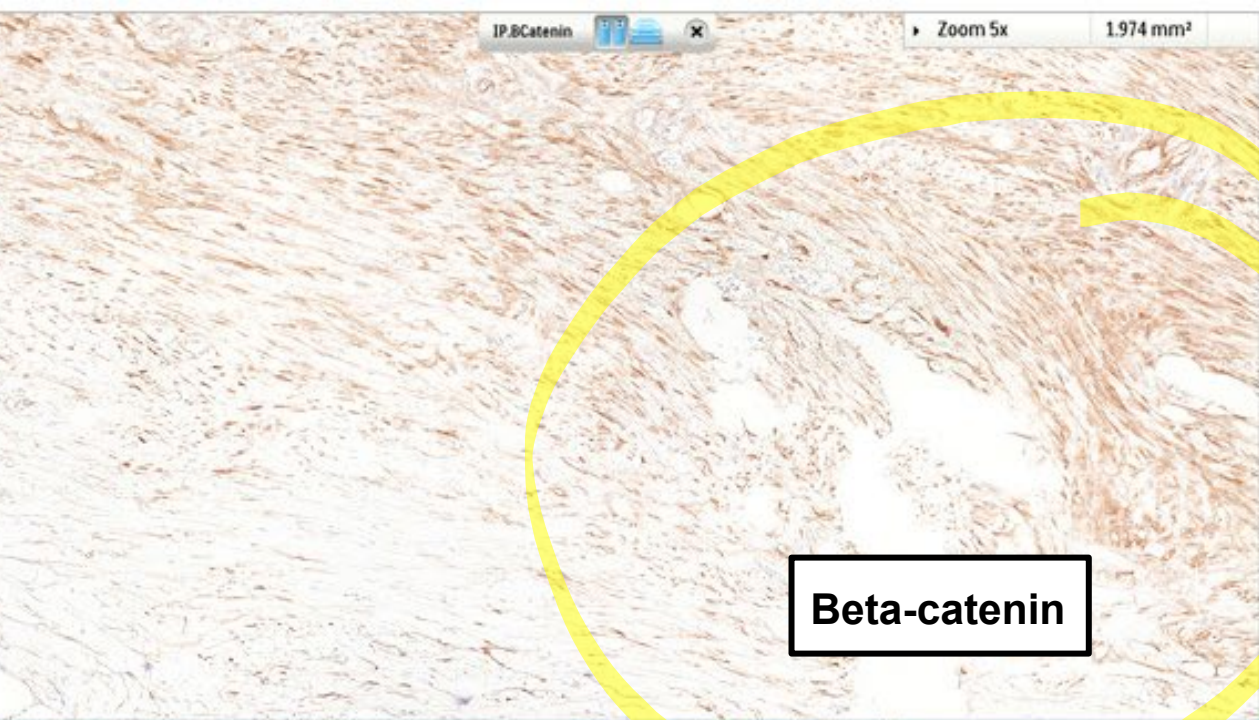
# Fibromatosis





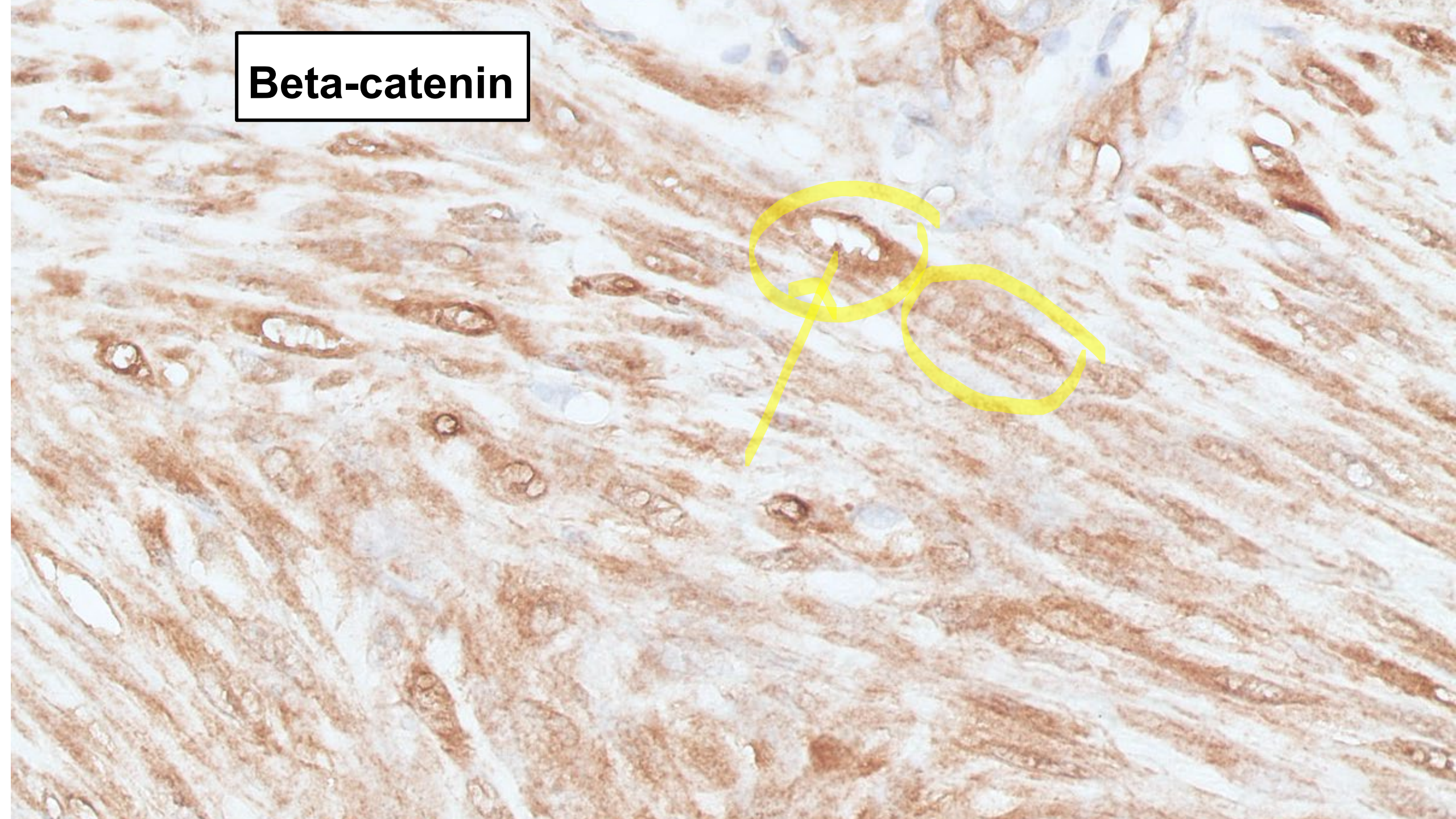






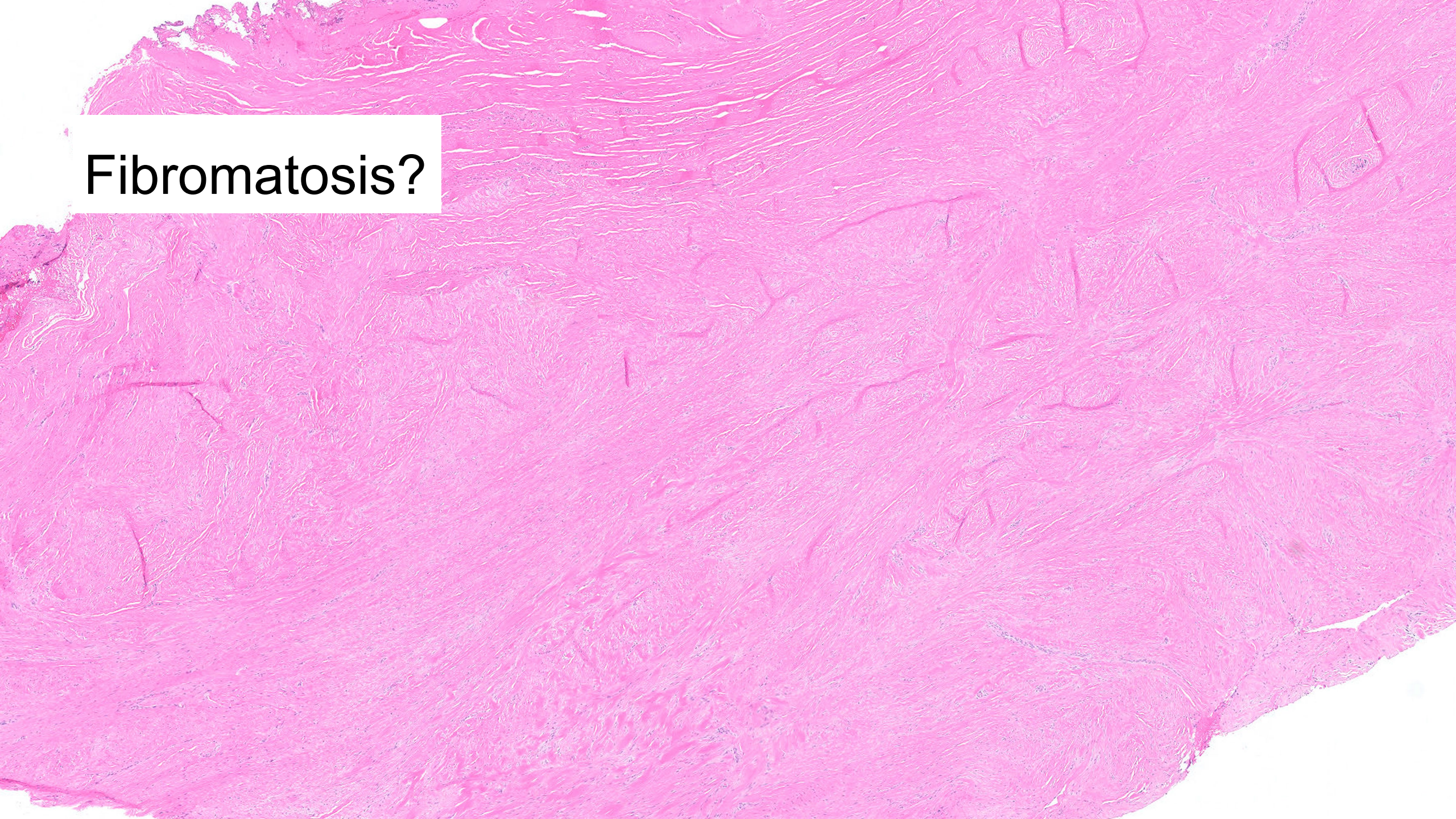
**Beta-catenin**

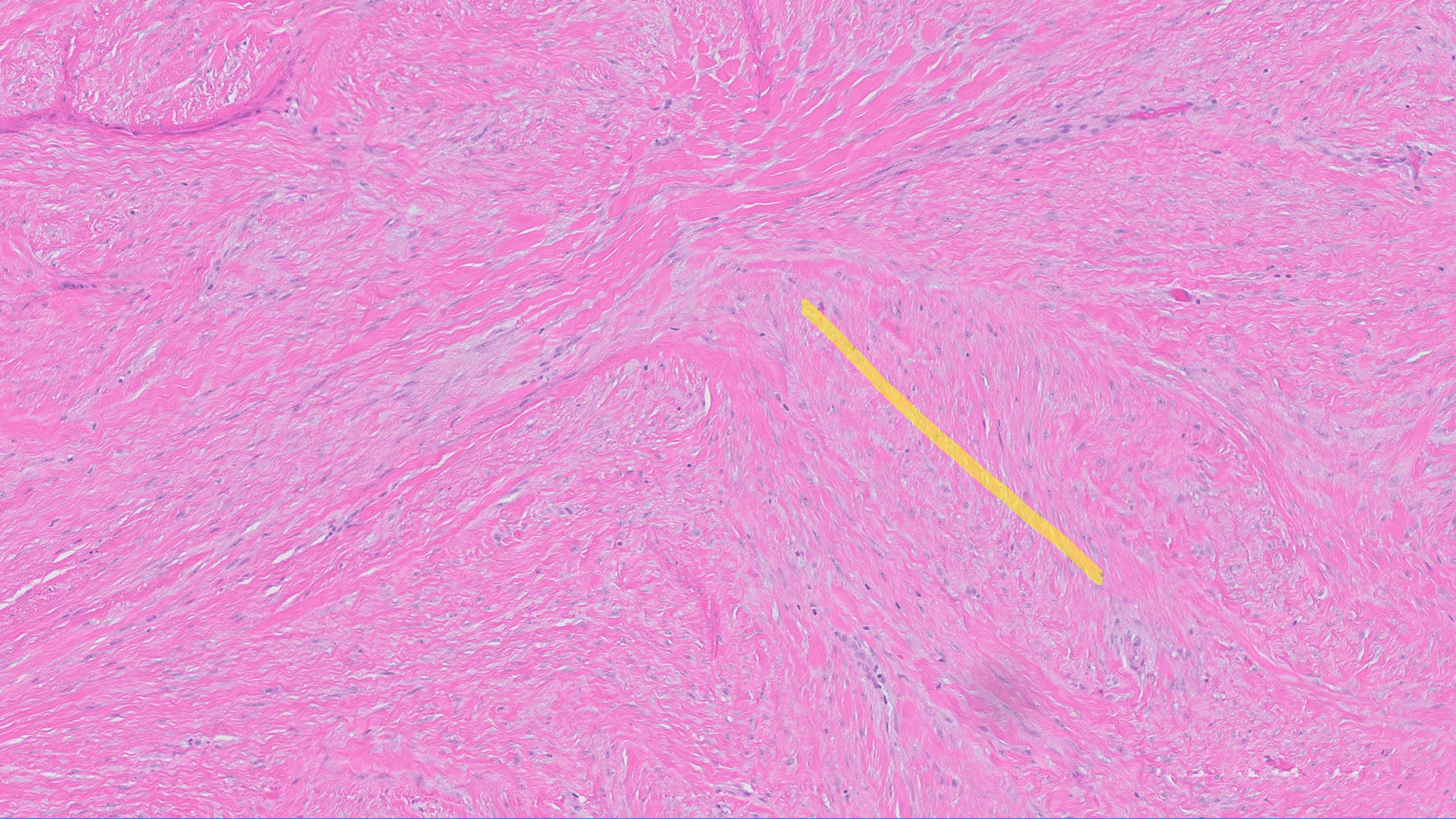




**Fibromatosis?**







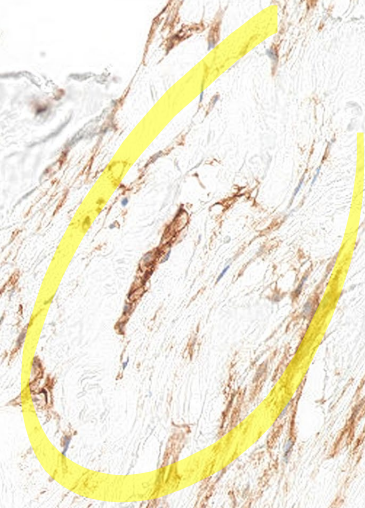




**Fibromatosis?**



**Beta-catenin**



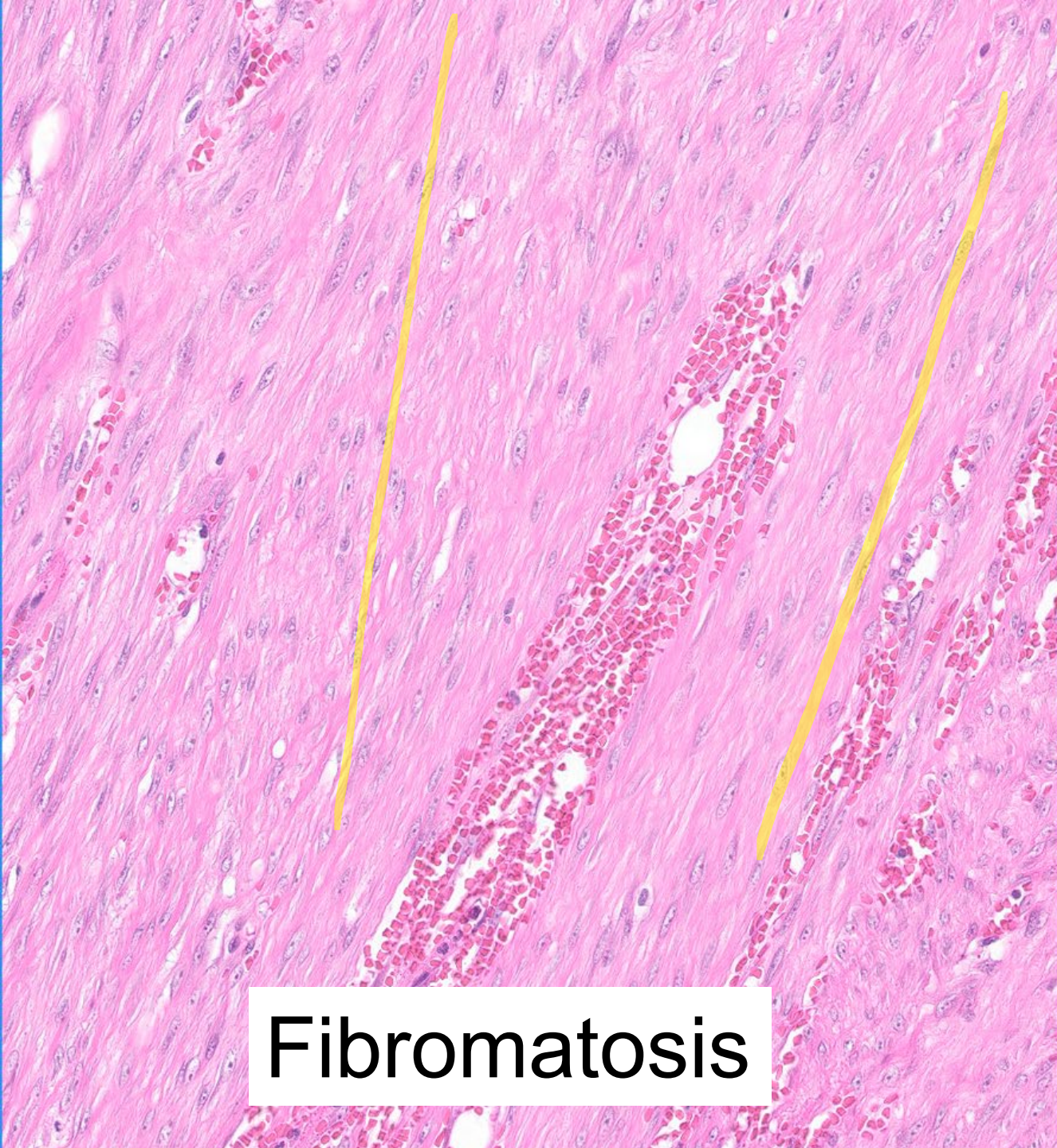


A histological section of scar tissue stained with hematoxylin and eosin (H&E). The image shows a dense, fibrous structure with numerous collagen fibers and scattered nuclei of fibroblasts and other cells. The overall appearance is that of a well-developed, organized scar tissue.

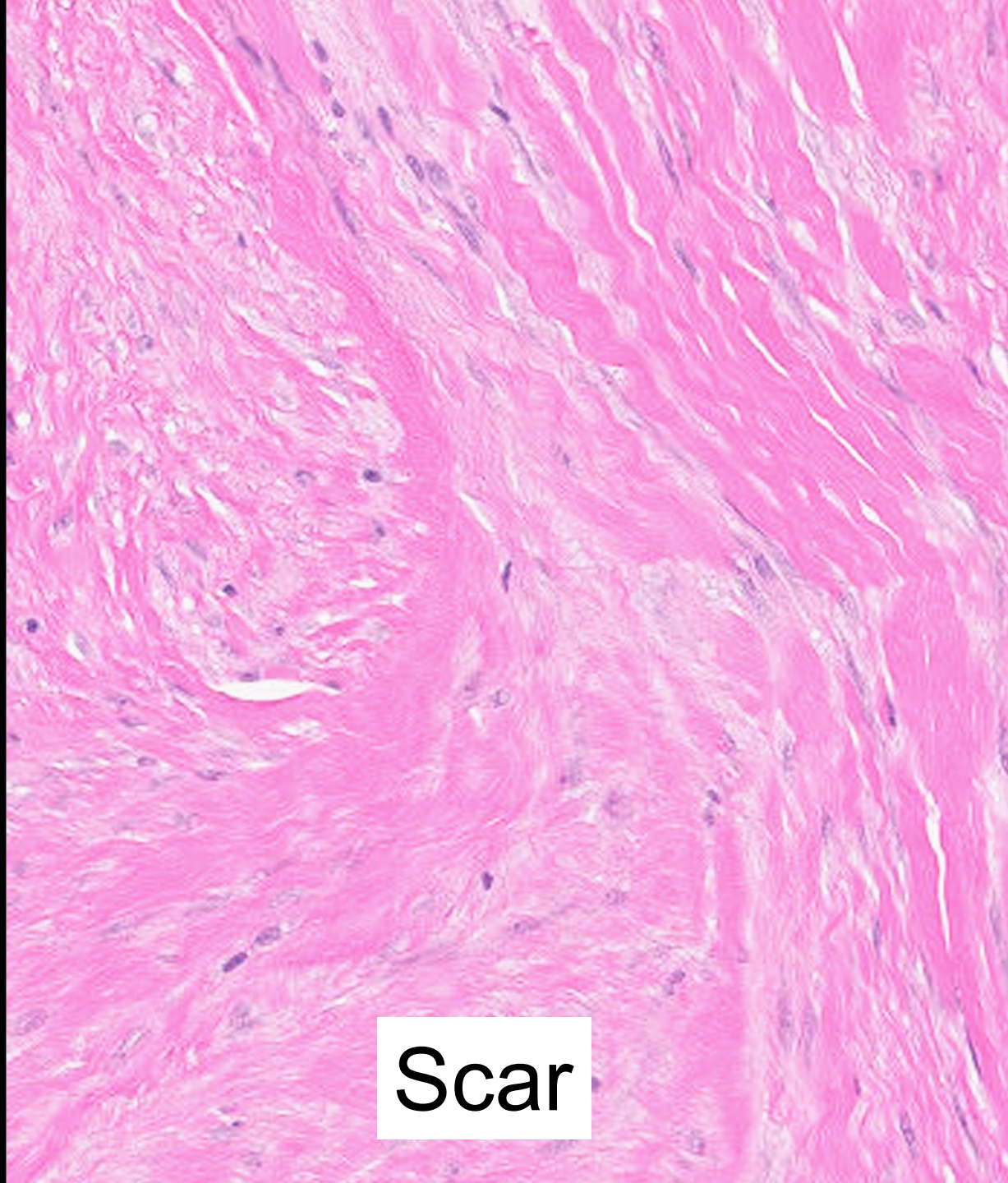Scar tissue

Negative for *CTNNB1* mutation





**Fibromatosis**



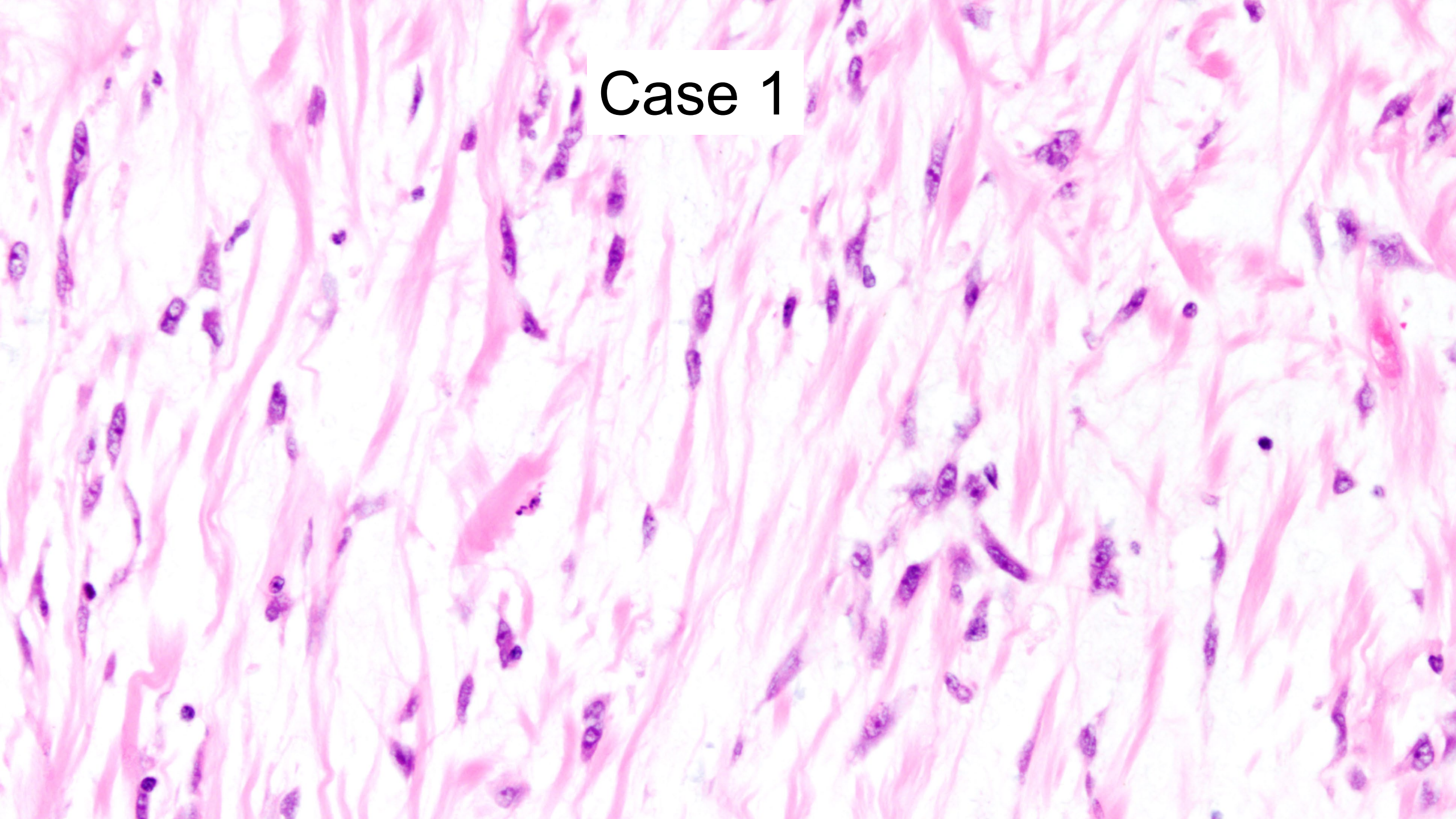
**Scar**



# Serosal surface

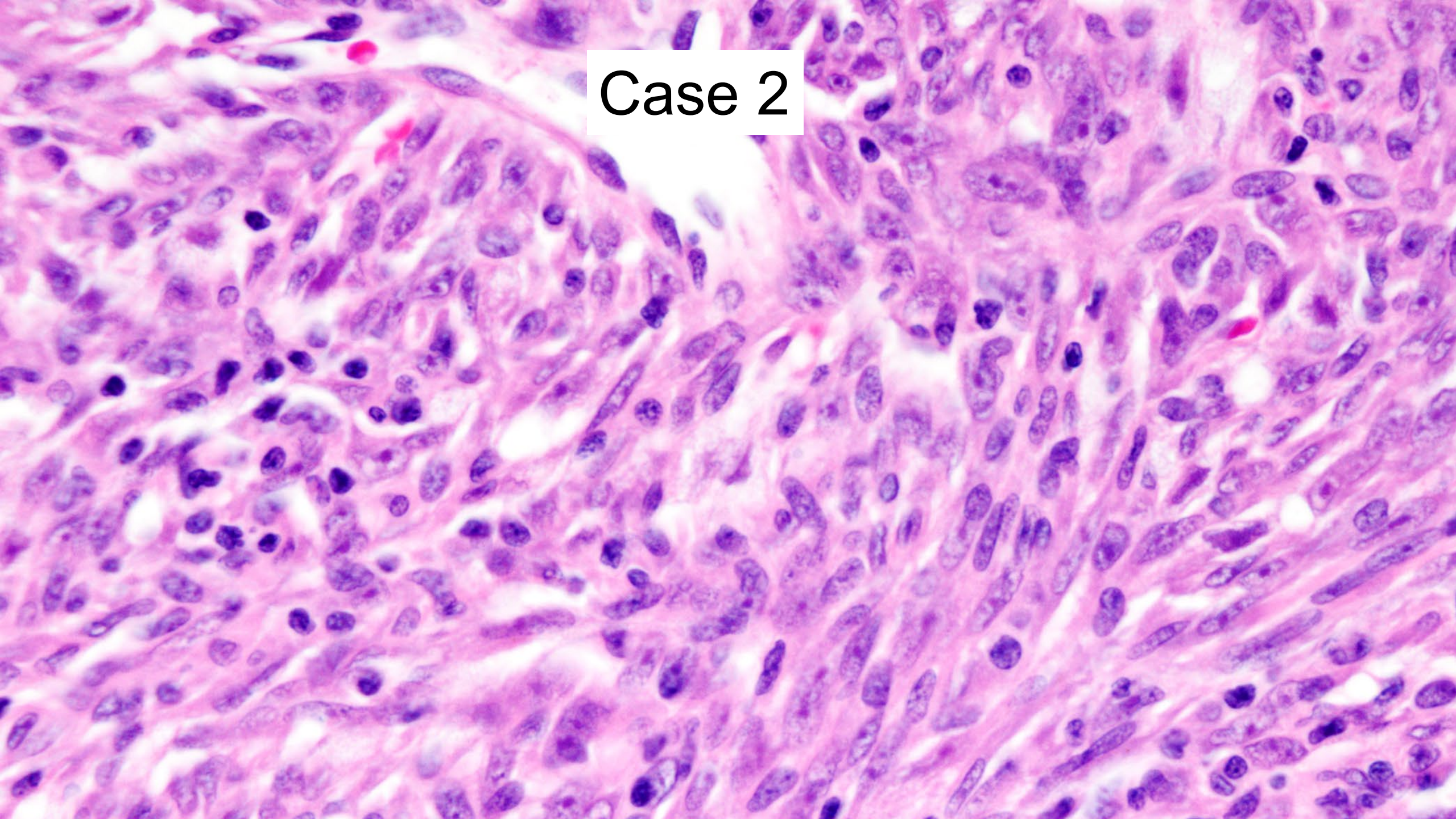


# Case 1





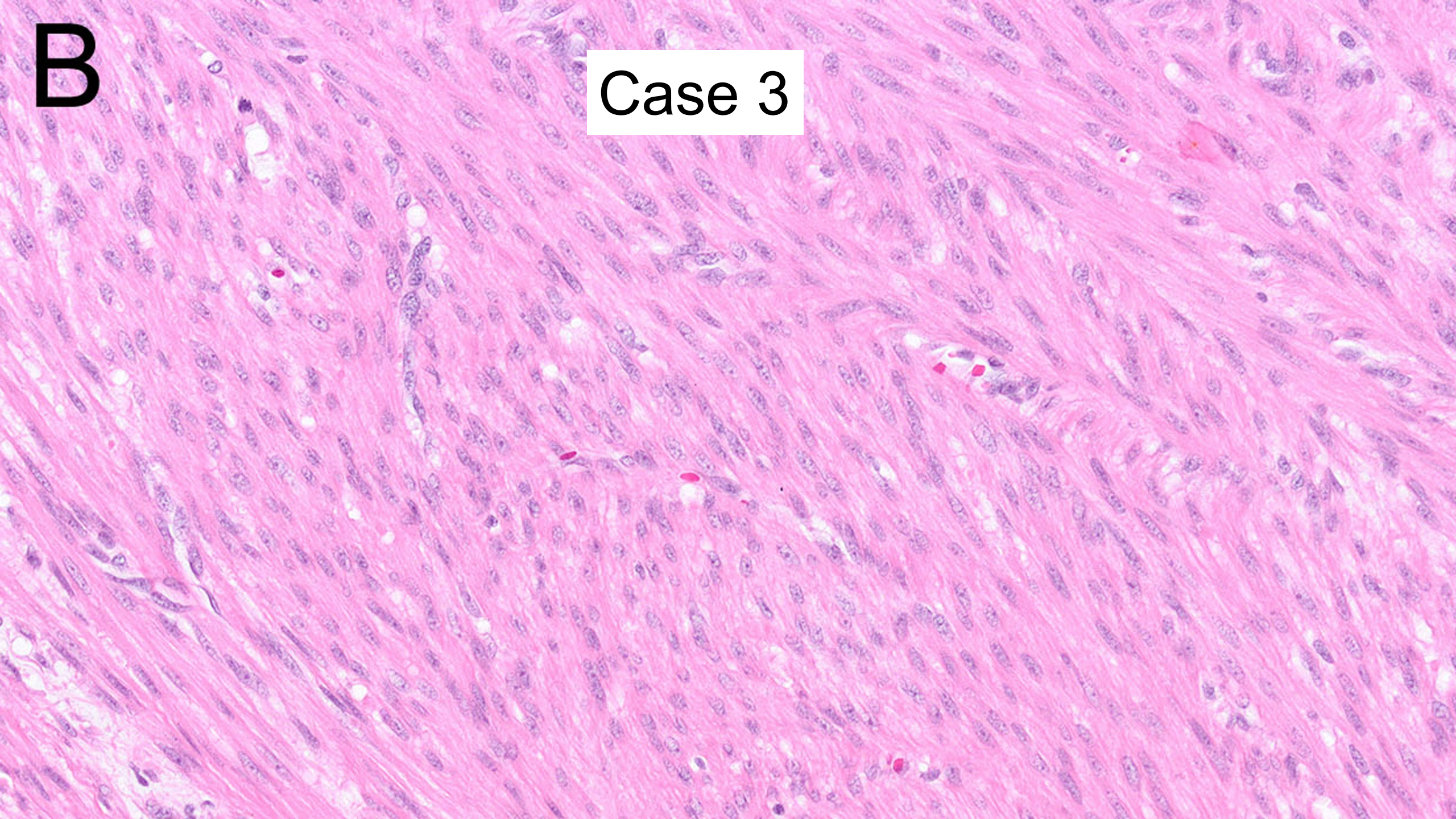
# Case 2





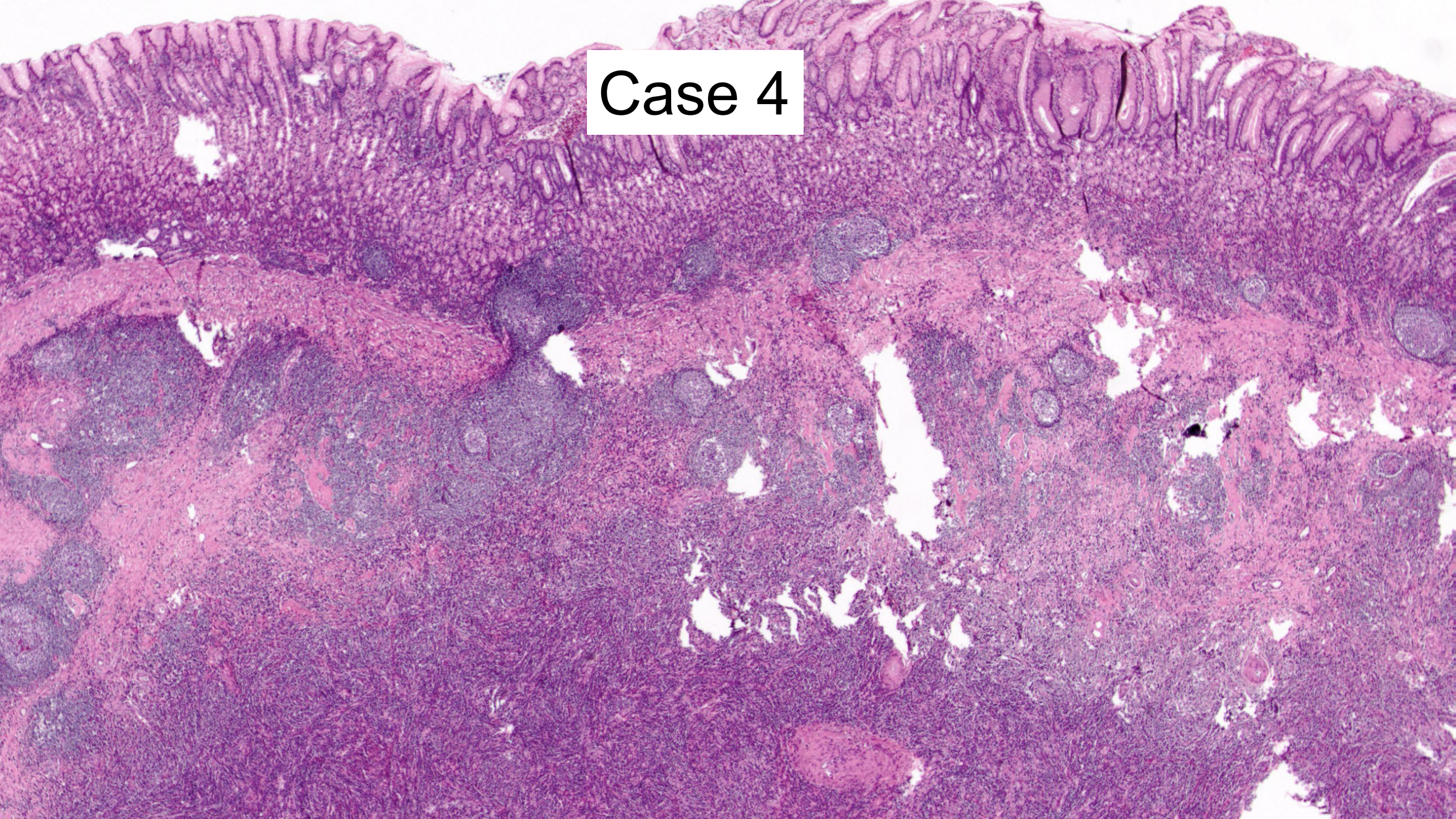
**B**

Case 3



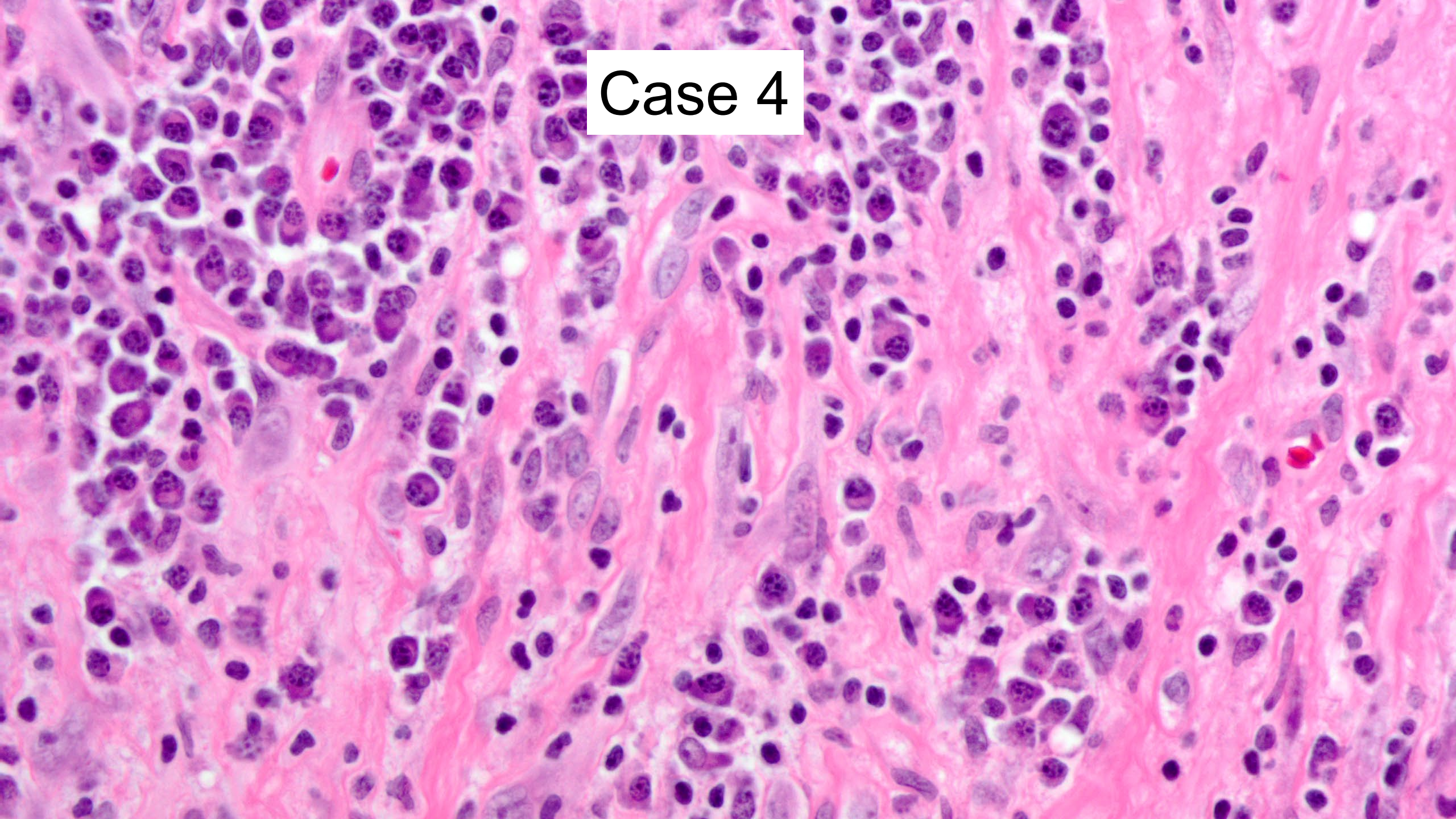


Case 4



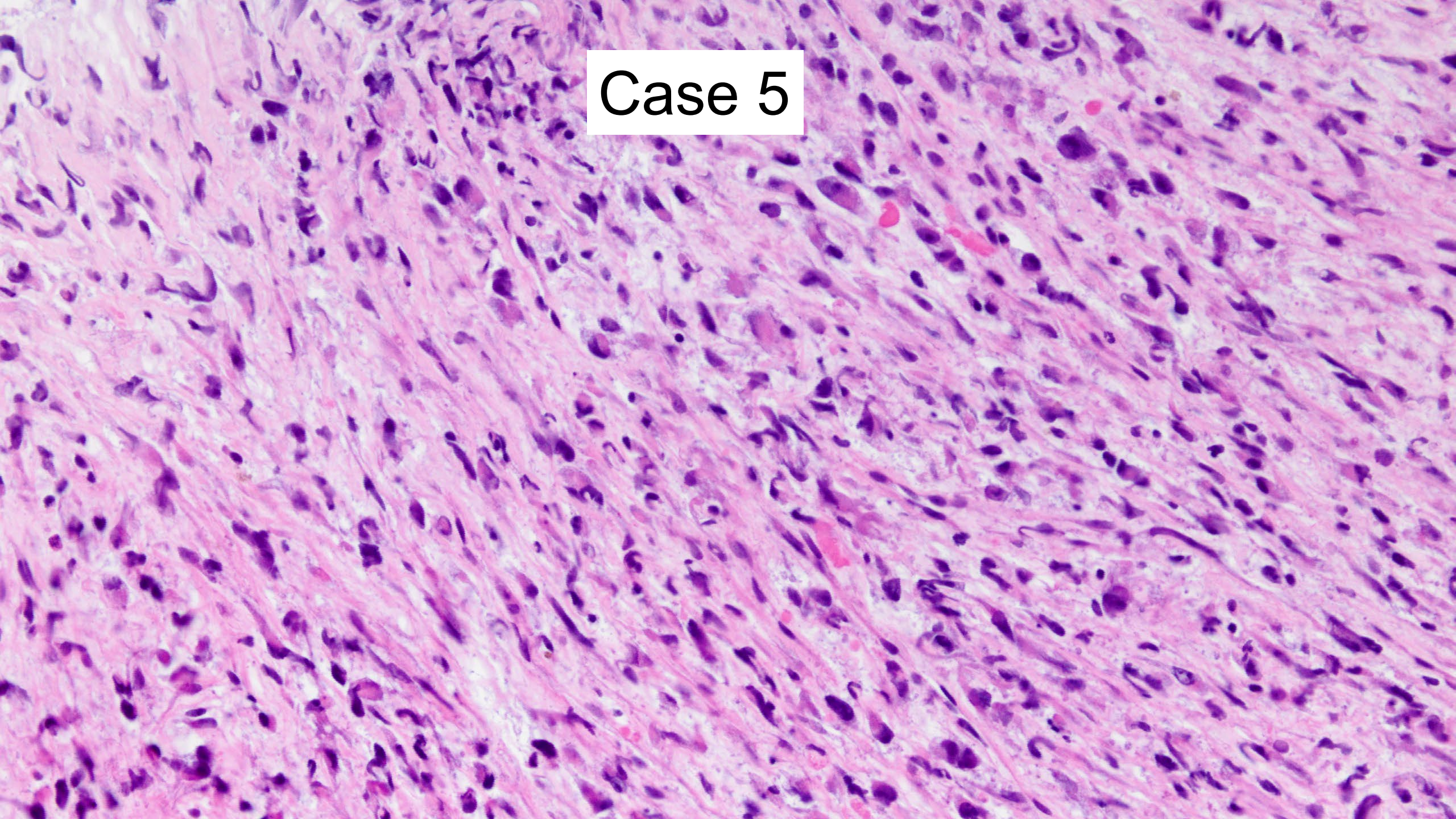


# Case 4



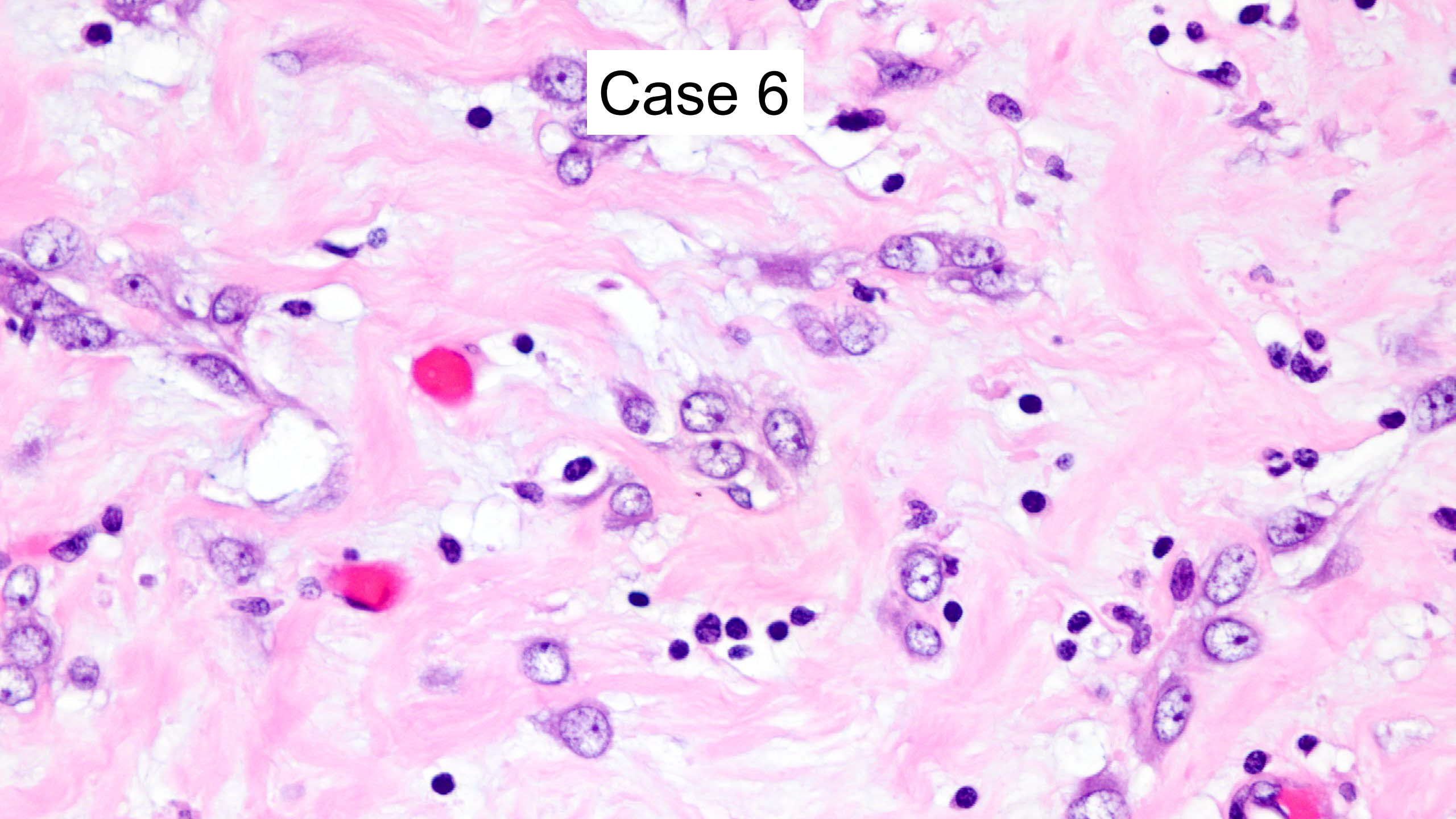


Case 5






Case 6



# Diagnosis



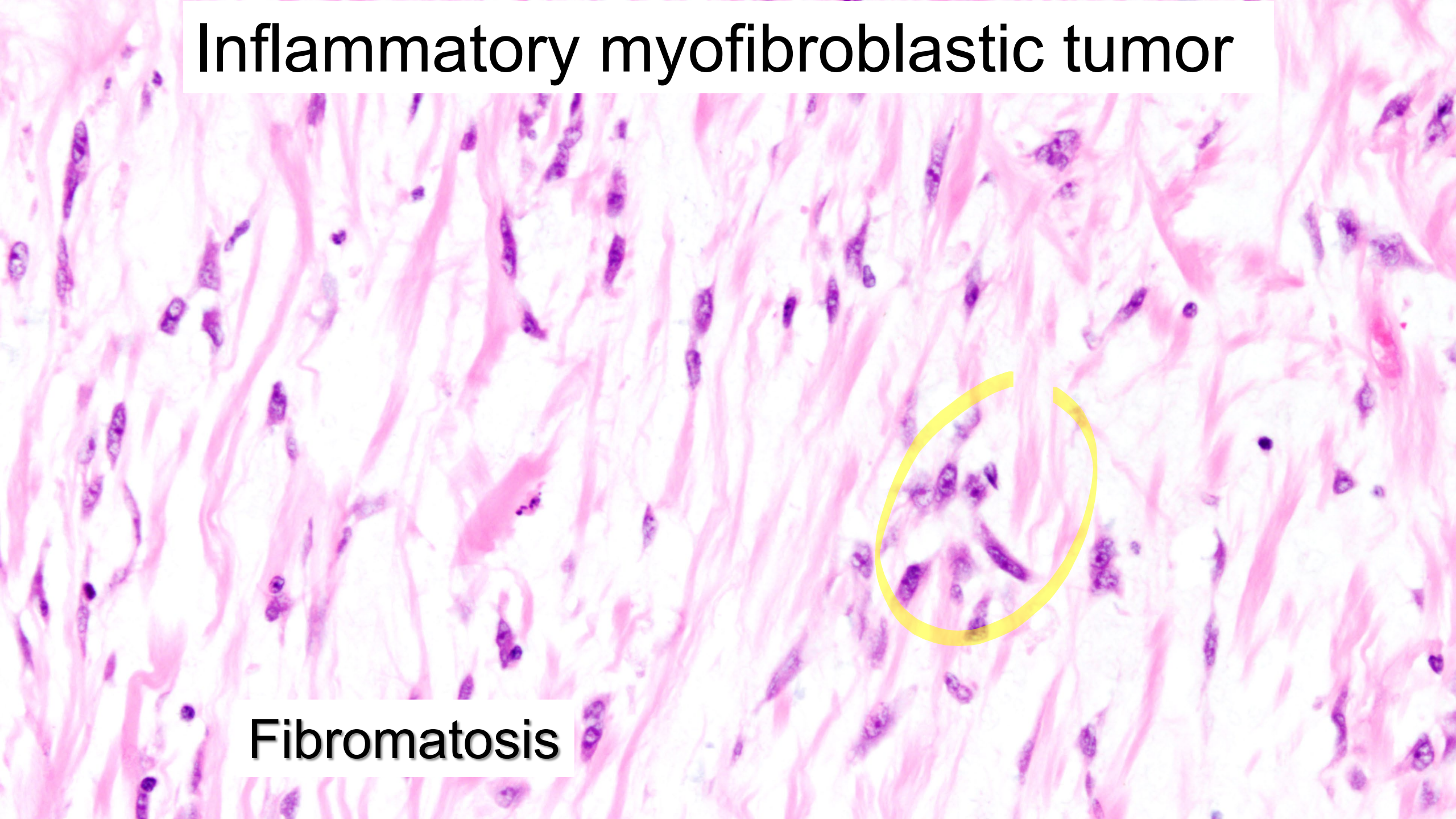
# Inflammatory Myofibroblastic Tumor

Serosal-based tumor





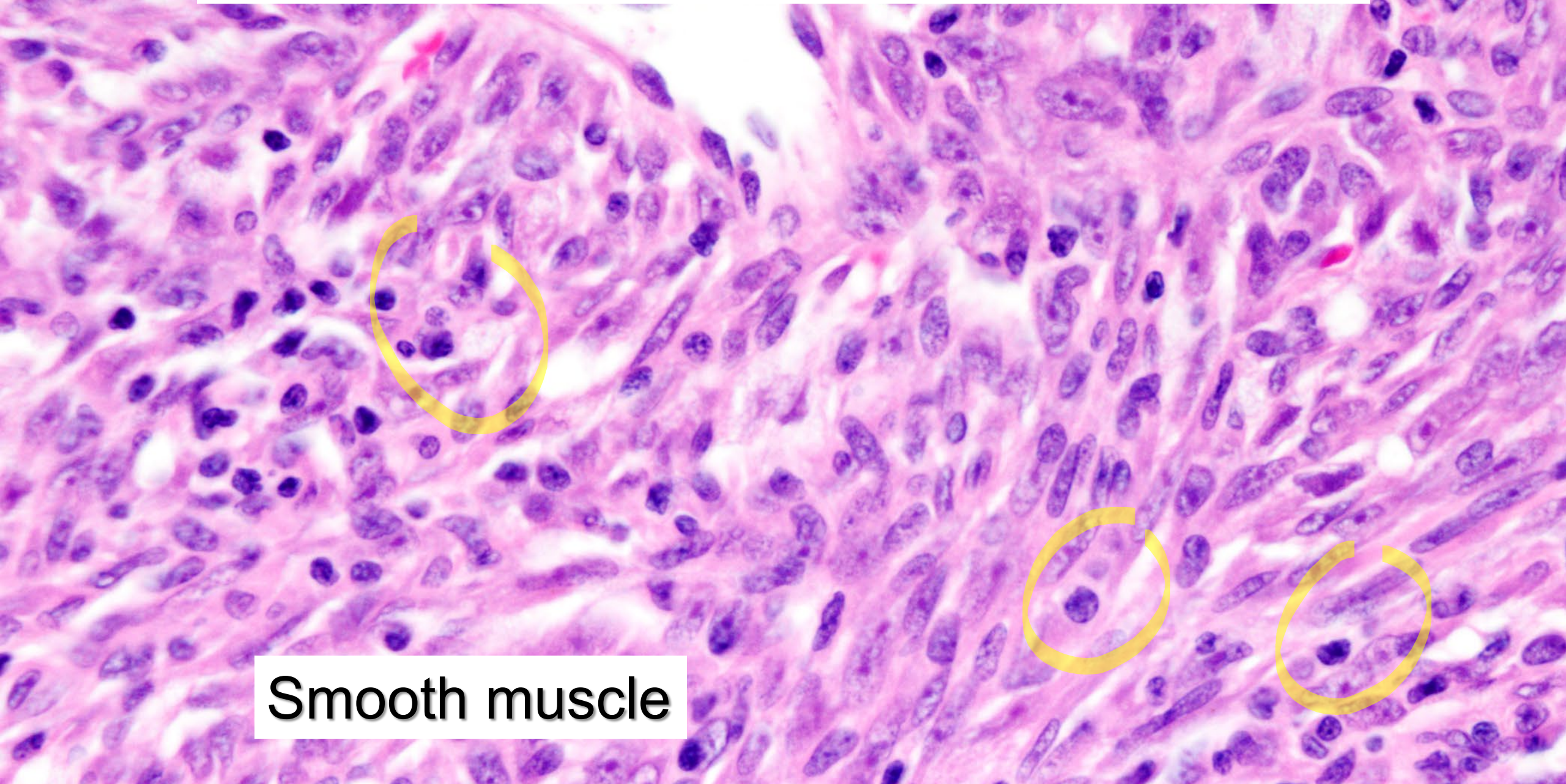
# Inflammatory myofibroblastic tumor



**Fibromatosis**

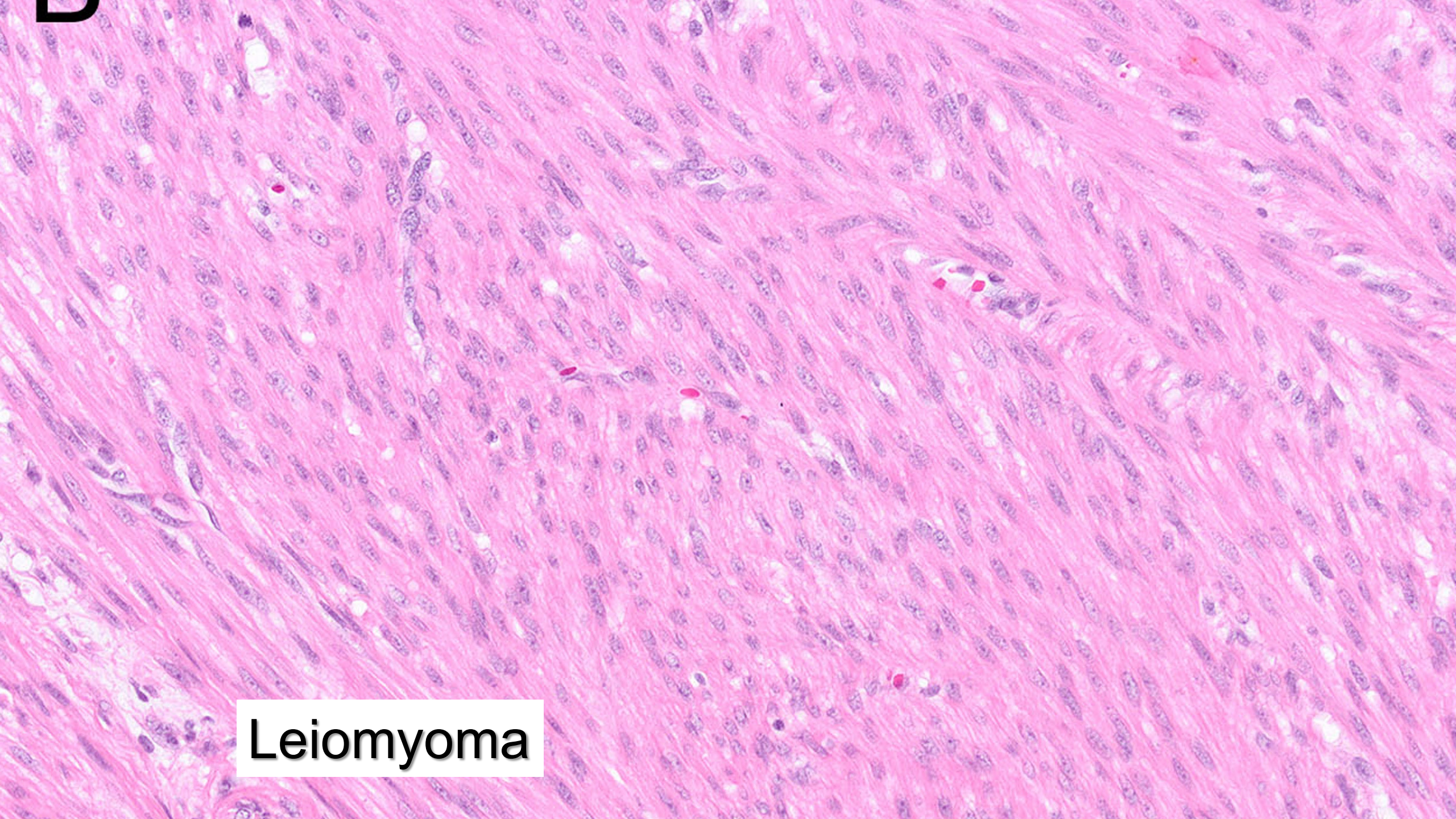


# Inflammatory myofibroblastic tumor



Smooth muscle





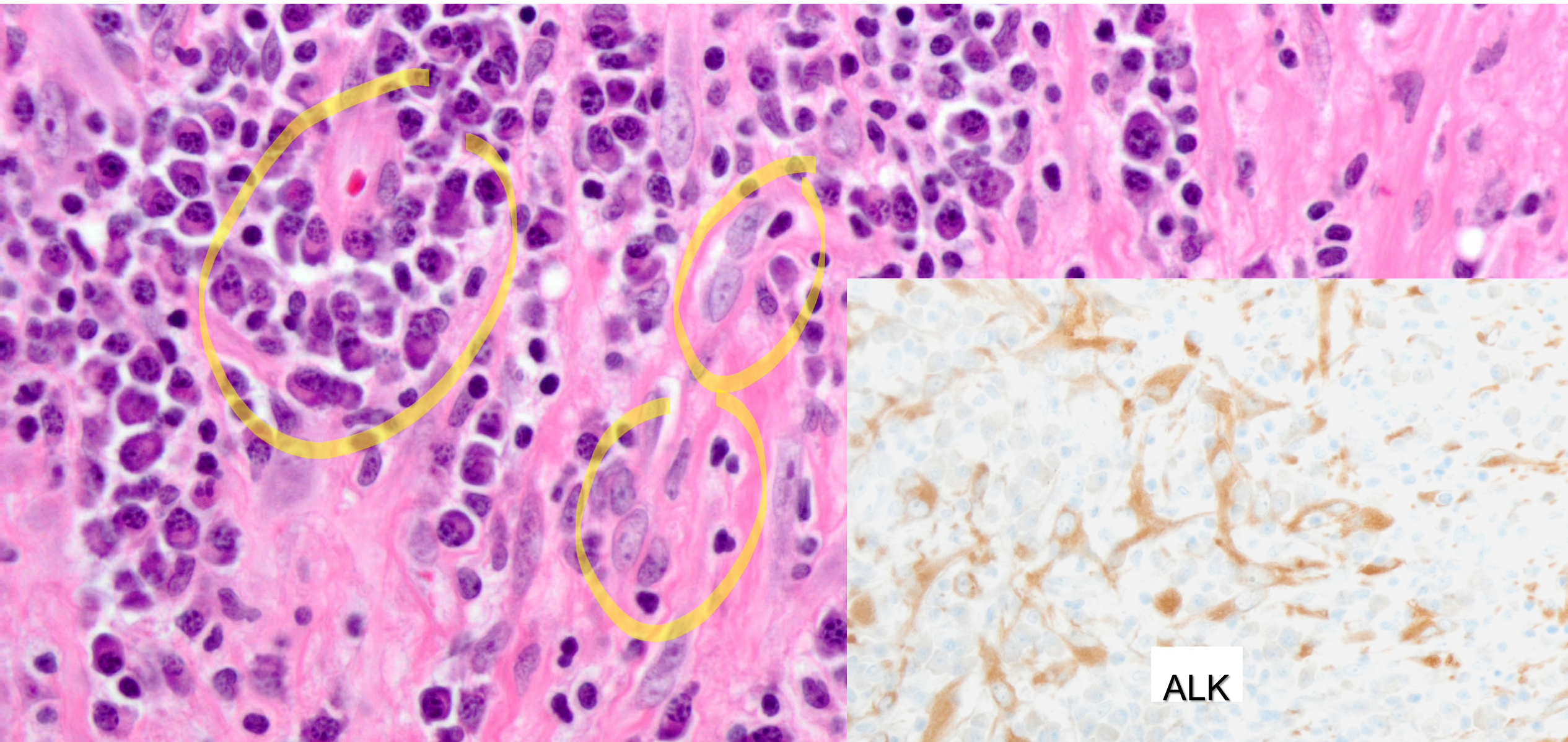
**Leiomyoma**



- Devins KM, Samore W, Nielsen GP, Deshpande V, Oliva E. Leiomyoma-like Morphology in Metastatic Uterine Inflammatory Myofibroblastic Tumors. *Mod Pathol*. 2023 Feb 18;36(6):100143. doi: 10.1016/j.modpat.2023.100143. Epub ahead of print. PMID: 36806735.

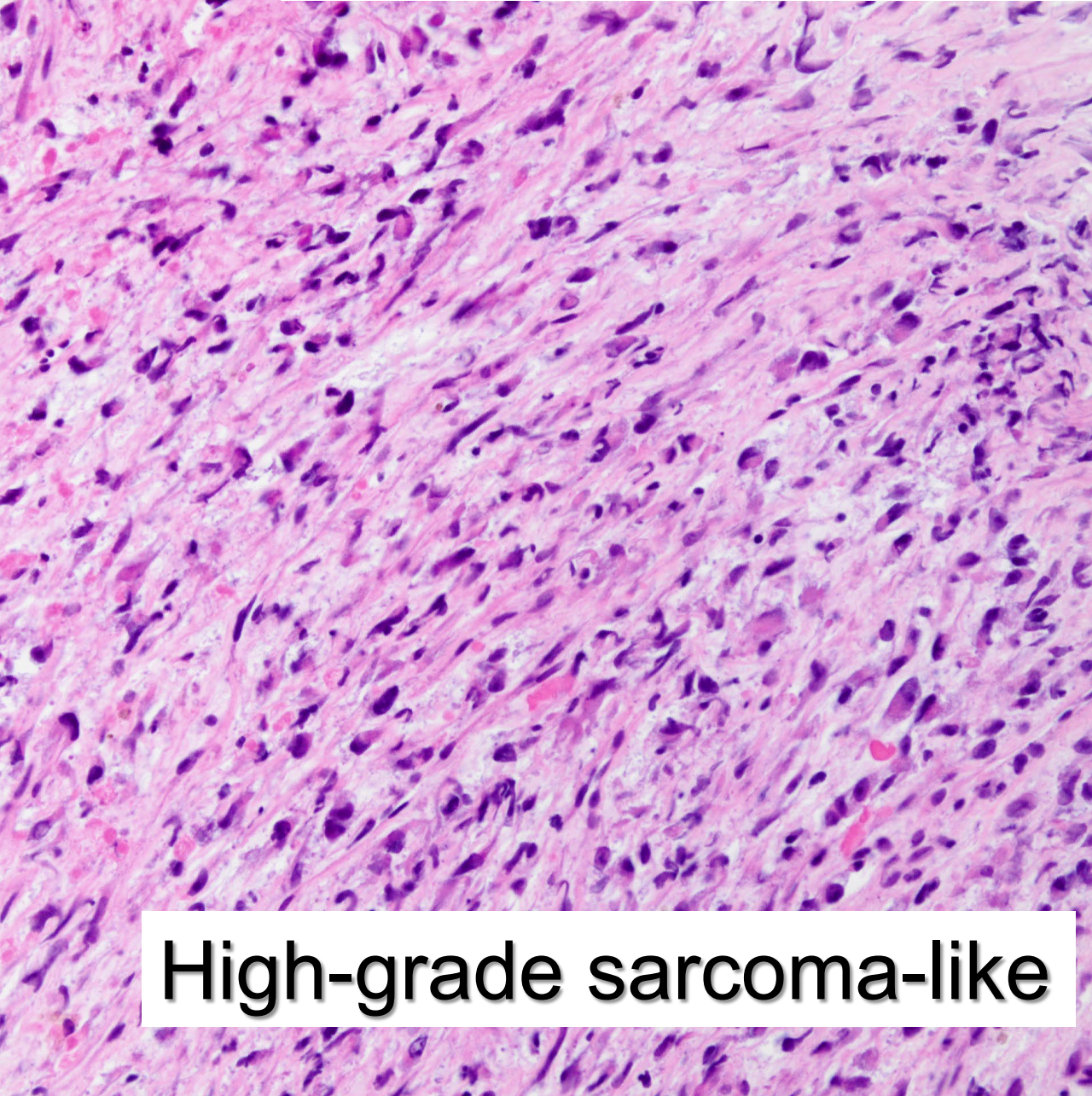


# (Super) Inflammatory myofibroblastic tumor

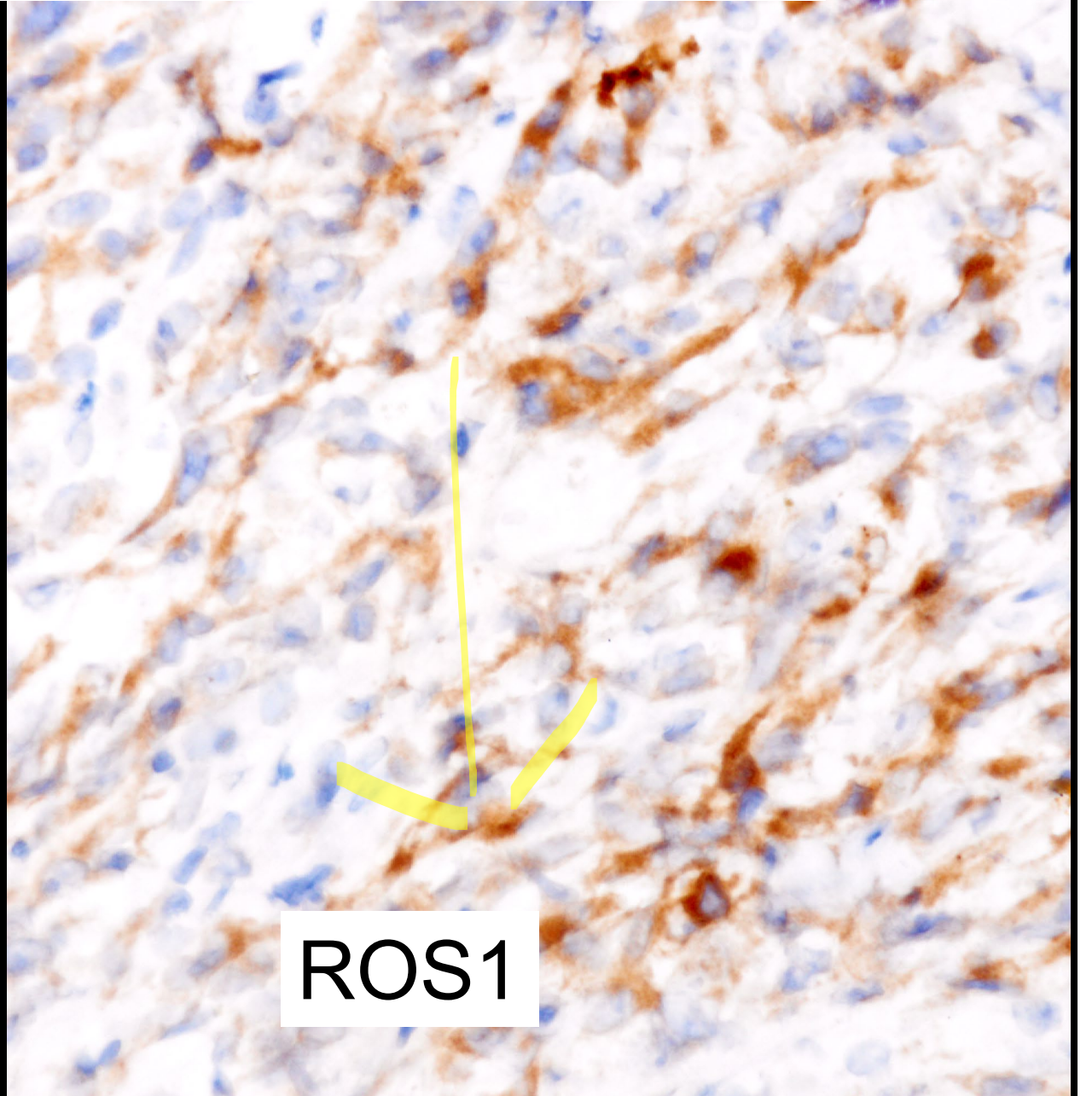




# Inflammatory myofibroblastic tumor



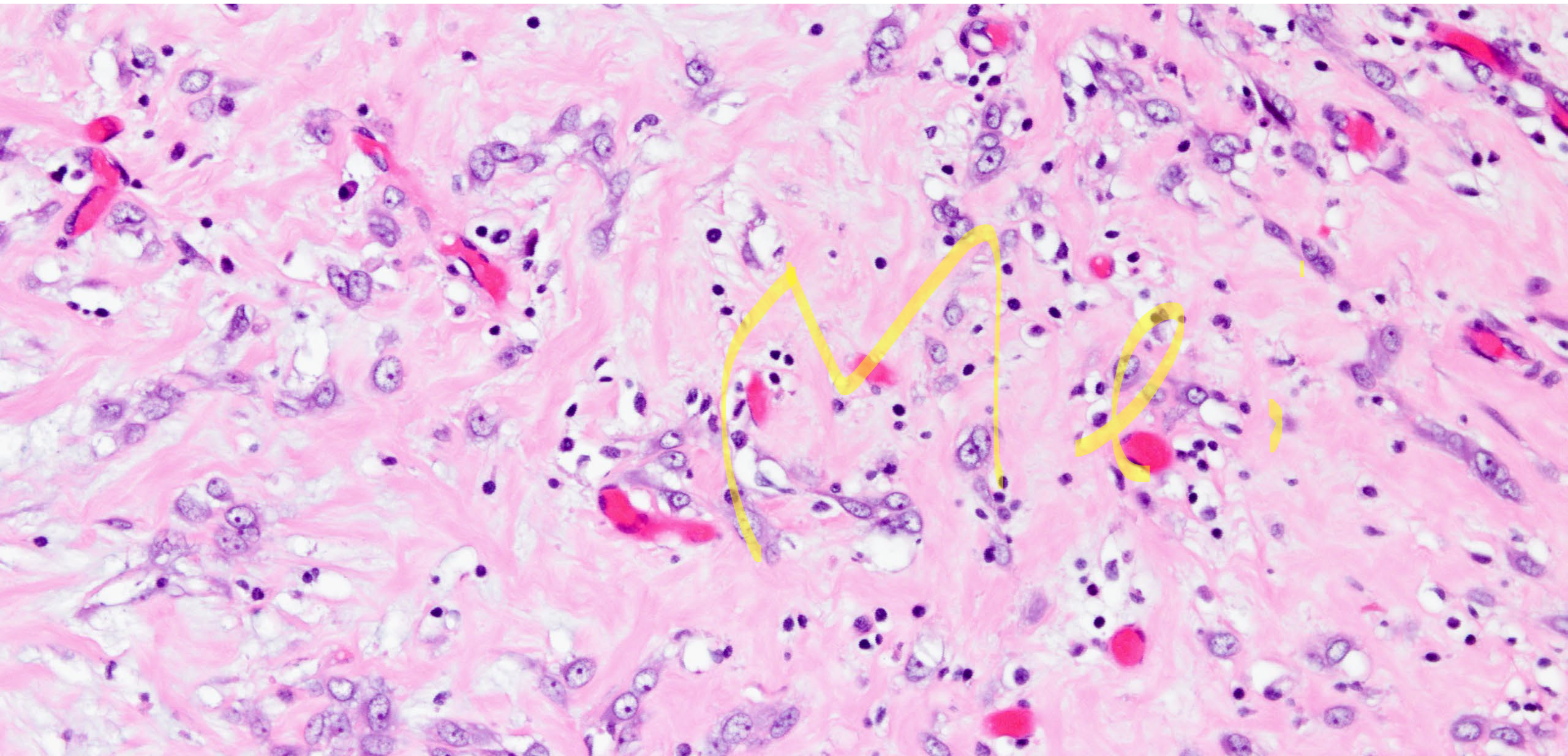
High-grade sarcoma-like



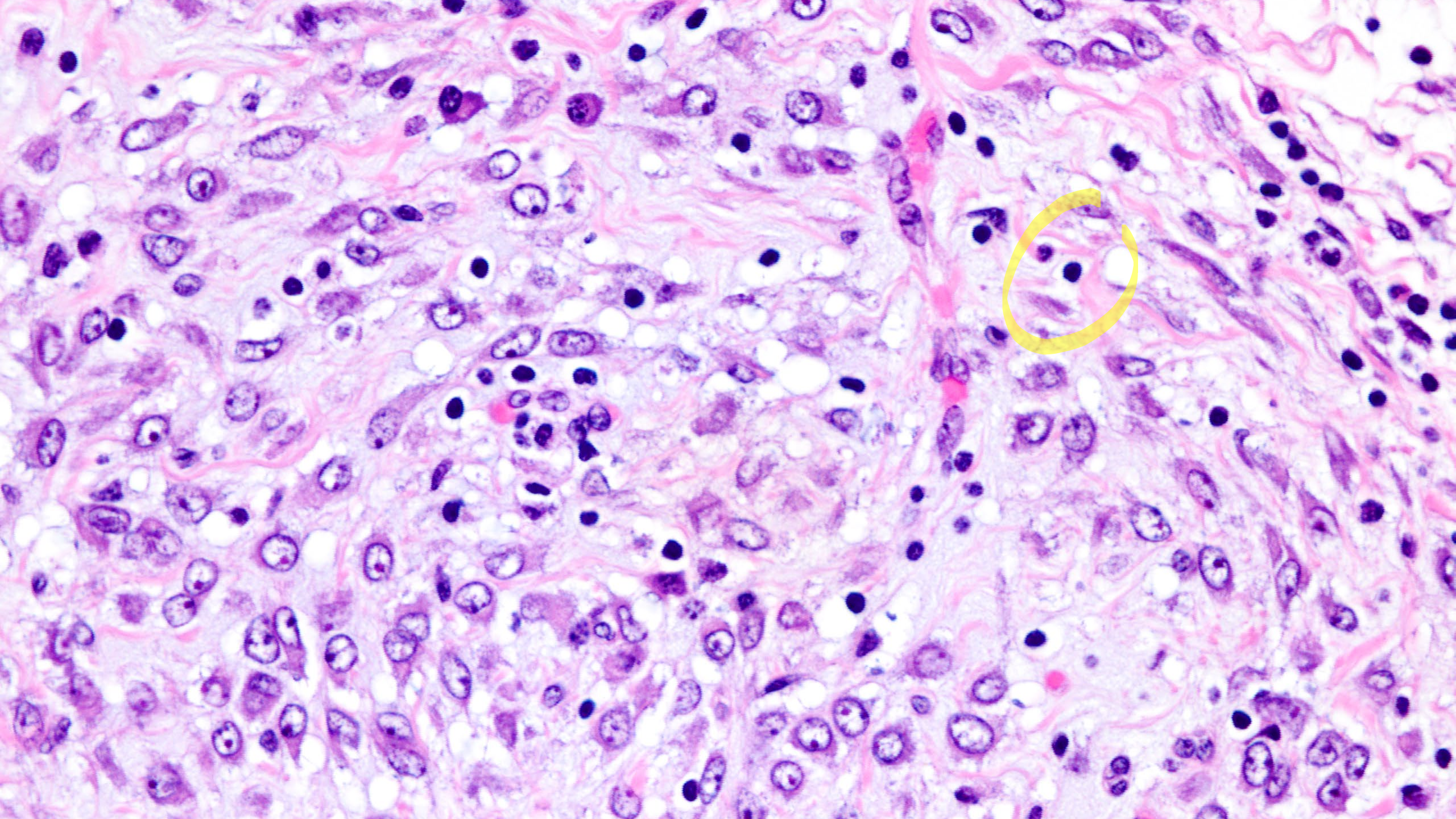
ROS1



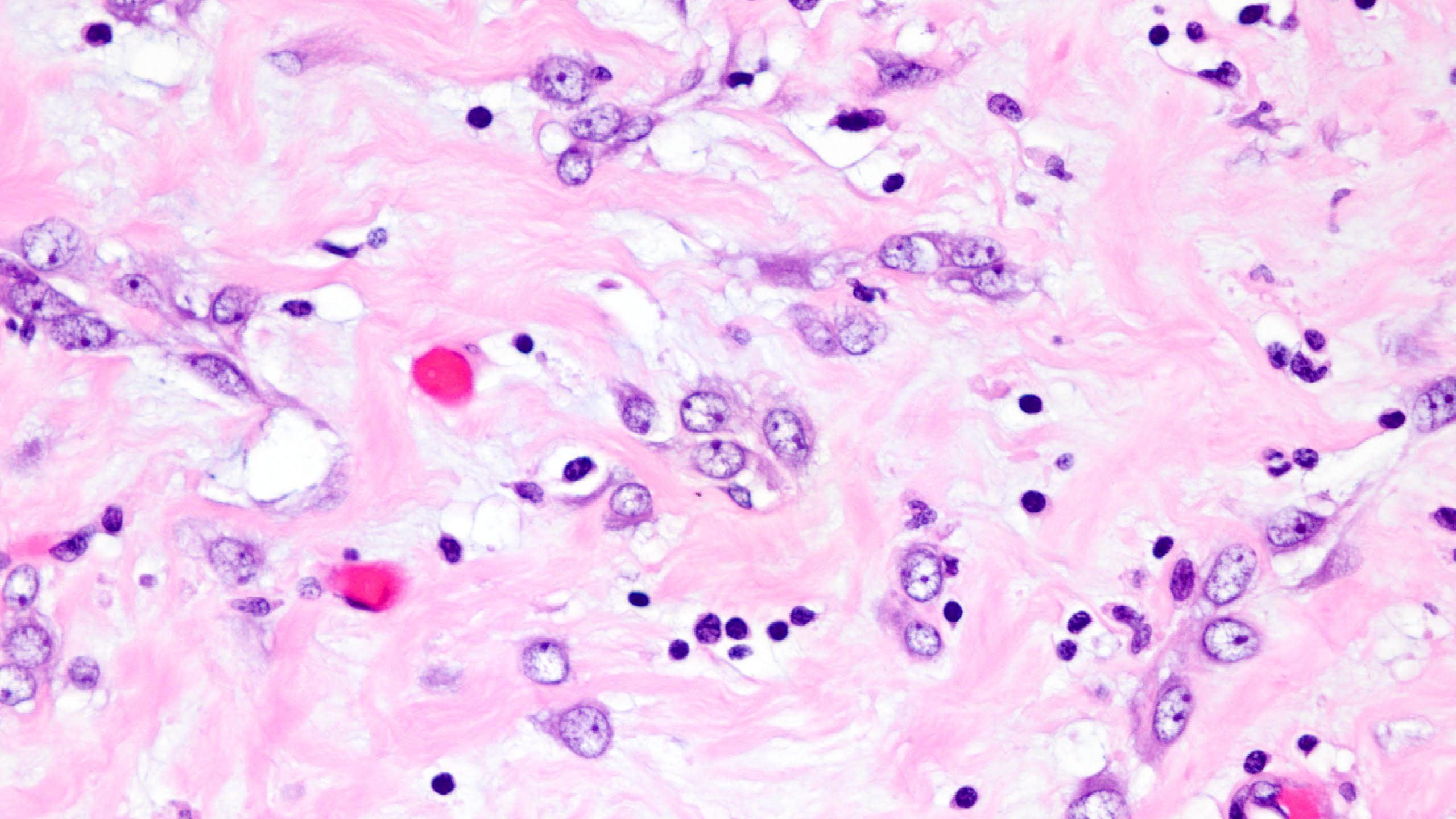
# Epithelioid Inflammatory Myofibroblastic Tumor





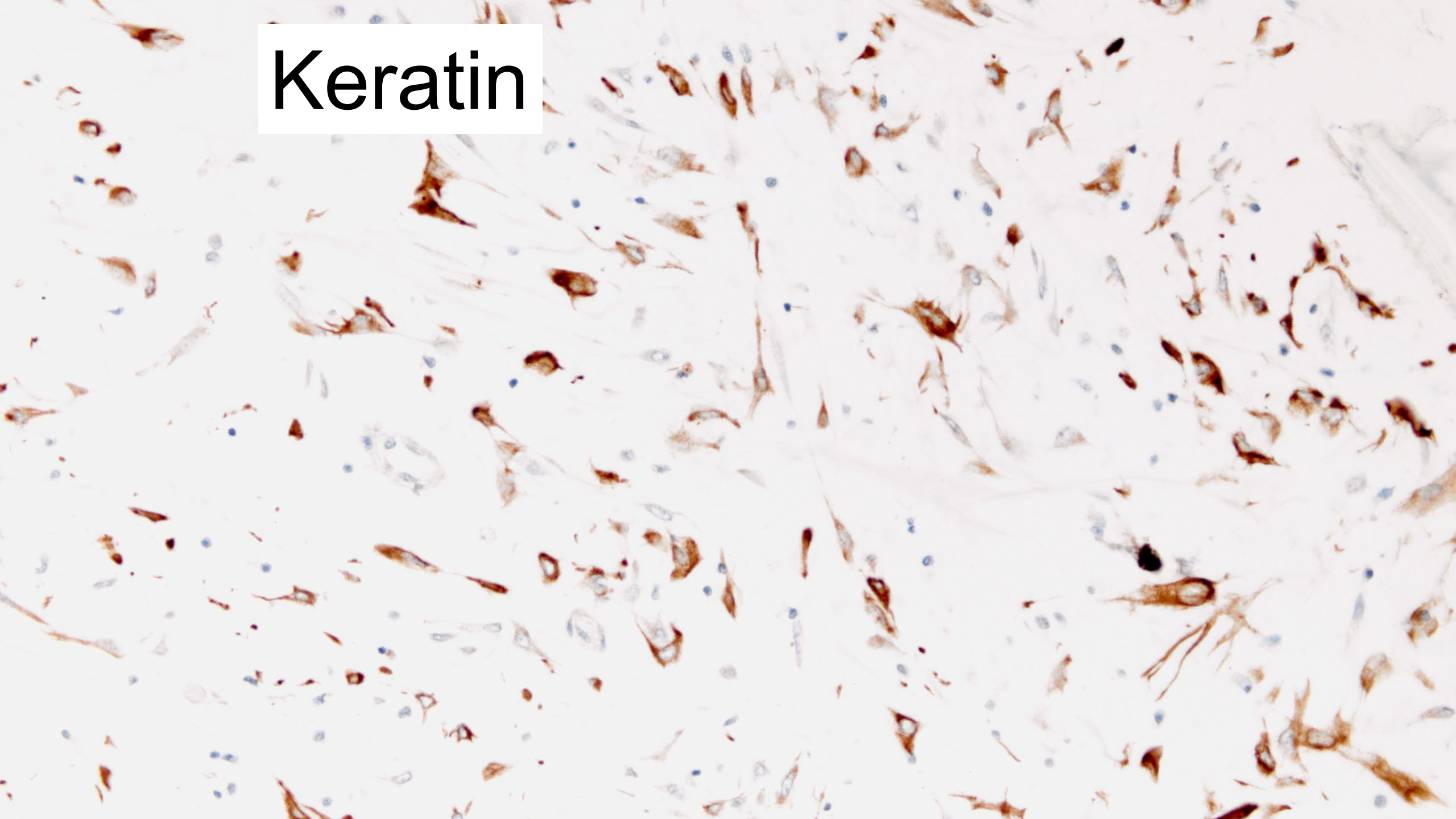






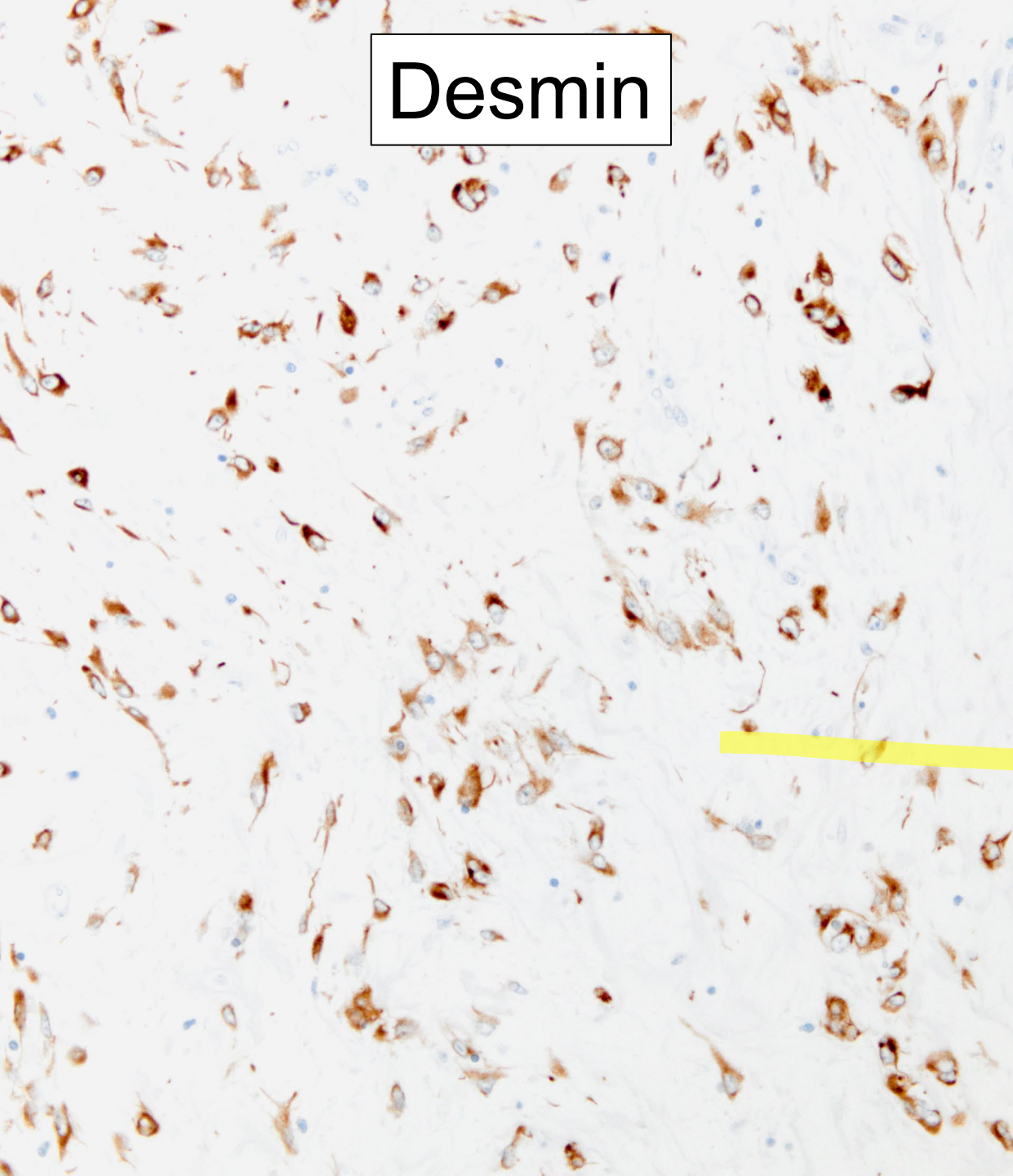


# Keratin

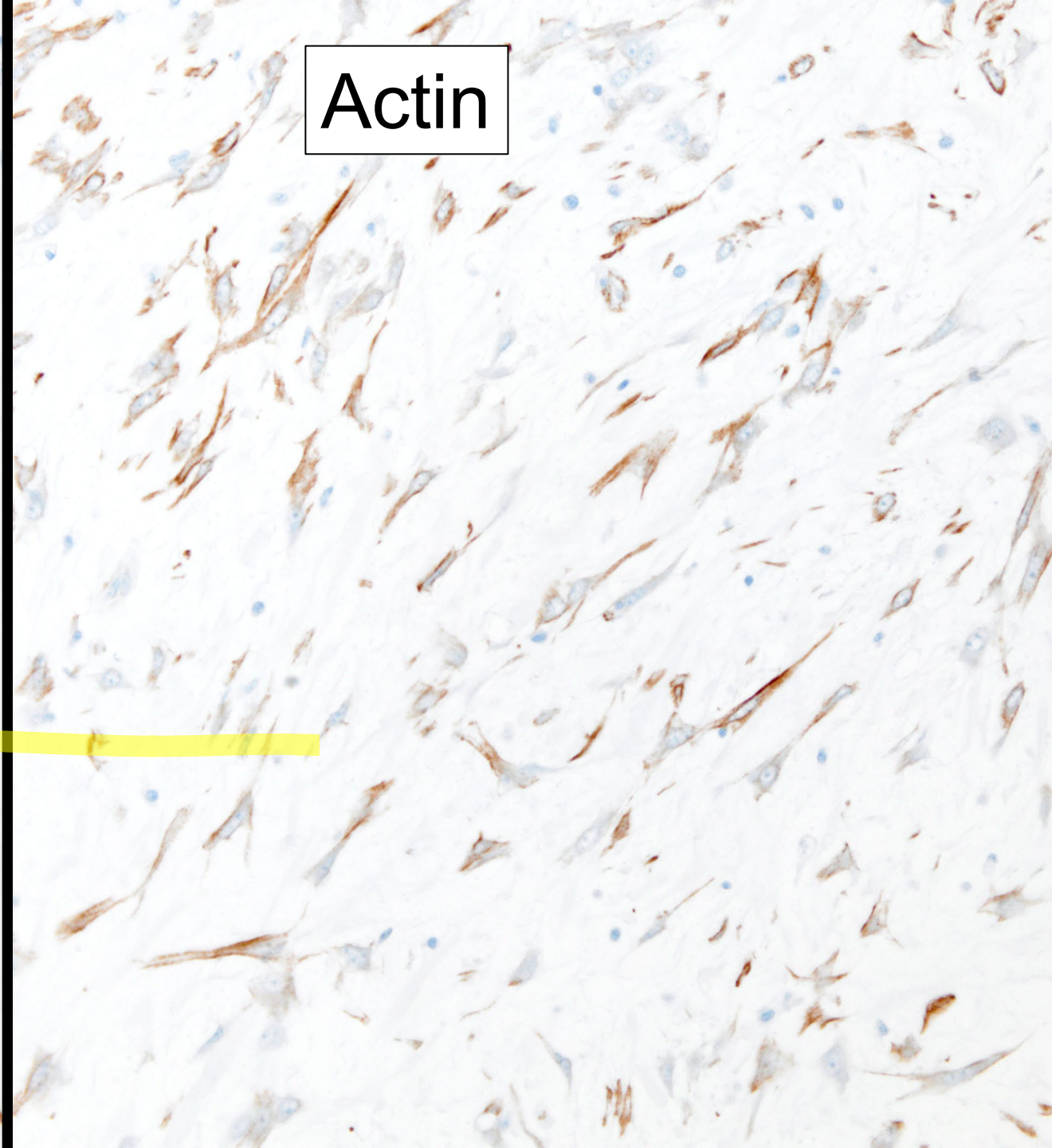




Desmin

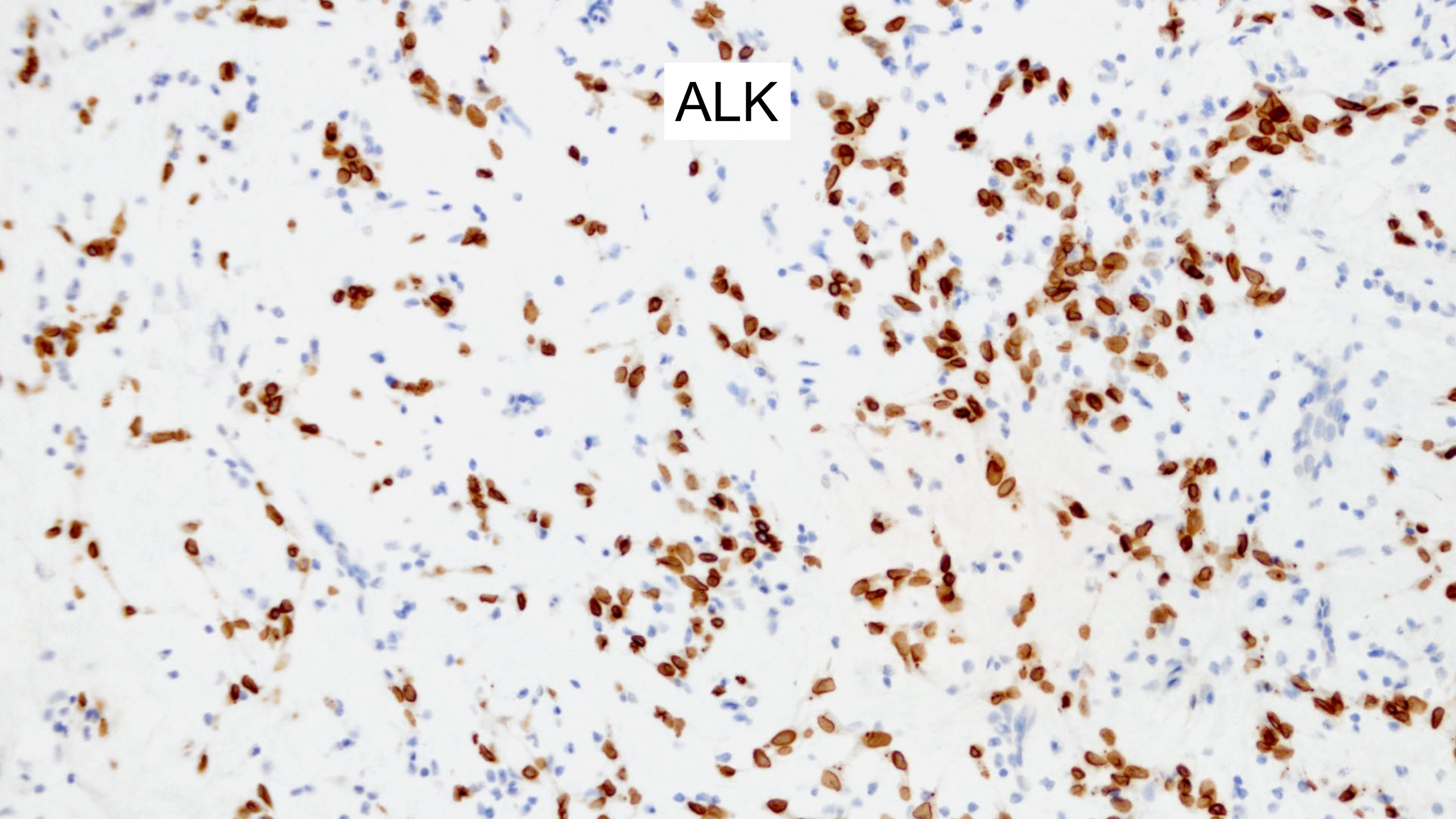


Actin





ALK










# Epithelioid IMT

- Wide age range
- Male predominance
- Intraabdominal predominance
- Epithelioid phenotype, myxoid stroma
- Desmin positive
- ALK+ perinuclear reactivity
- *RANBP2-ALK* fusion
- Aggressive biology





| <b>Genetic change in IMT</b> | <b>Therapy</b> |
|------------------------------|----------------|
| ALK-1                        | Crizotinib     |
| ROS1                         | Crizotinib     |
| NTRK                         | larotrectinib  |

**Genetic change in IMT**

**Therapy**

ALK-1

Crizotinib

ROS1

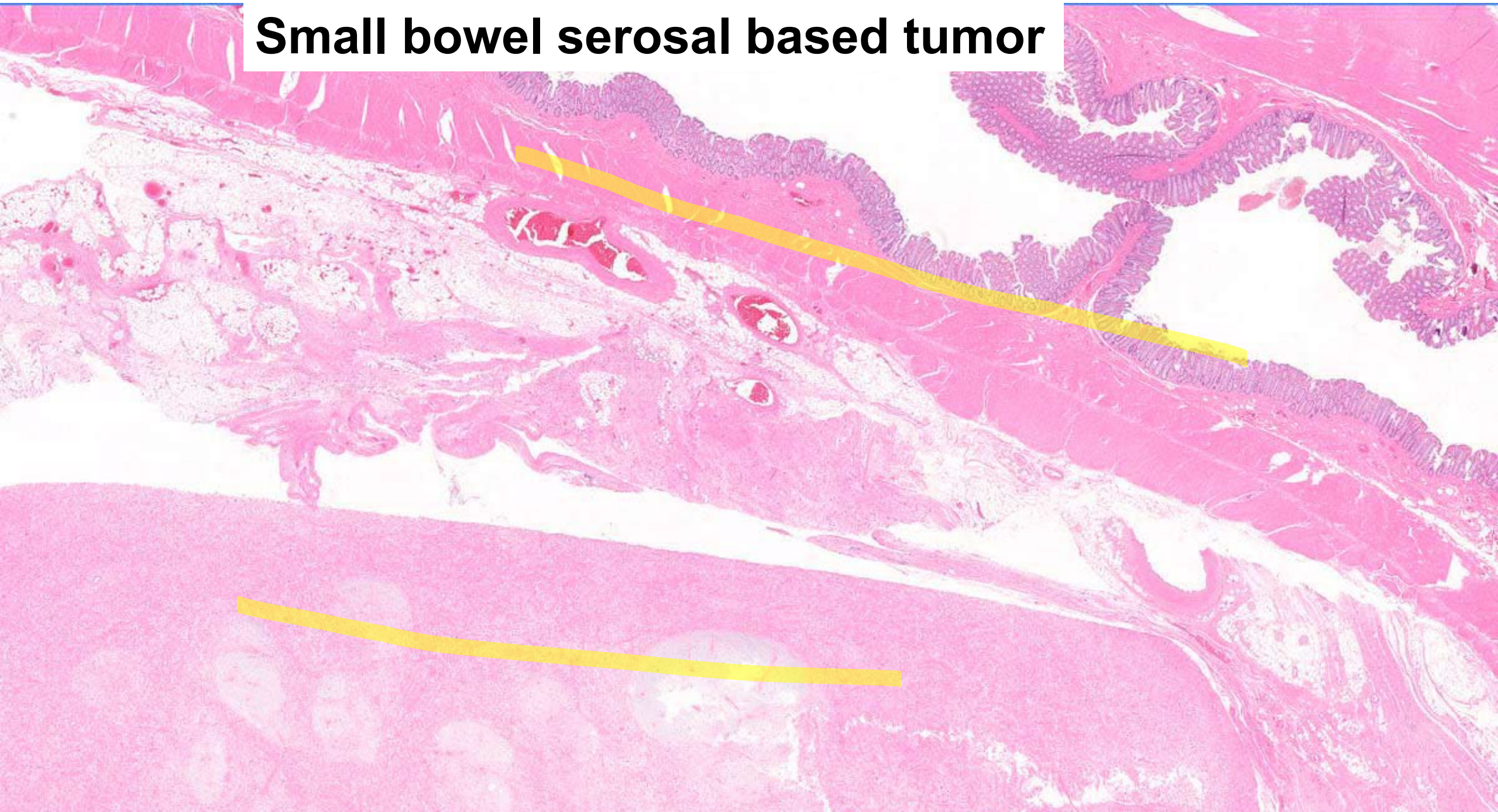
Crizotinib

NTRK

larotrectinib



# Small bowel serosal based tumor





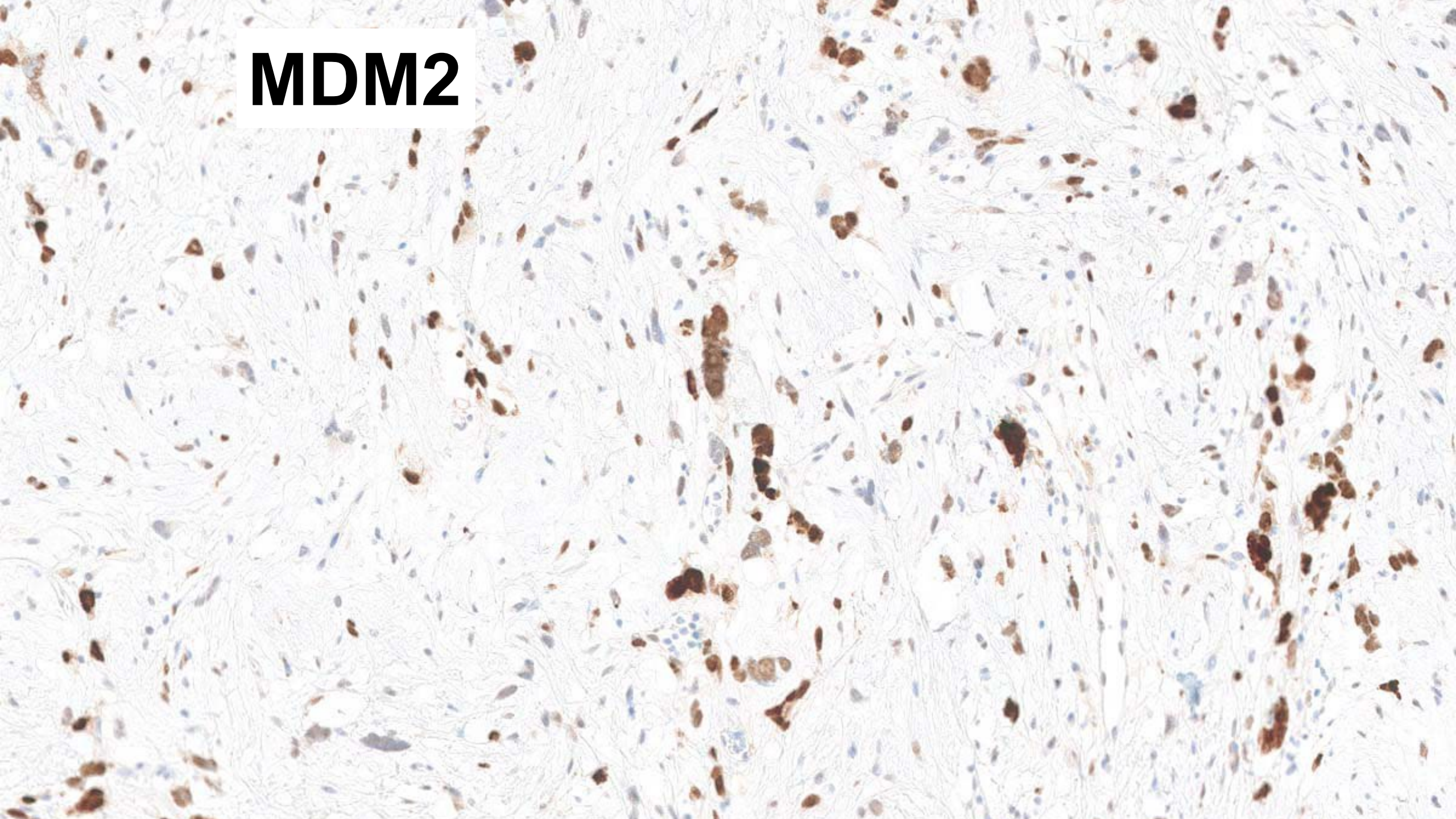
A histological slide showing a dense population of spindle-shaped cells with hyperchromatic nuclei and eosinophilic cytoplasm, characteristic of dedifferentiated liposarcoma. A yellow circle highlights a specific cell with a large, dark, hyperchromatic nucleus.

**High grade sarcoma**

**Dedifferentiated liposarcomas**



**MDM2**





# Lesson I've learnt

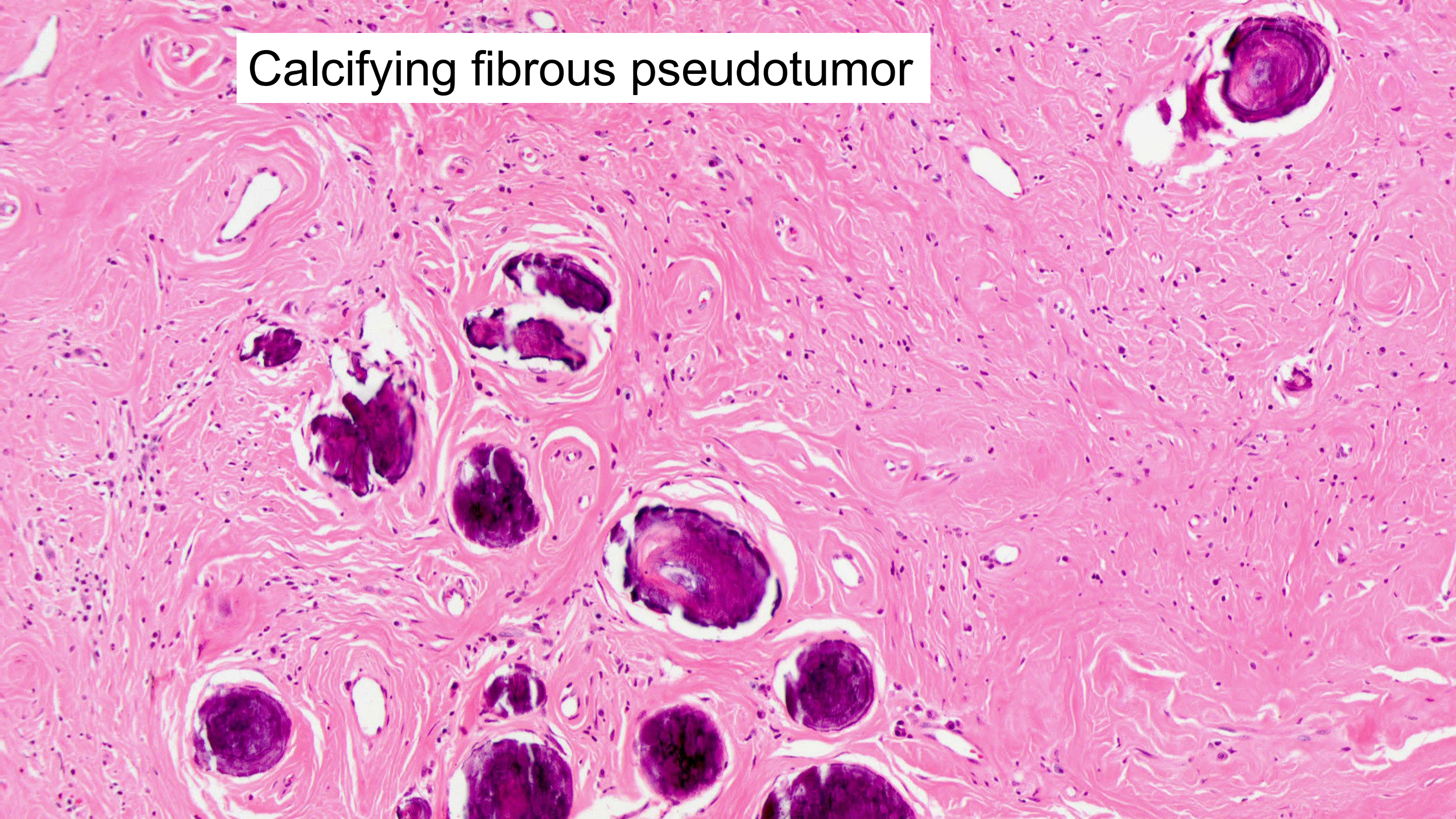
All intra-abdominal high-grade sarcomas represent dedifferentiated liposarcomas

Until proven otherwise





# Calcifying fibrous pseudotumor



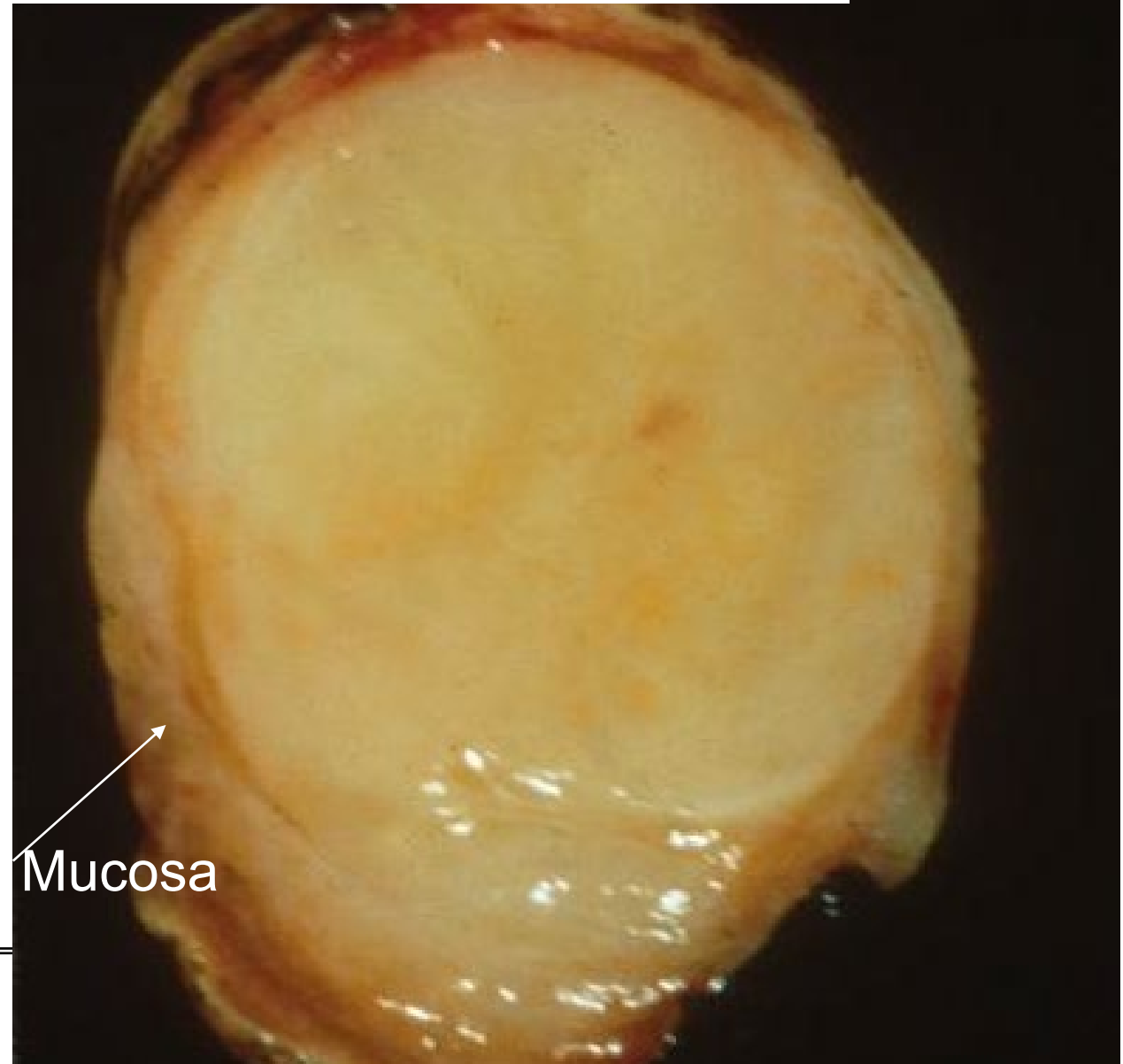
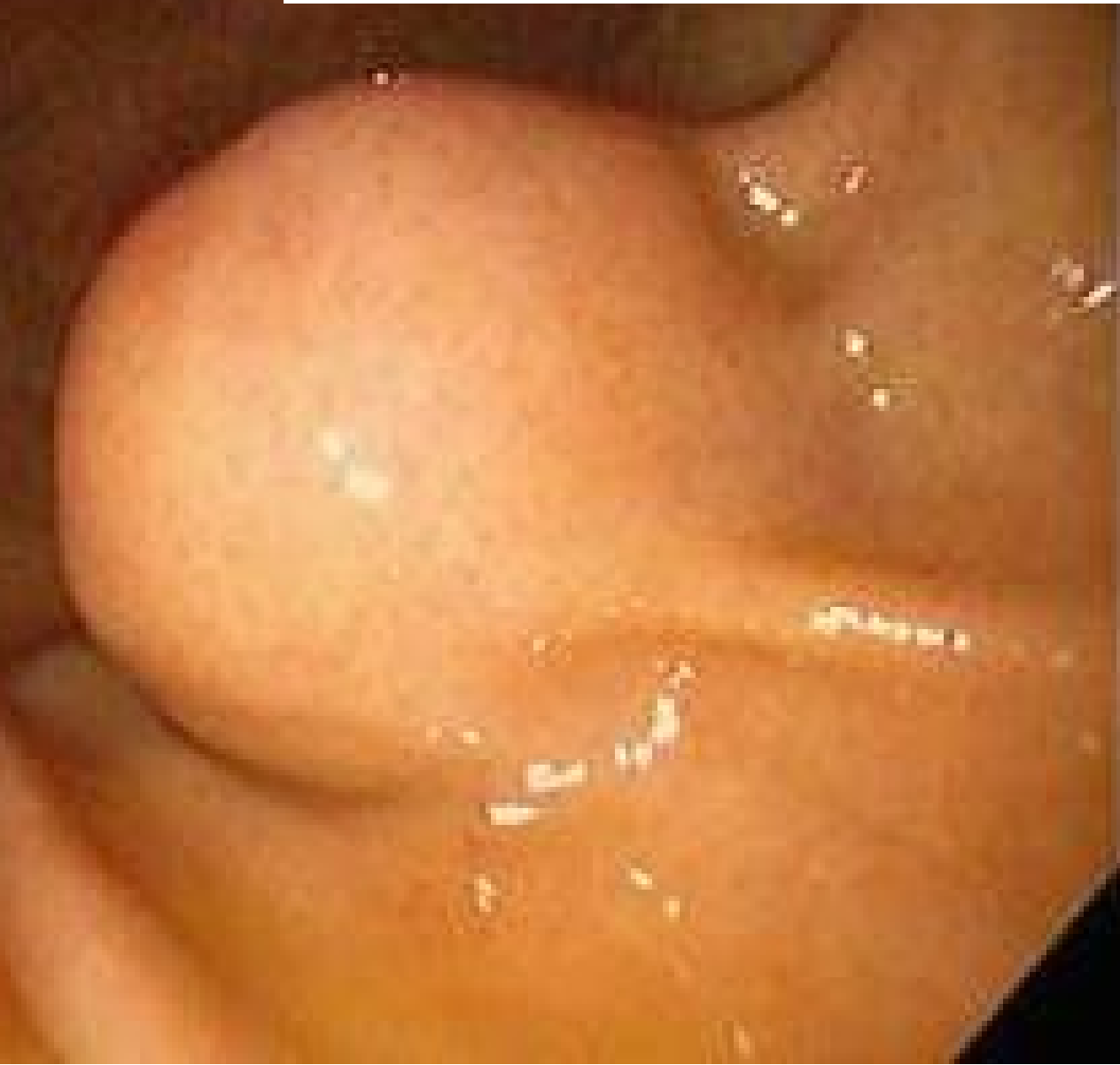

# Muscularis Propria



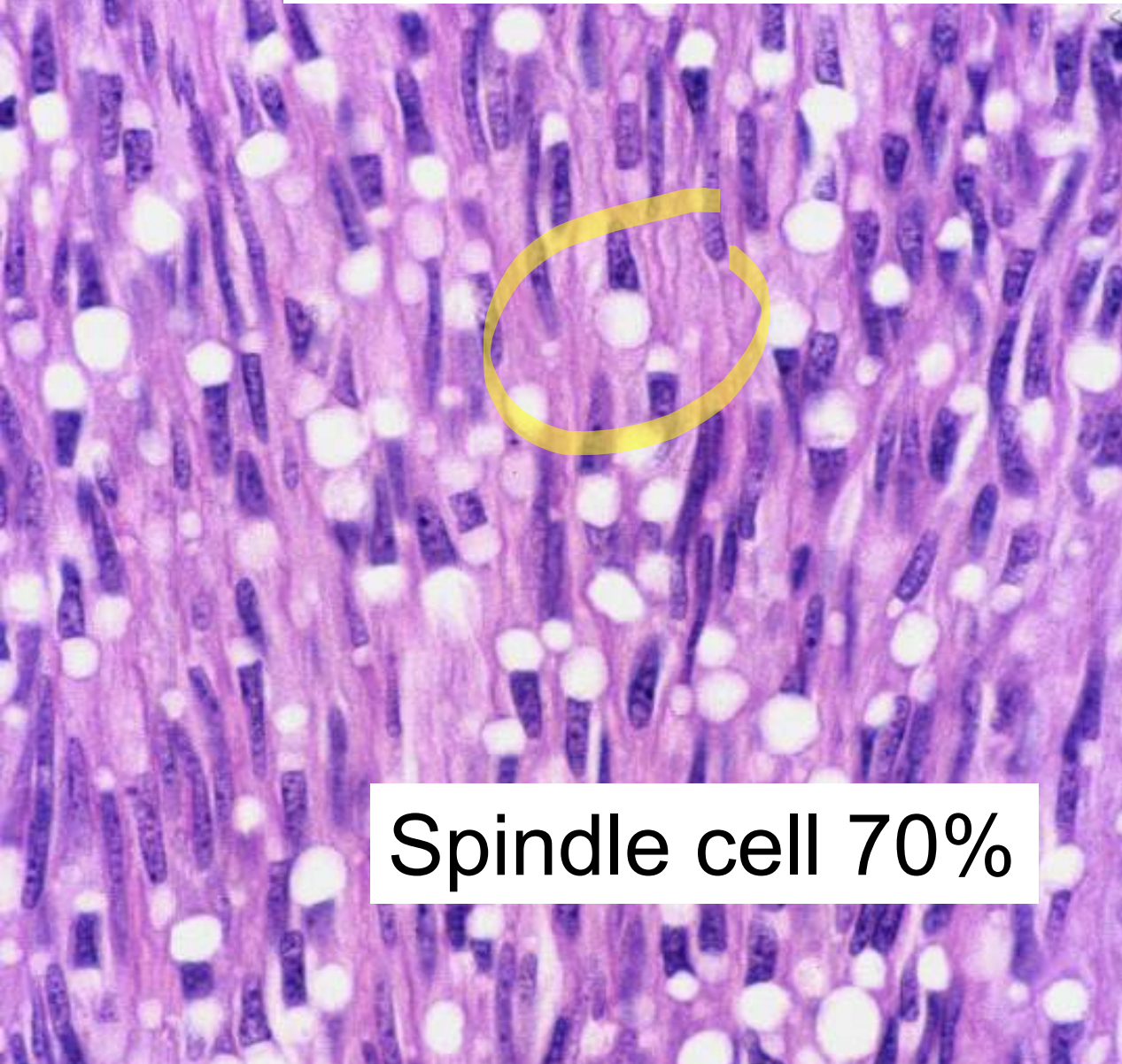


# Gastrointestinal Stromal Tumor

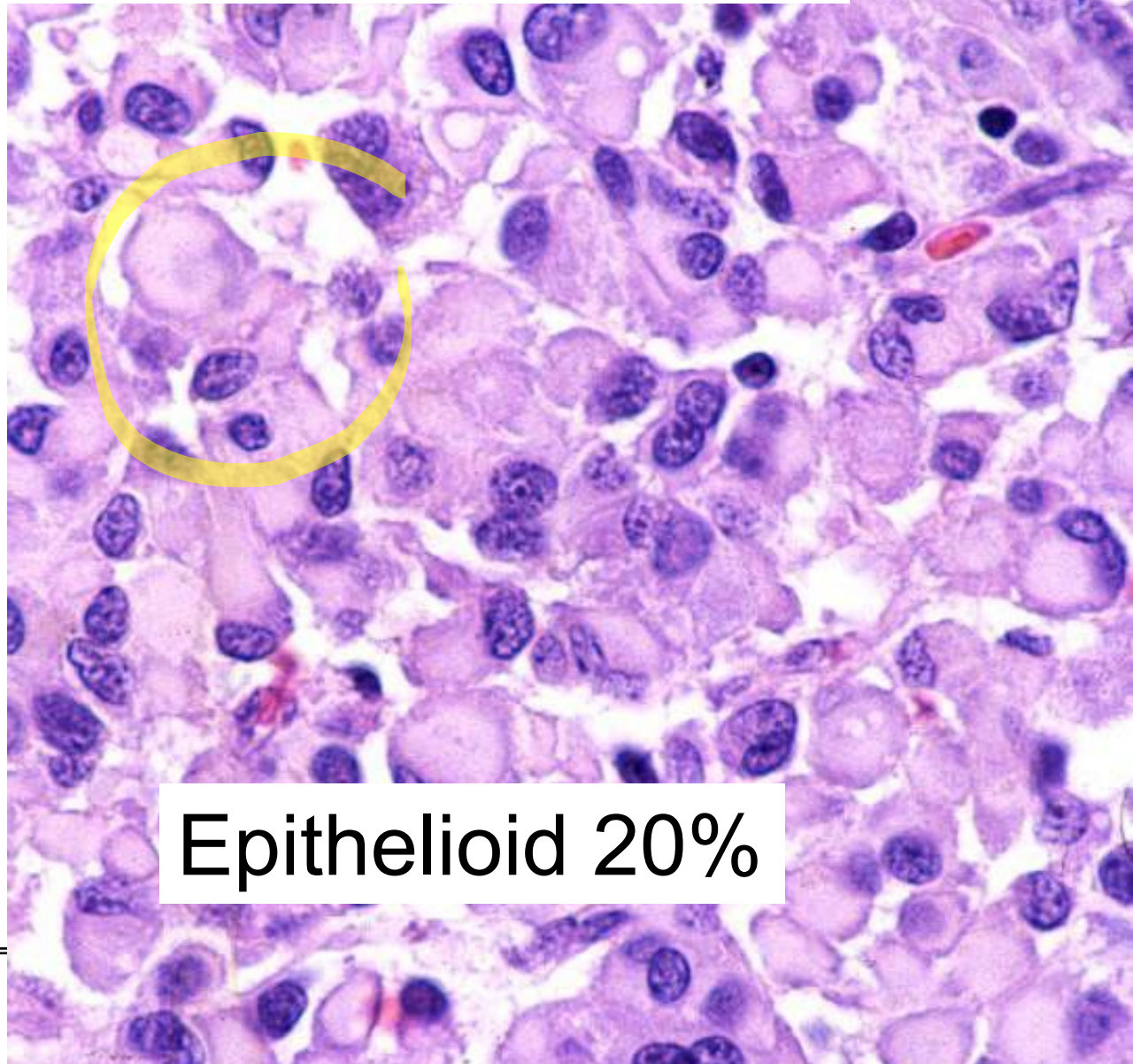




# Gastrointestinal Stromal Tumor



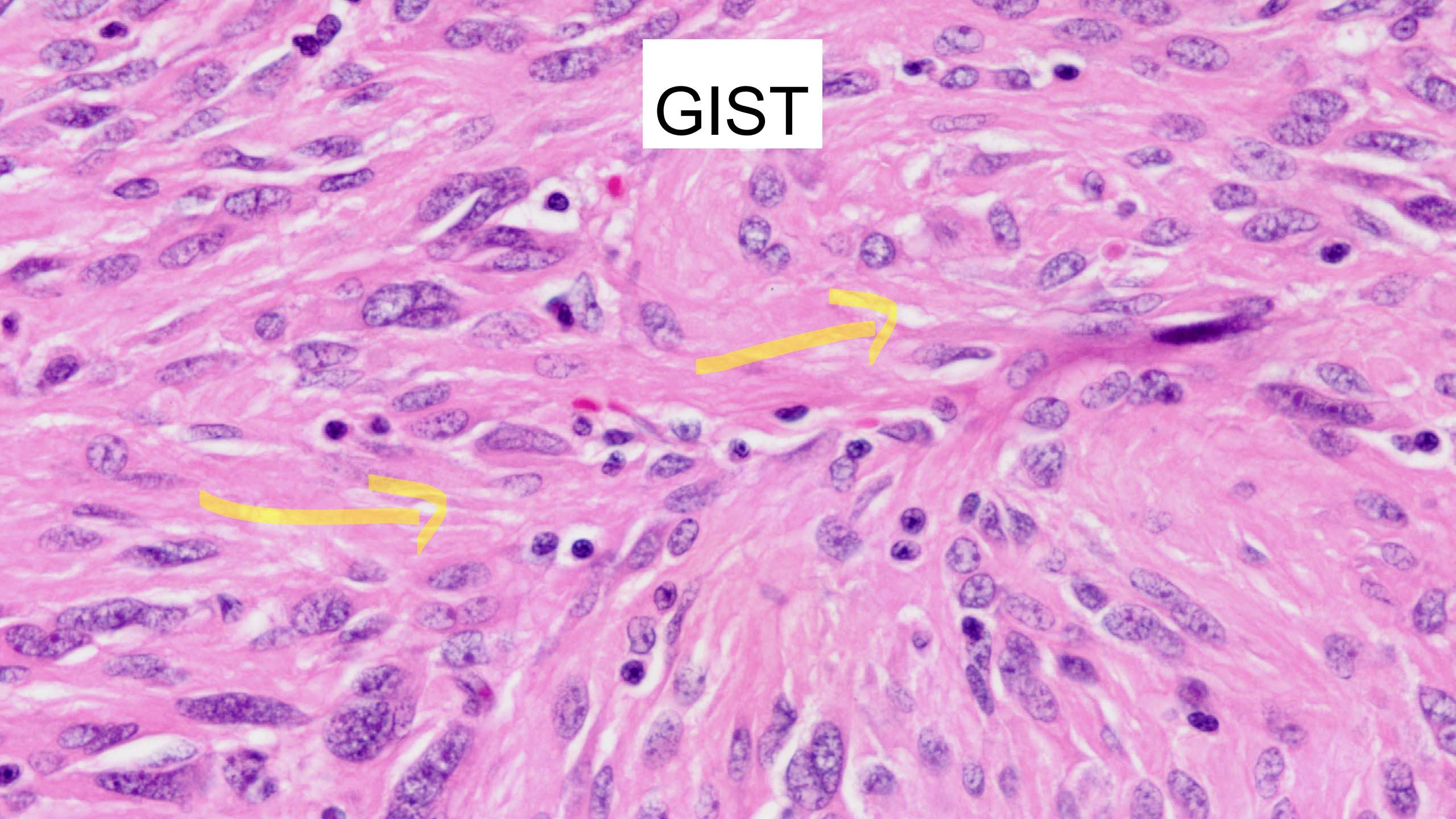Spindle cell 70%



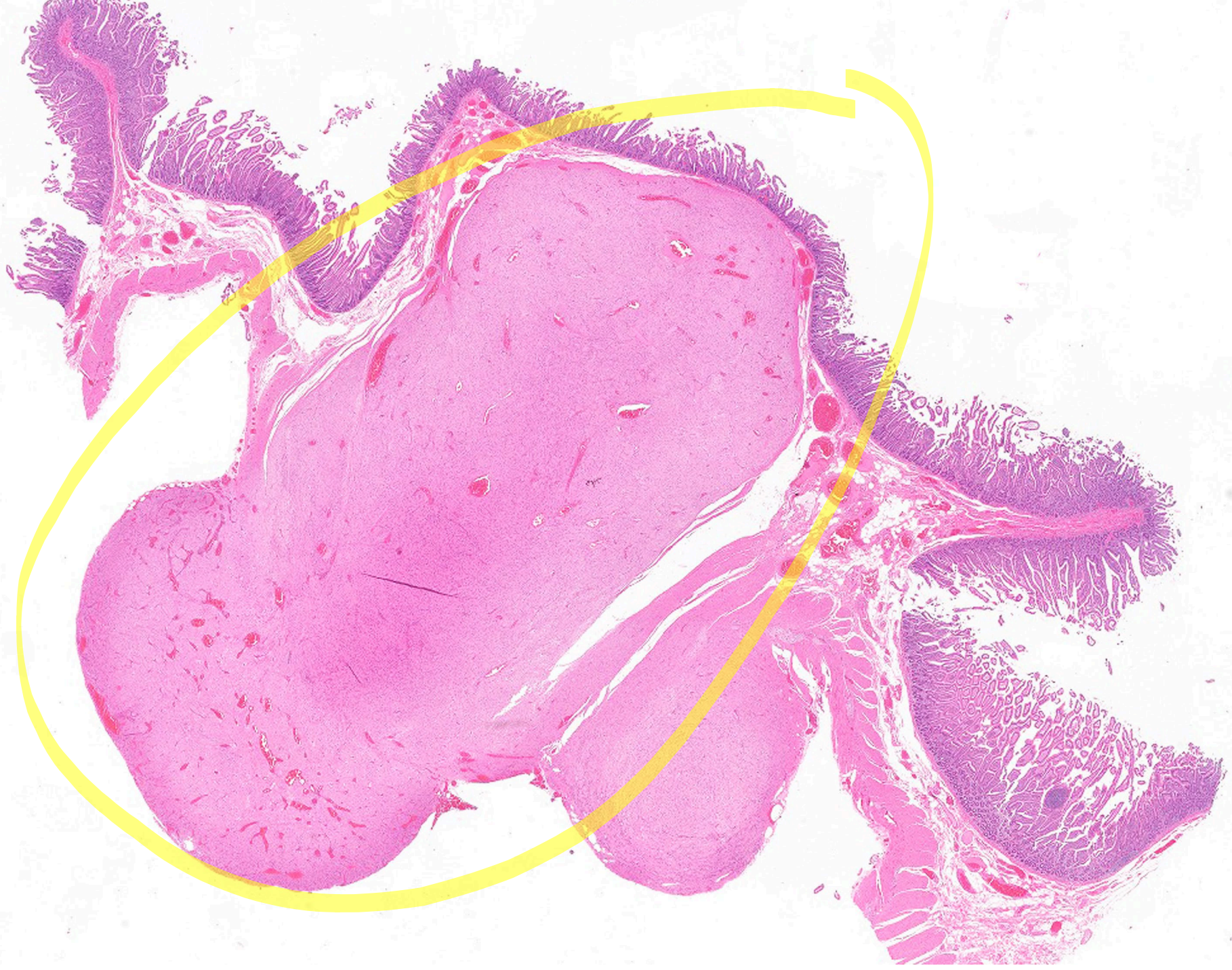
Epithelioid 20%



GIST

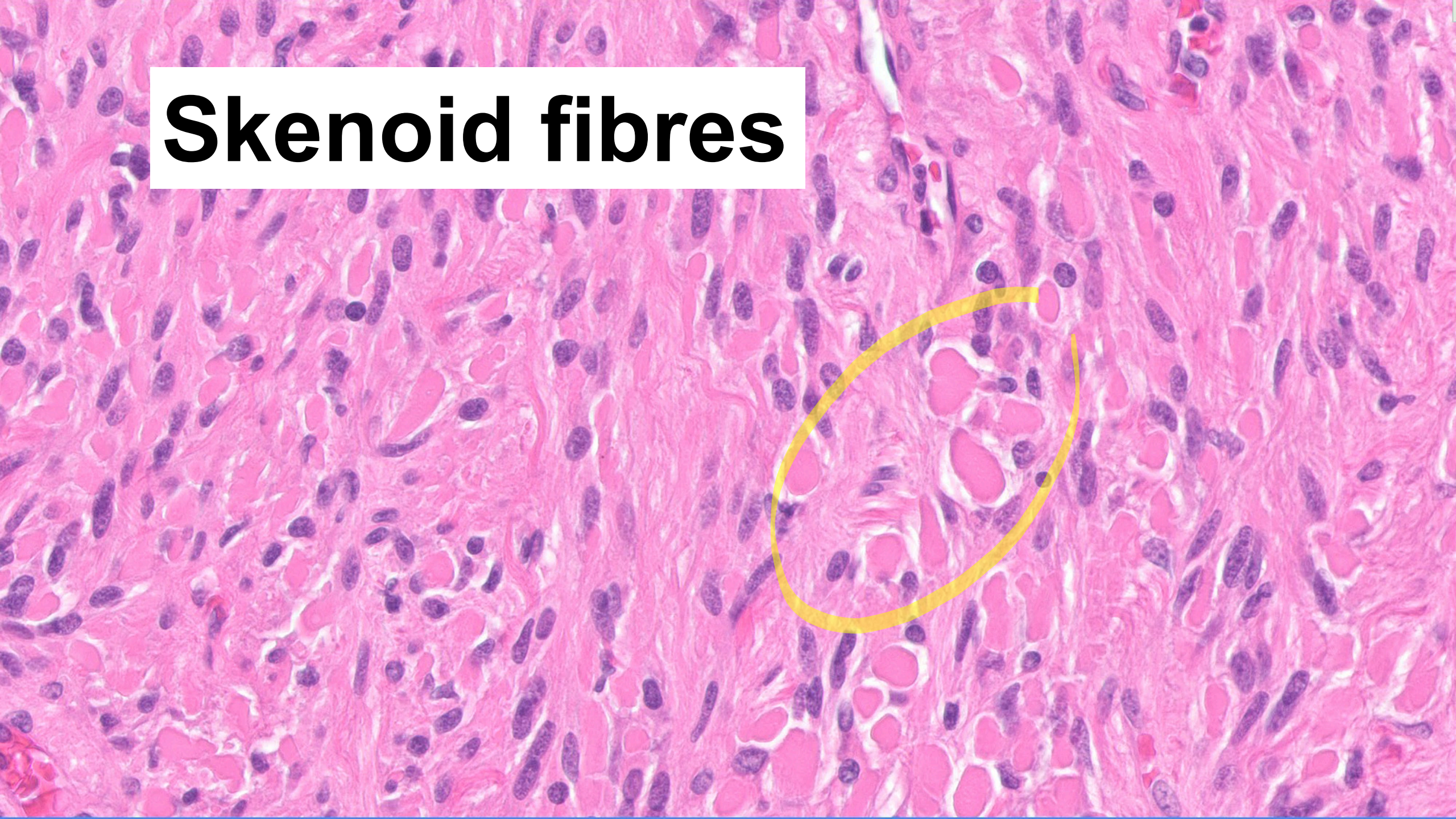






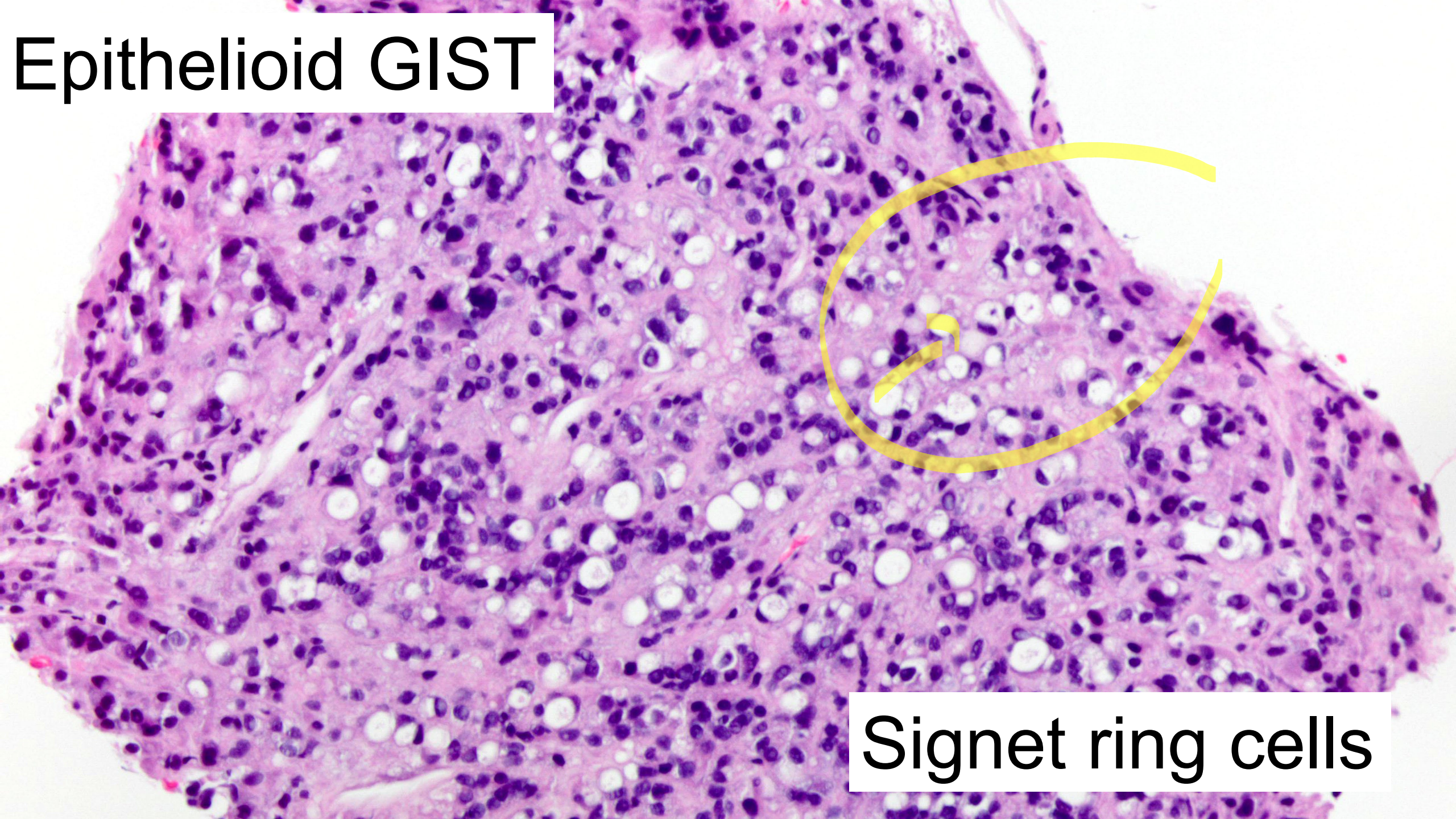


# Skenoid fibres





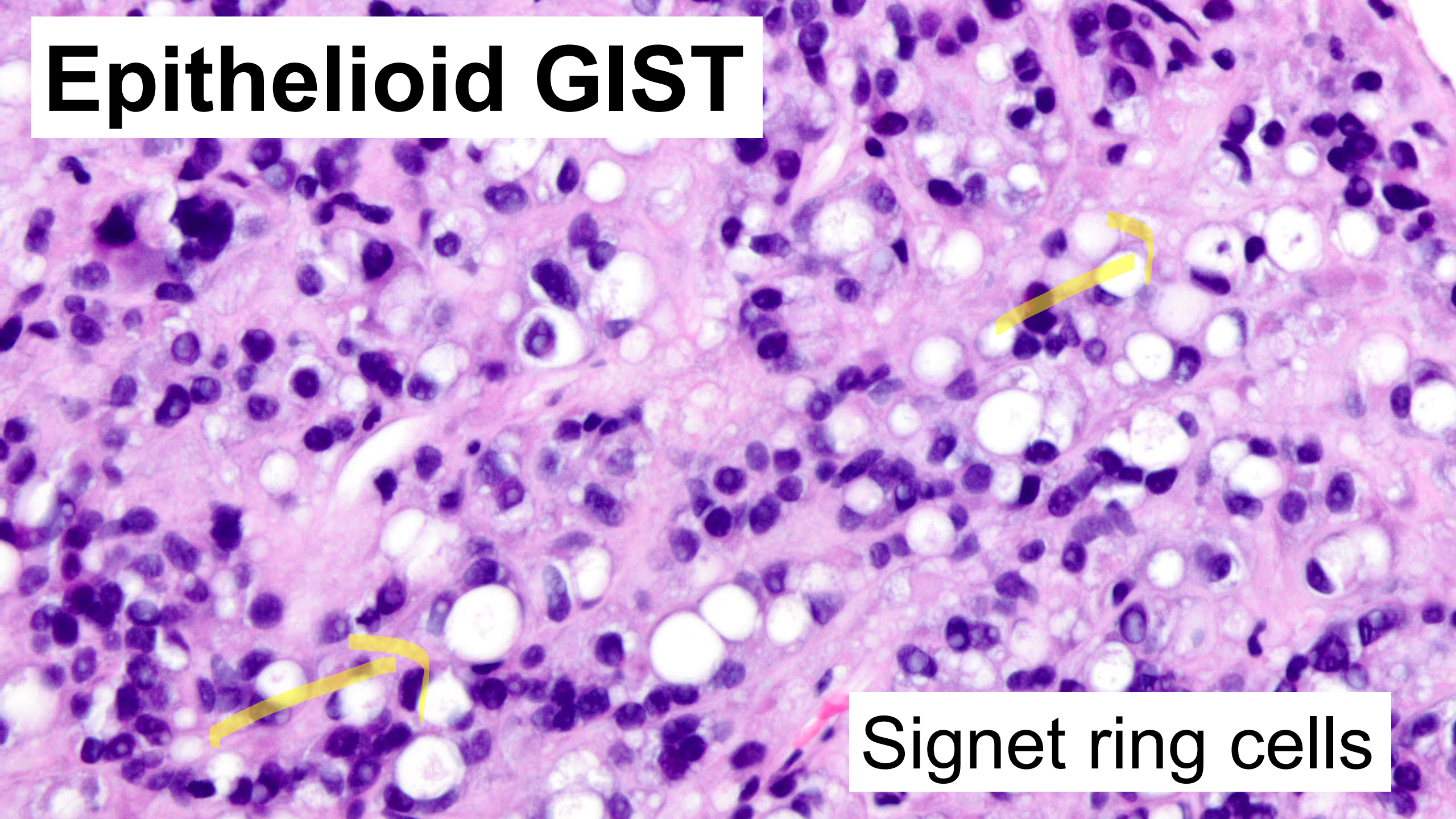
# Epithelioid GIST



Signet ring cells

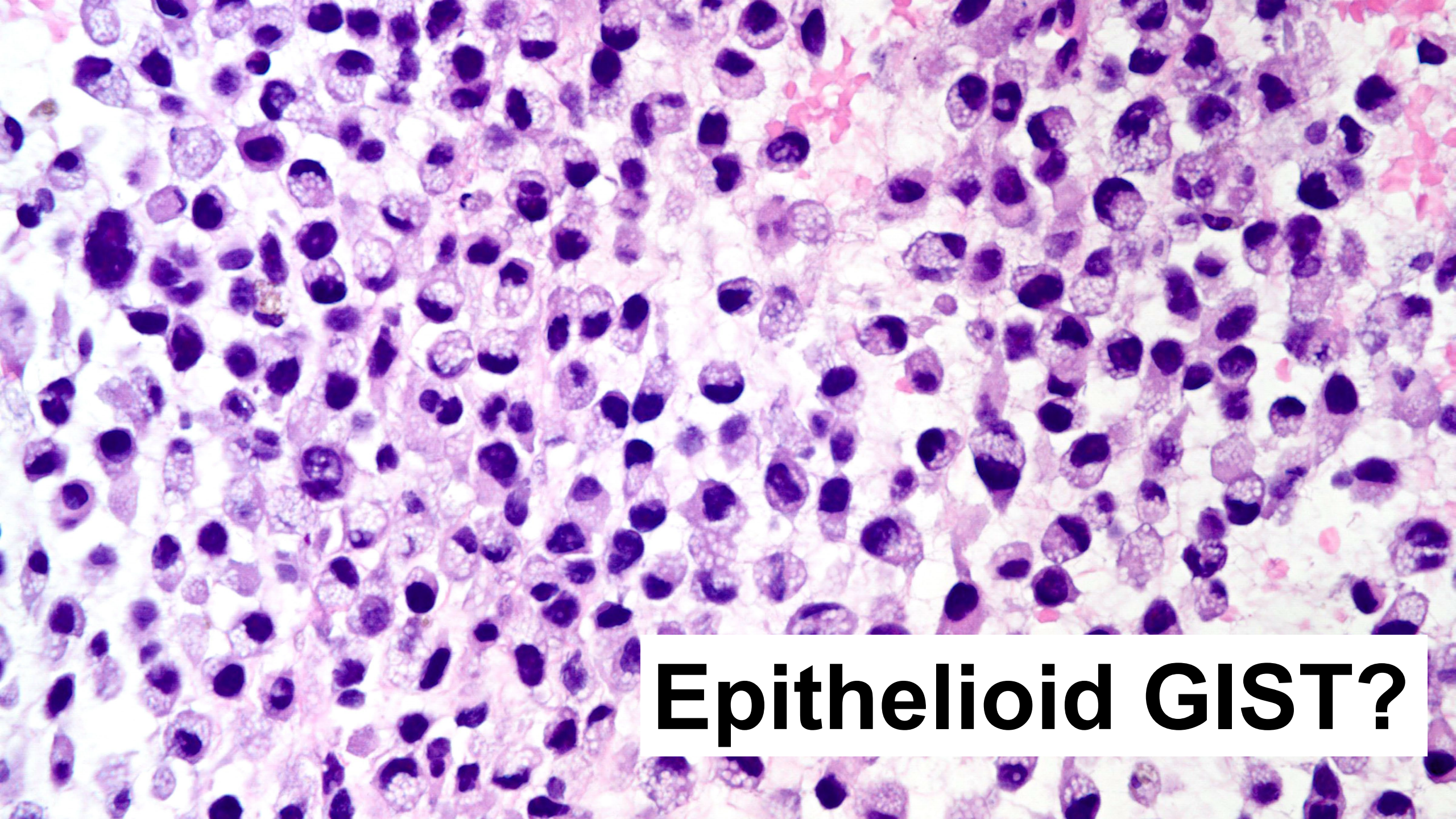


# Epithelioid GIST



Signet ring cells





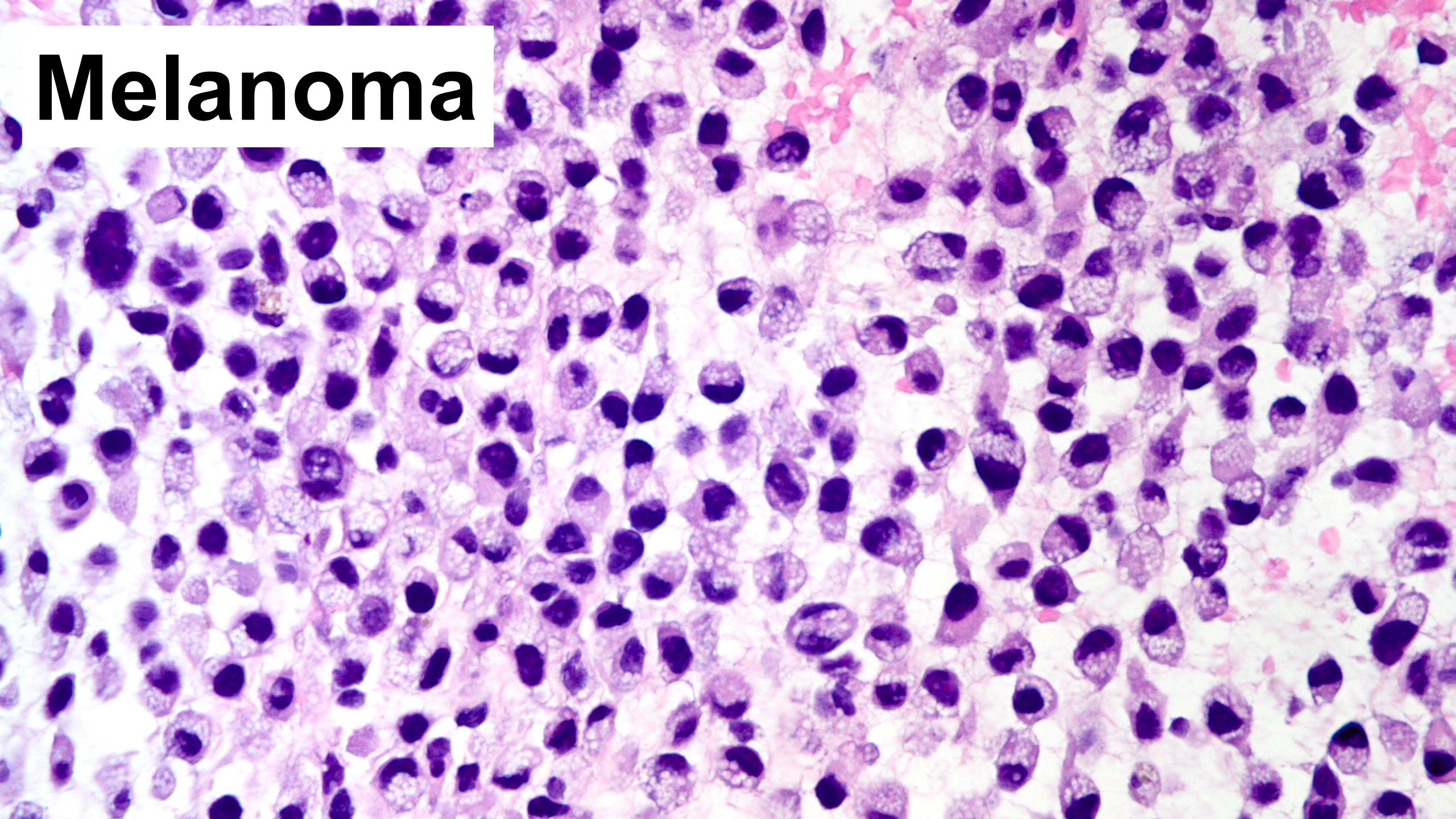
**Epithelioid GIST?**





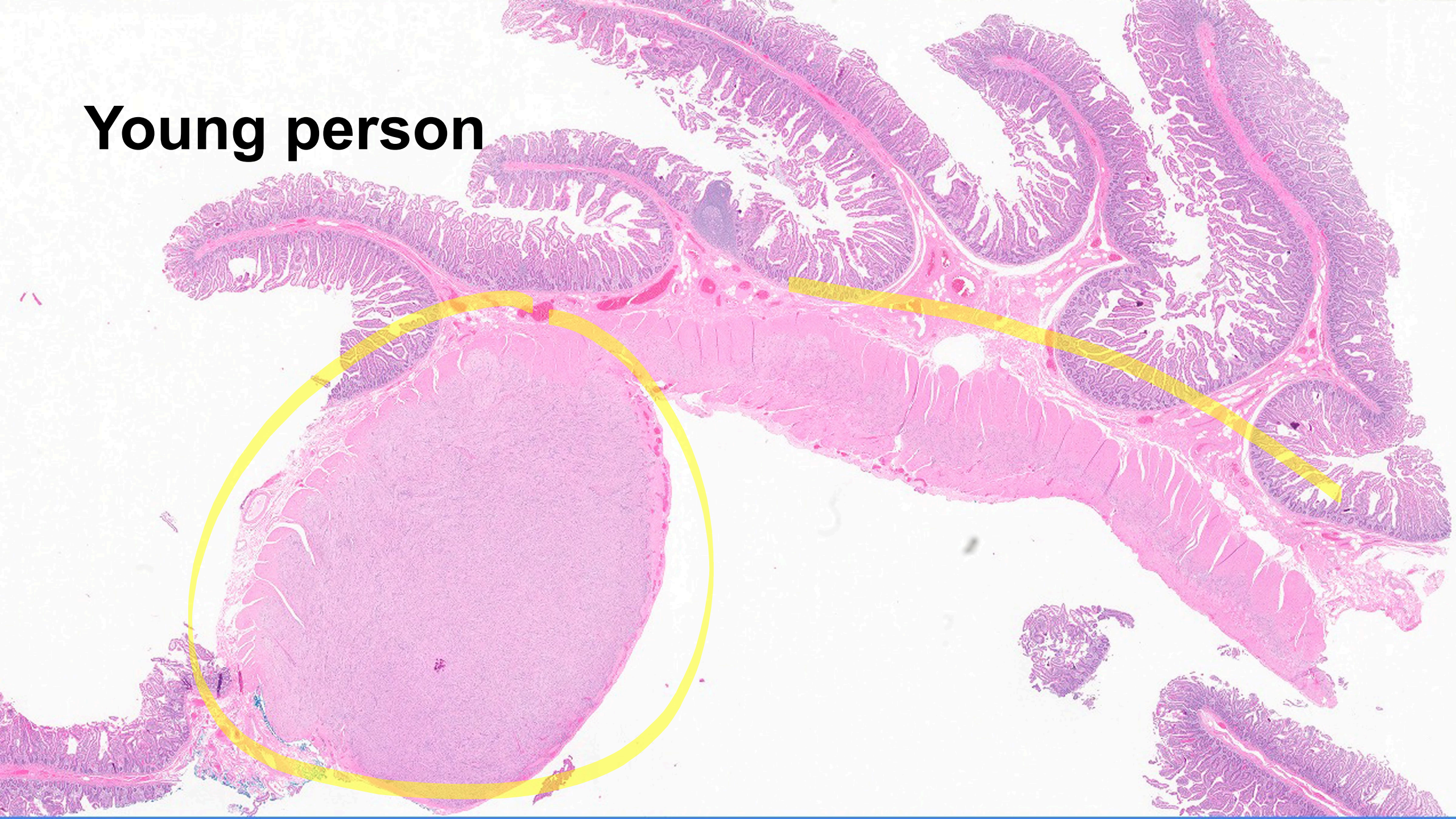

# Melanoma





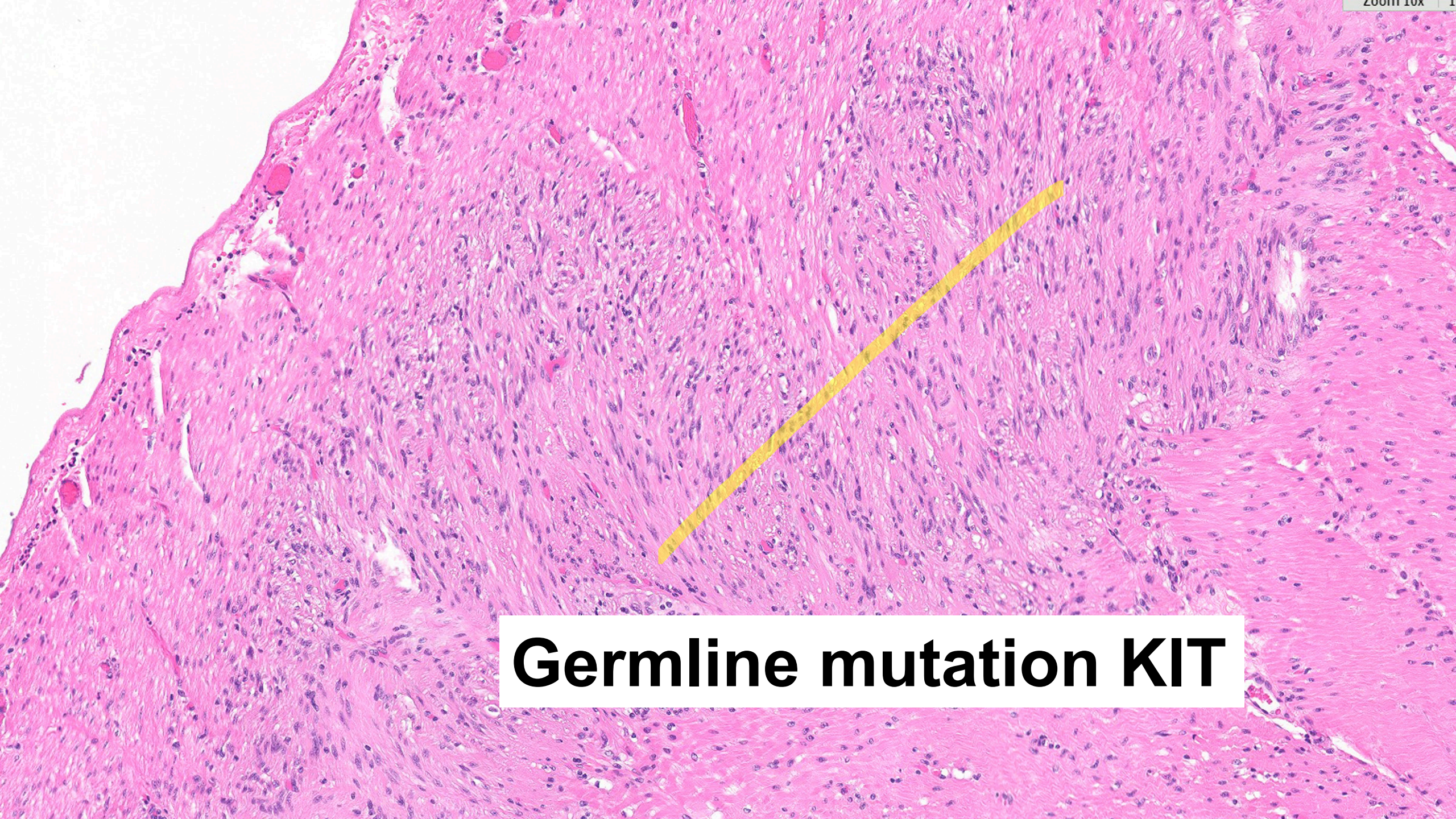
**Young person**











**Germline mutation KIT**



>95% POSITIVE

**KIT**

Negative: PDGRFA mutant

OTHER POSITIVE TUMORS with  
shared morphologic features  
Melanoma, epithelial tumors,  
some sarcomas (angiosarcoma),  
PEComa

**KIT**

>90% POSITIVE

**DOG1**

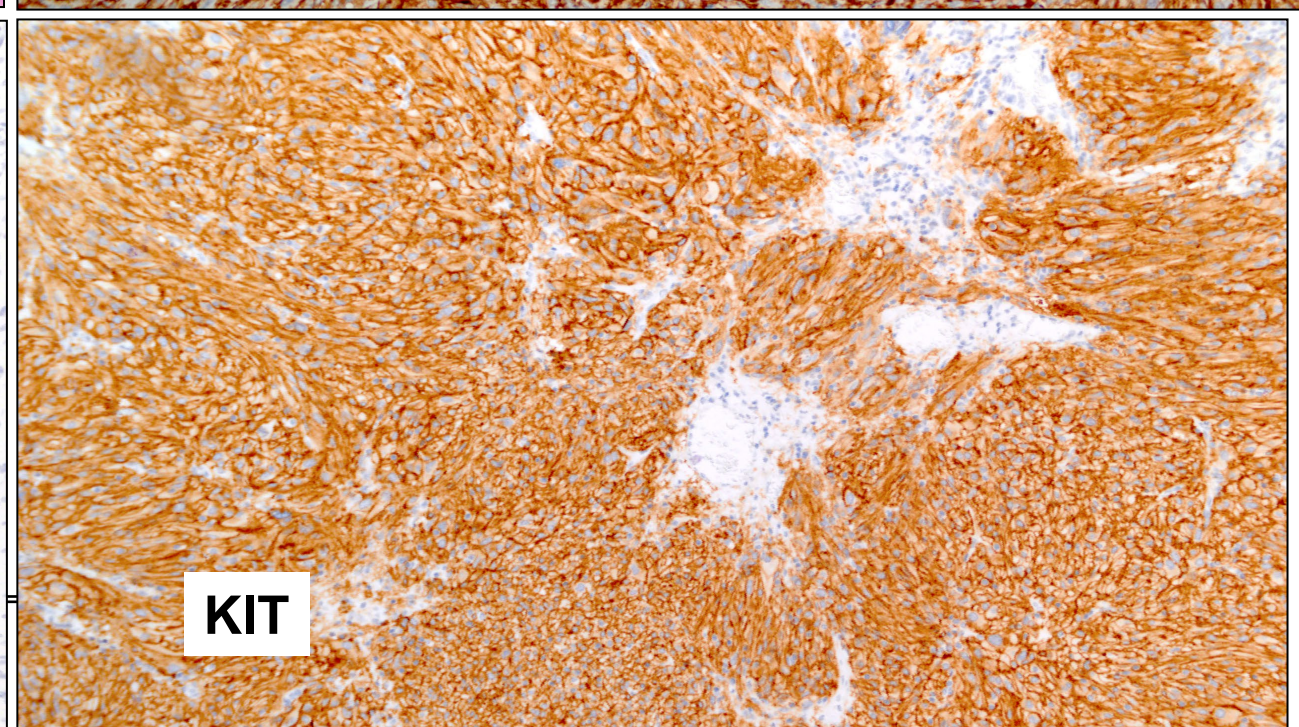
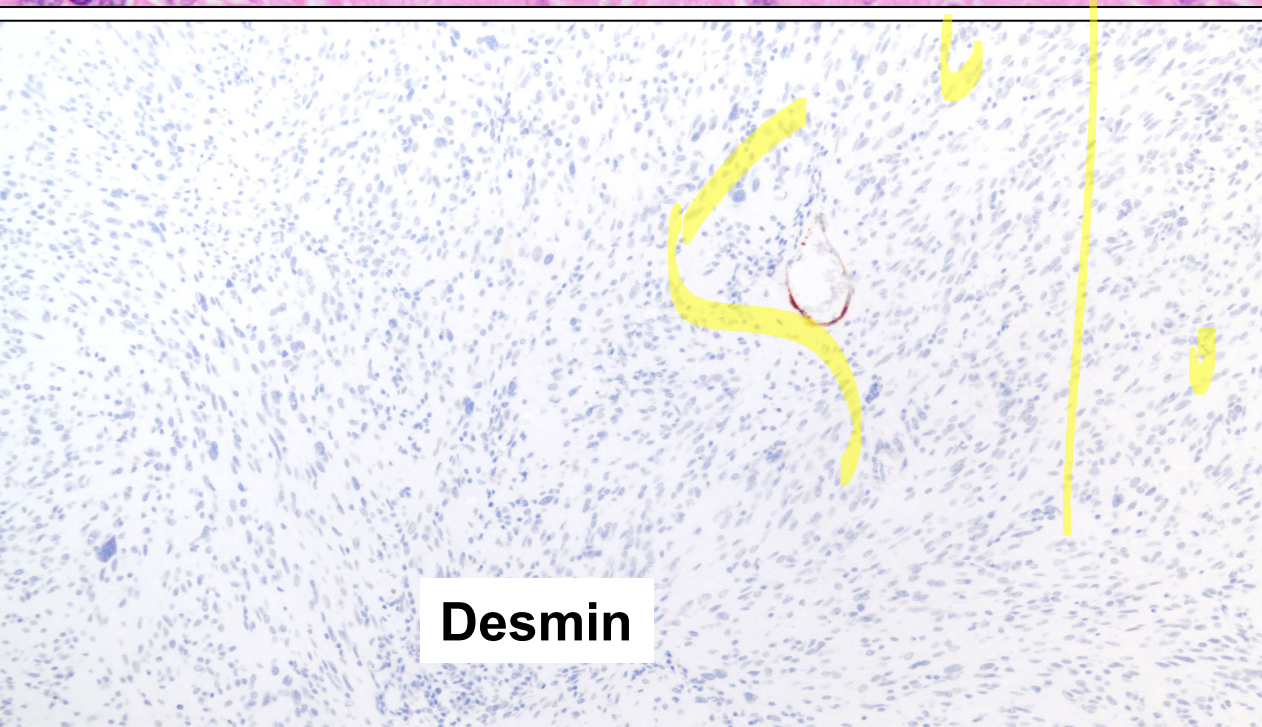
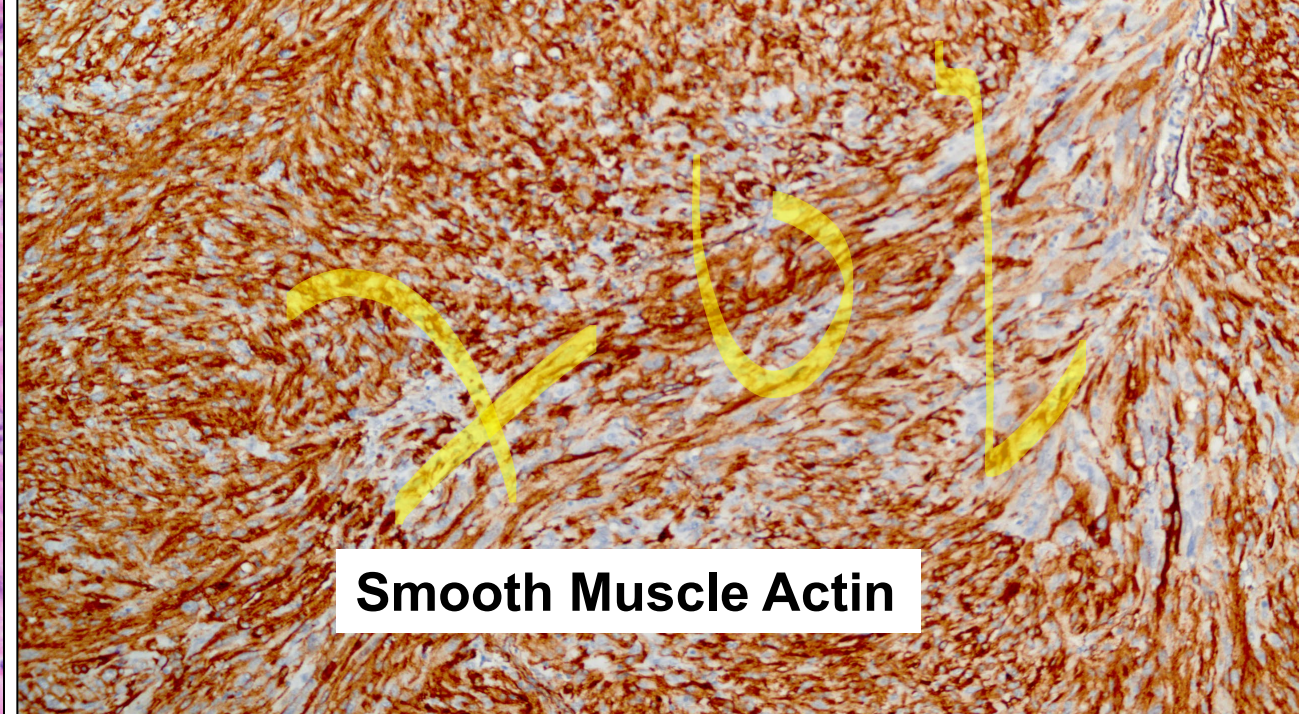
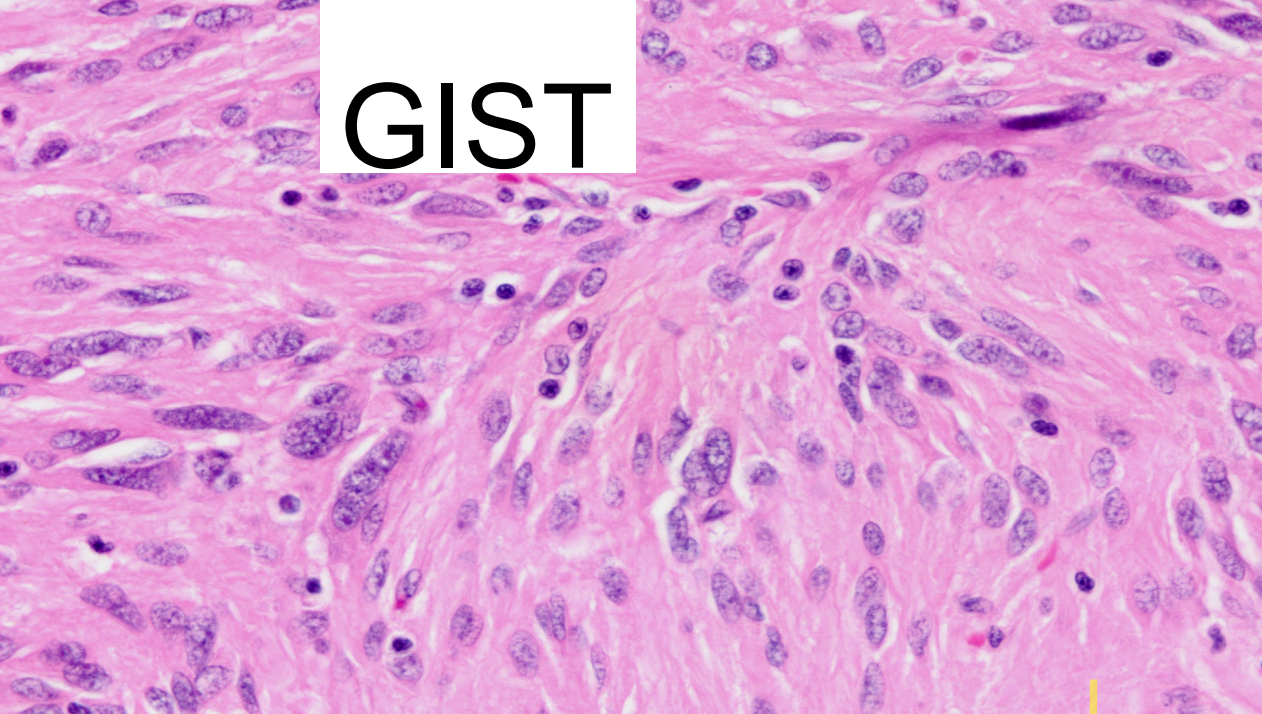Positive: PDGRFA mutant

OTHER POSITIVE TUMORS  
Leiomyoma, synovial sarcoma,  
20% of epithelial neoplasms

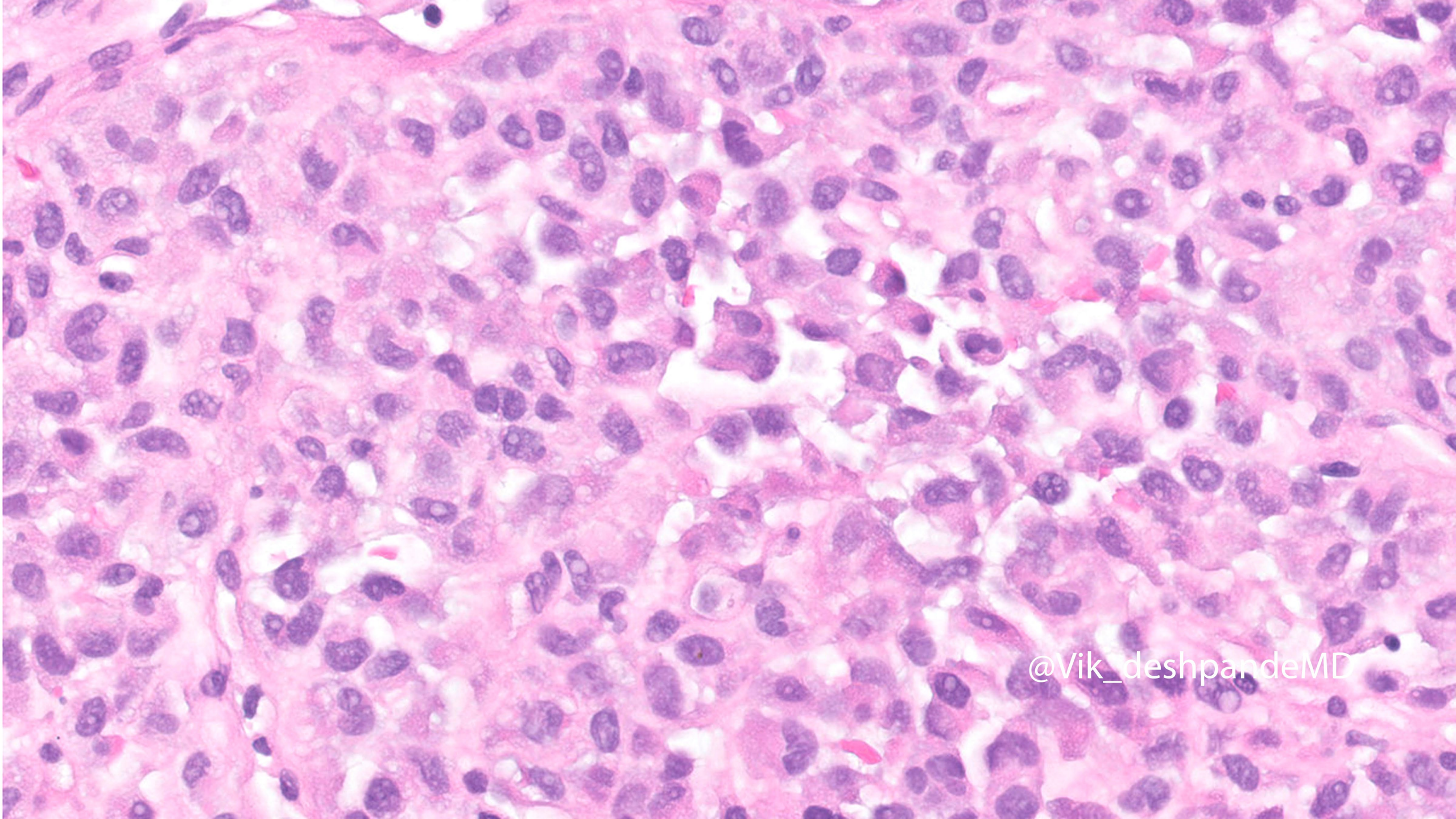
**DOG1**





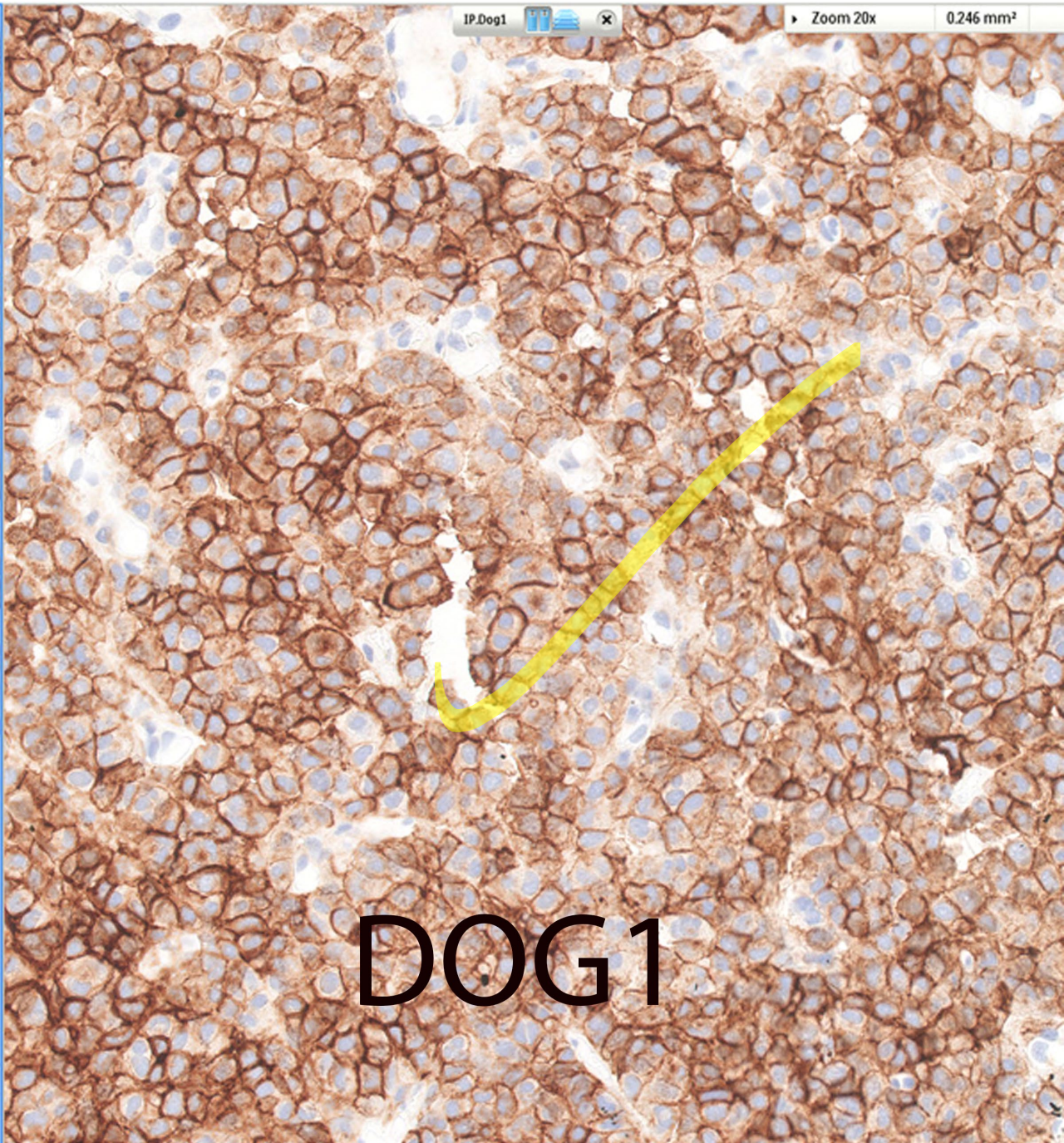
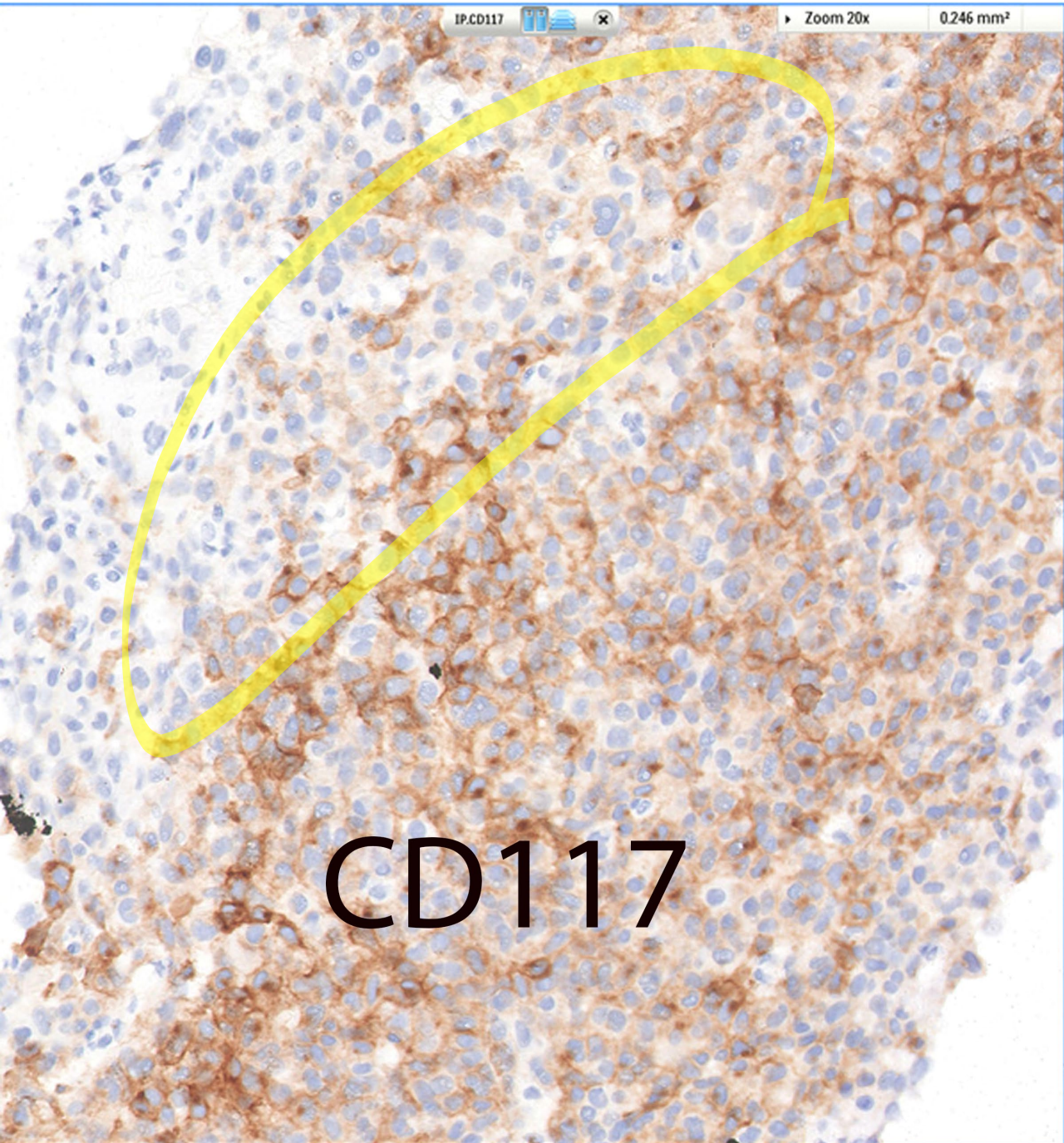






@Vik\_deshpandeMD





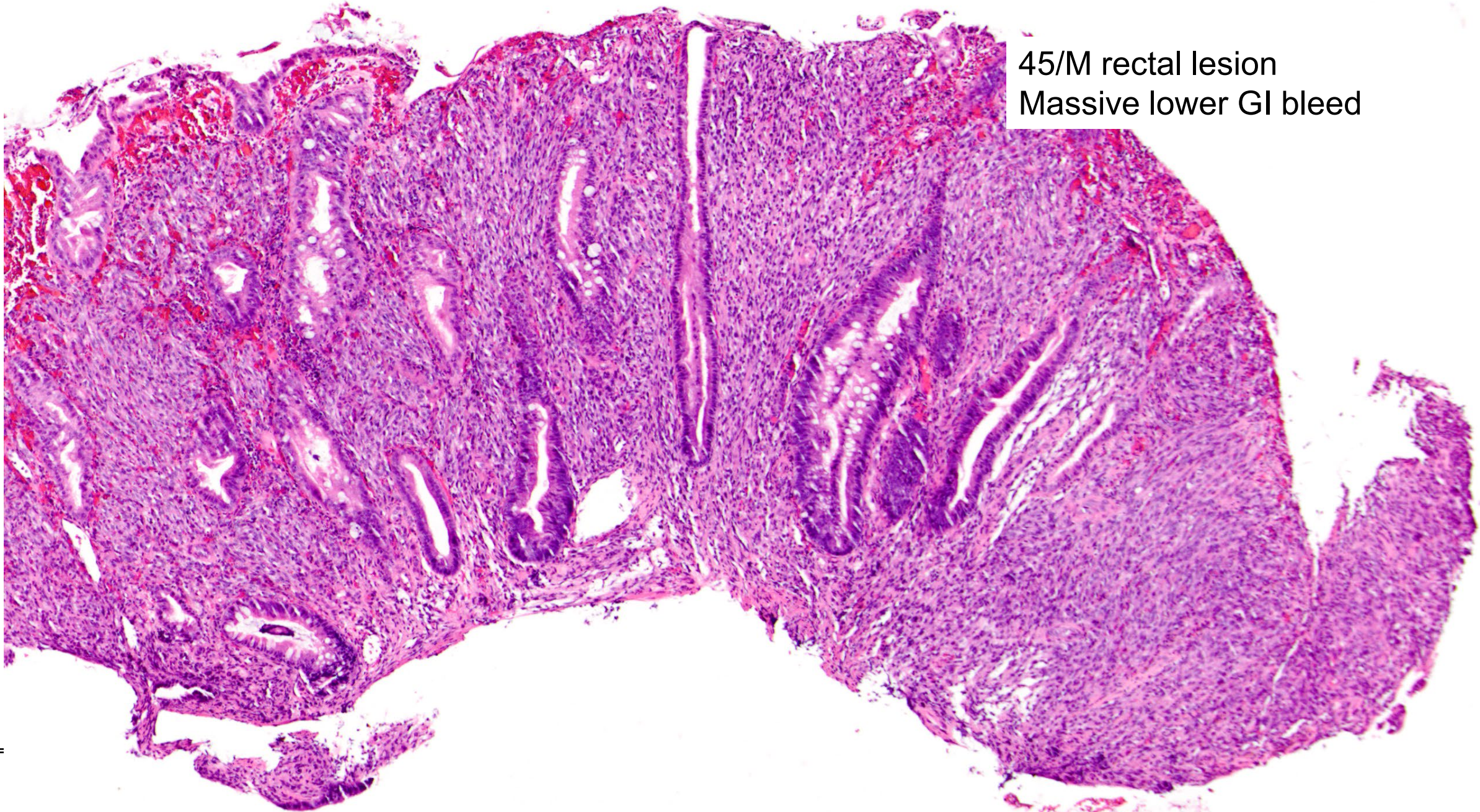


# Desmin



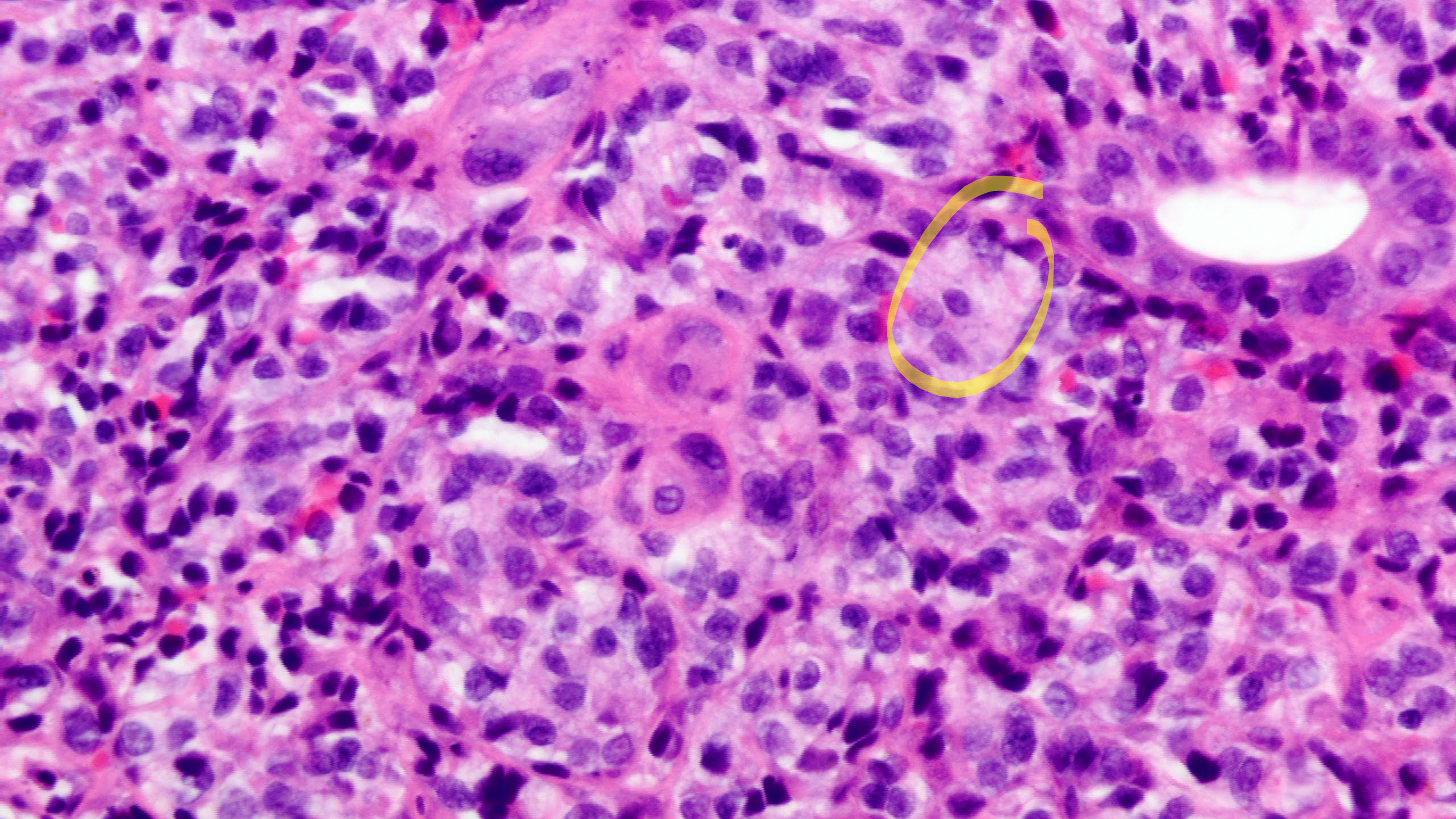
© dashpandemD





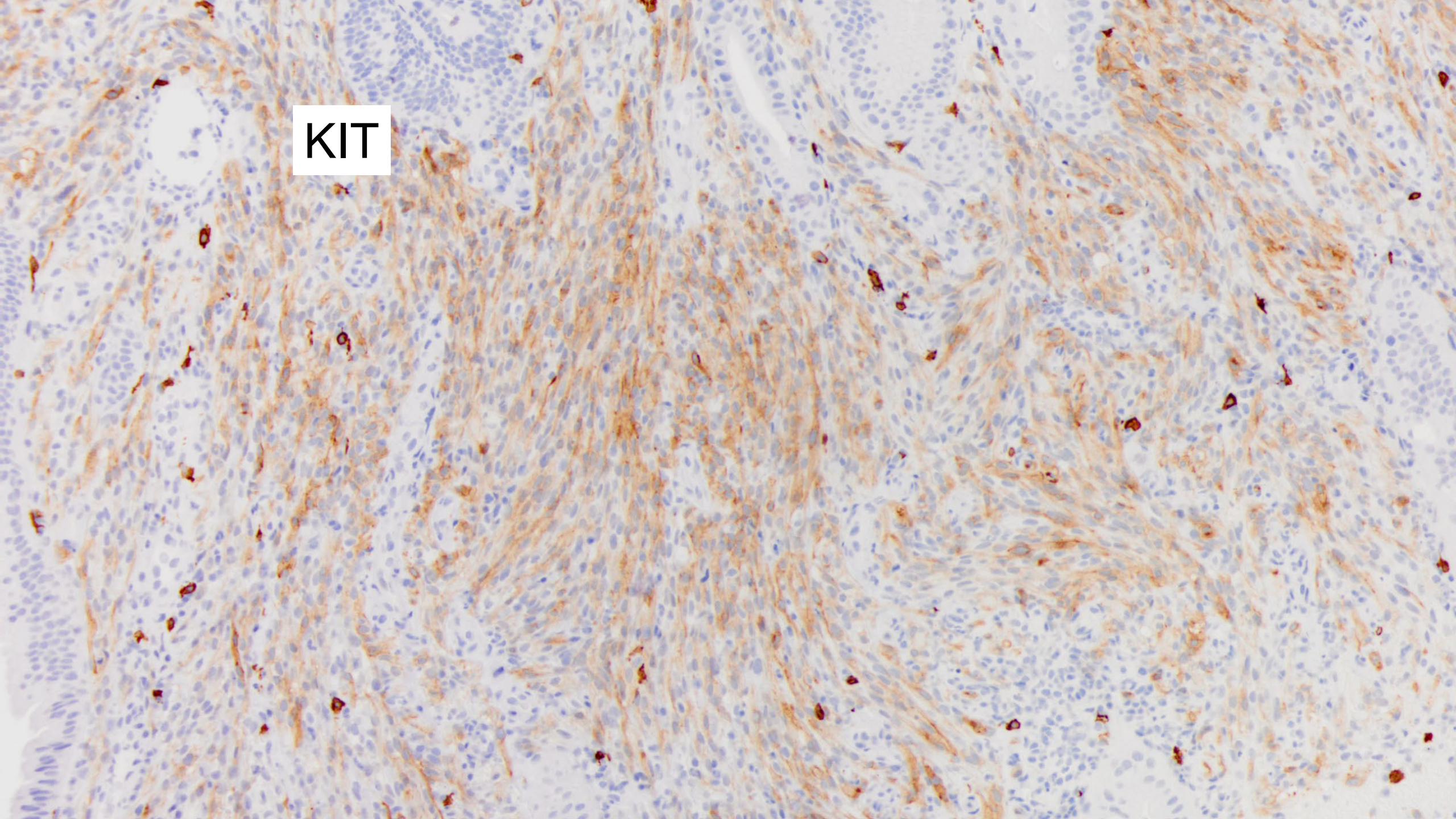
45/M rectal lesion  
Massive lower GI bleed



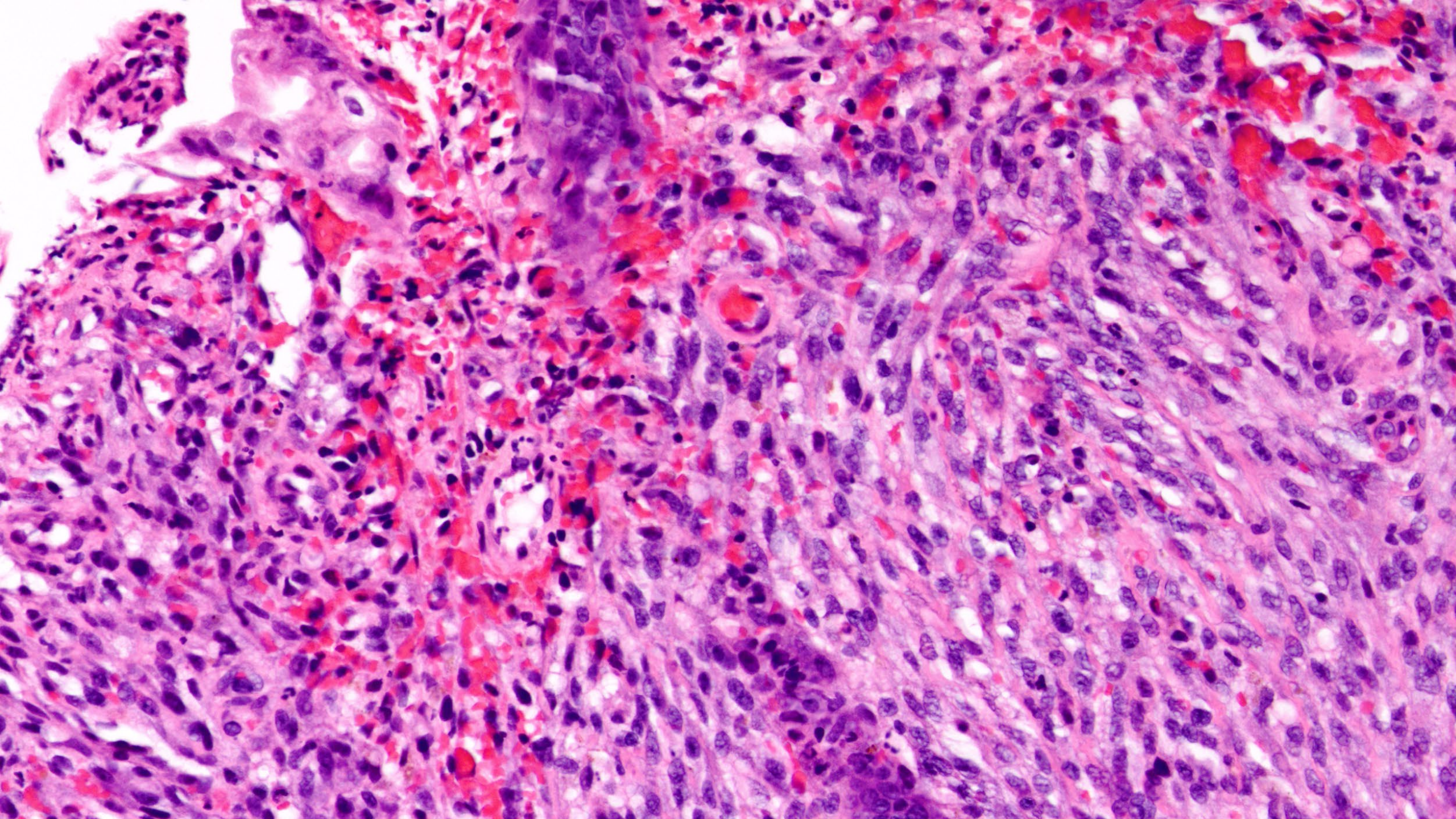




KIT











Kaposi sarcoma

This image shows a histological section of Kaposi sarcoma tissue. The tissue is characterized by a dense population of spindle-shaped cells with brown nuclear staining, indicating the presence of ERG and HHV8. The background is a light blue counterstain.

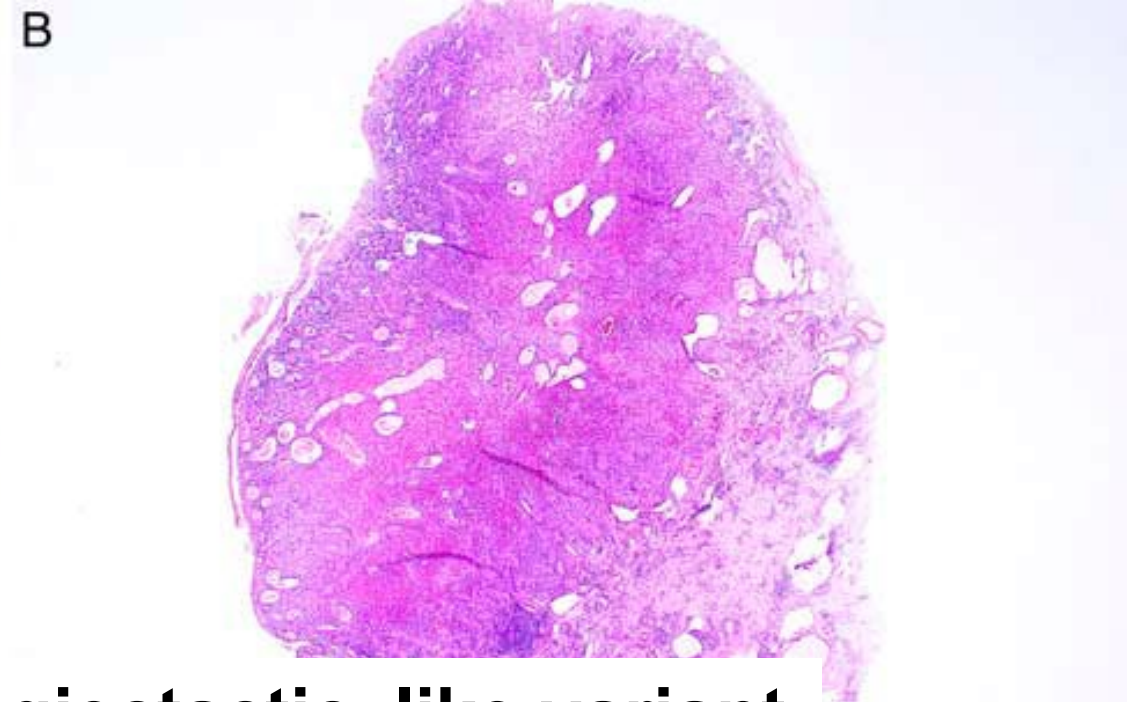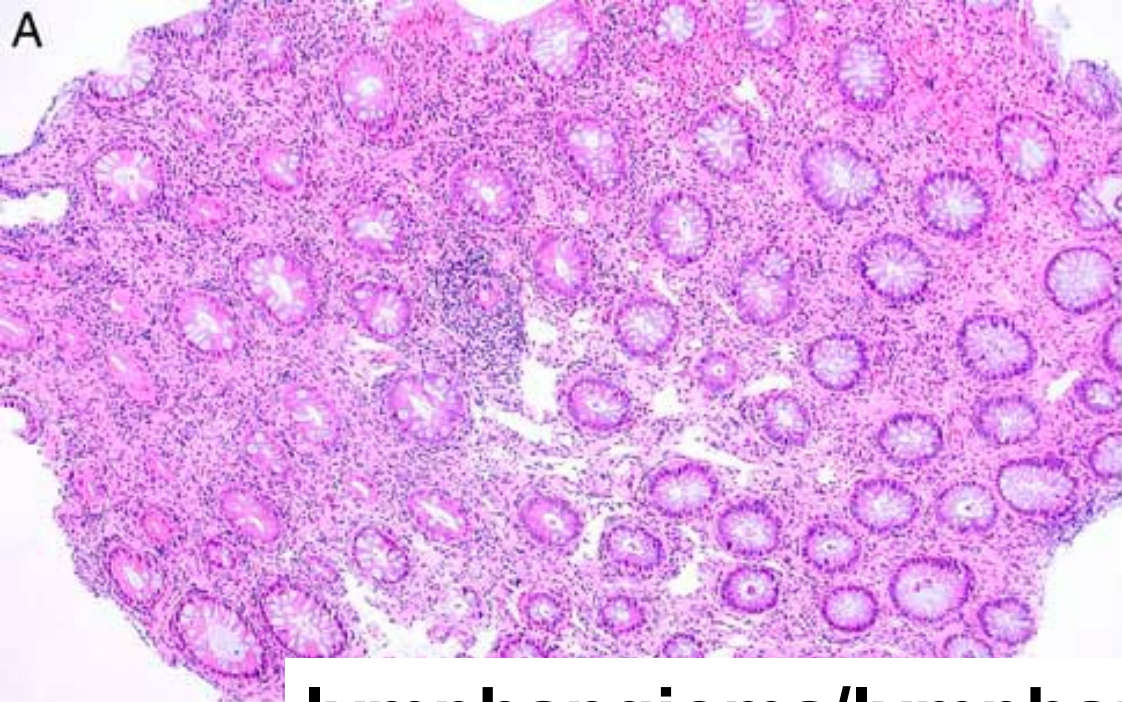


ERG

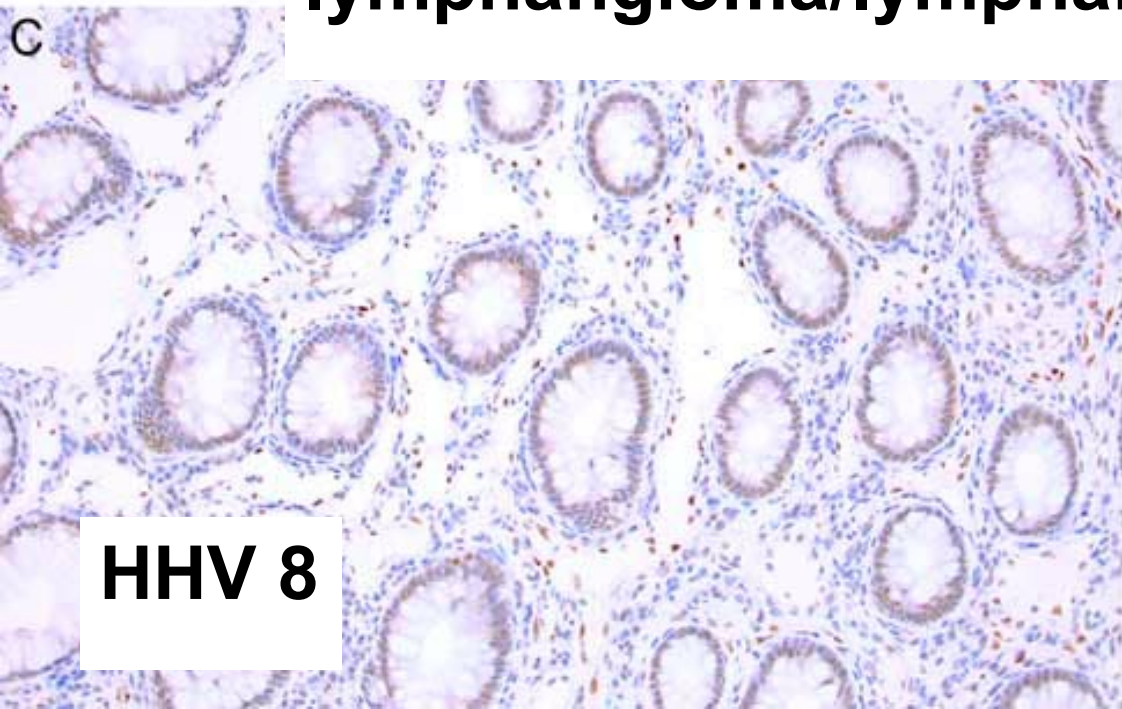
This inset image shows a magnified view of the Kaposi sarcoma tissue, highlighting the brown nuclear staining for ERG. The spindle-shaped cells are clearly visible, and the brown staining is concentrated in the nuclei.

HHV8

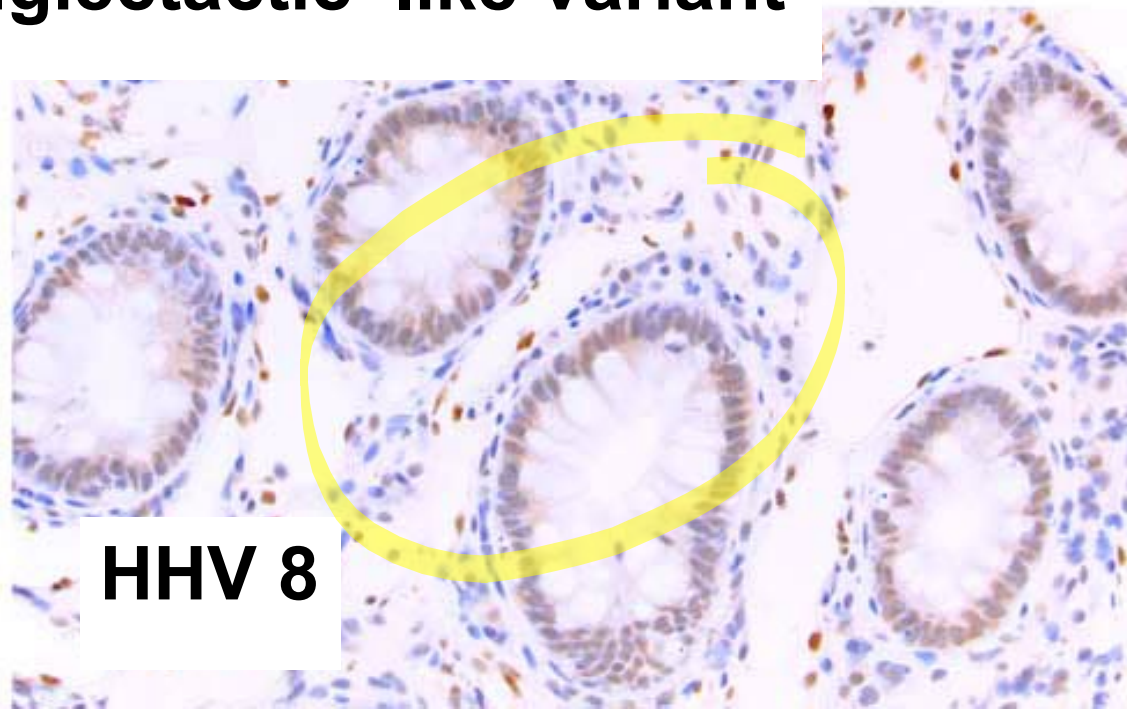




**lymphangioma/lymphangiectatic-like variant**

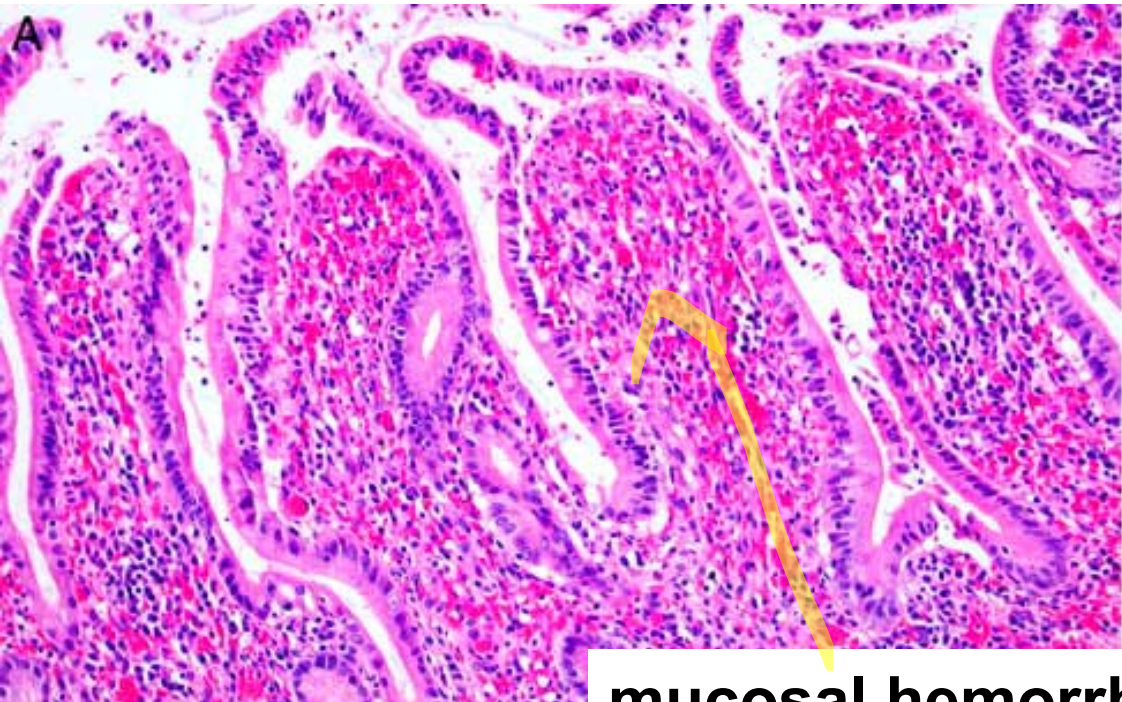


**HHV 8**

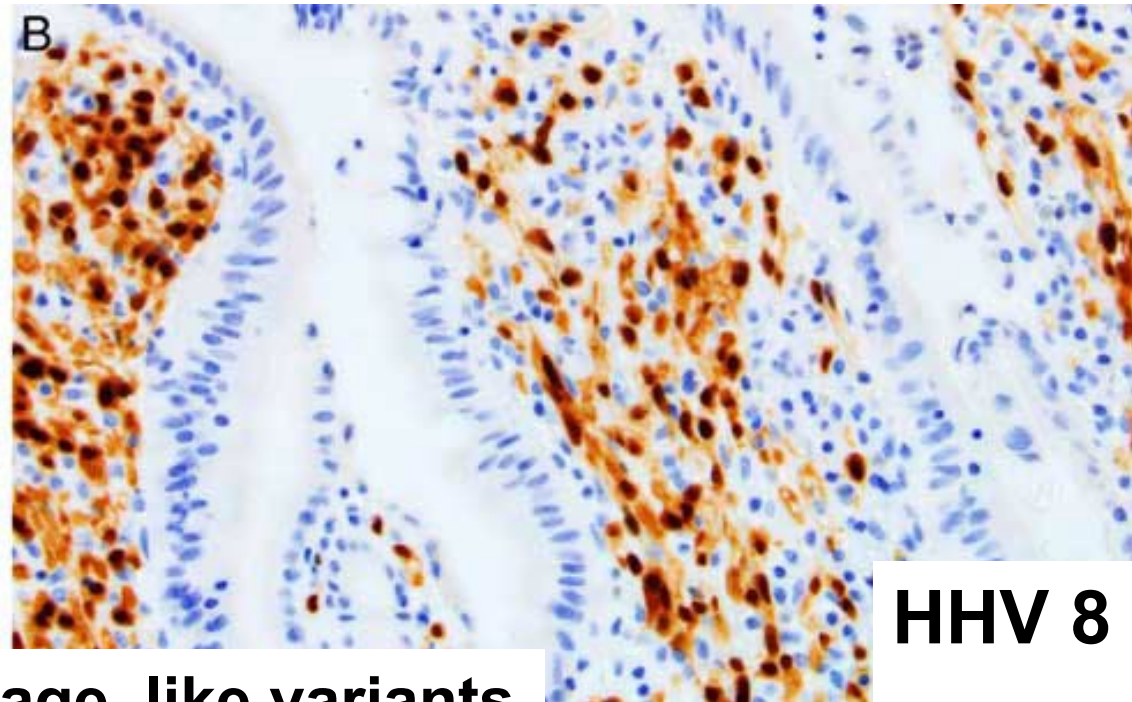


**HHV 8**

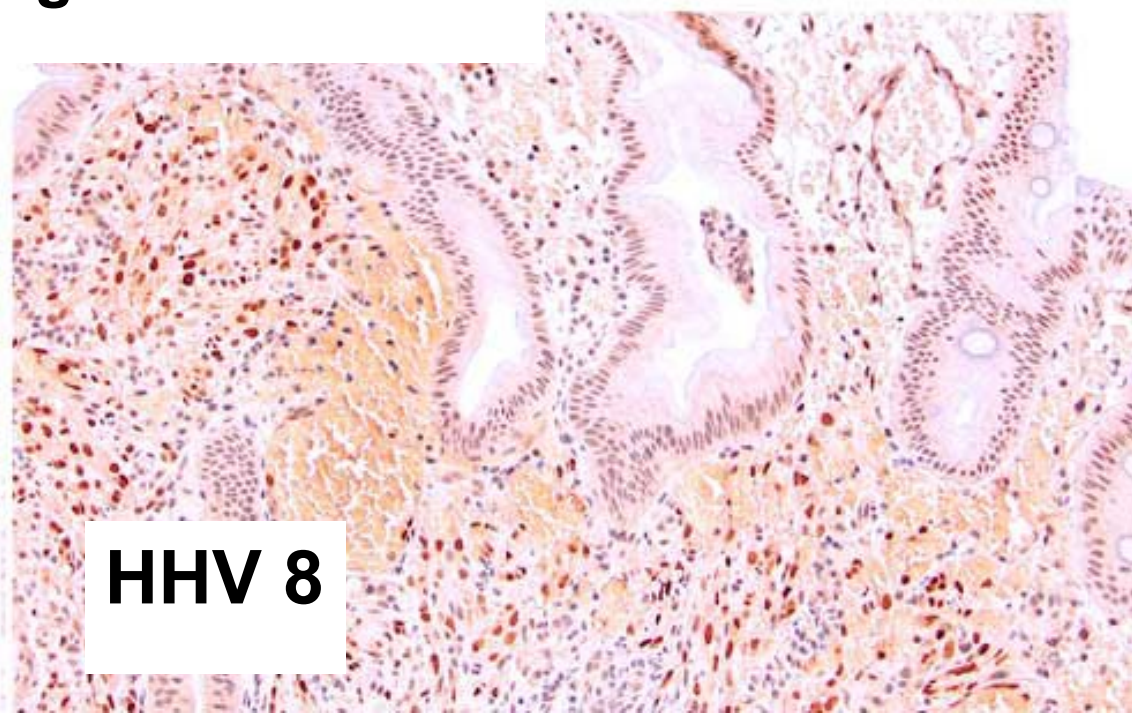
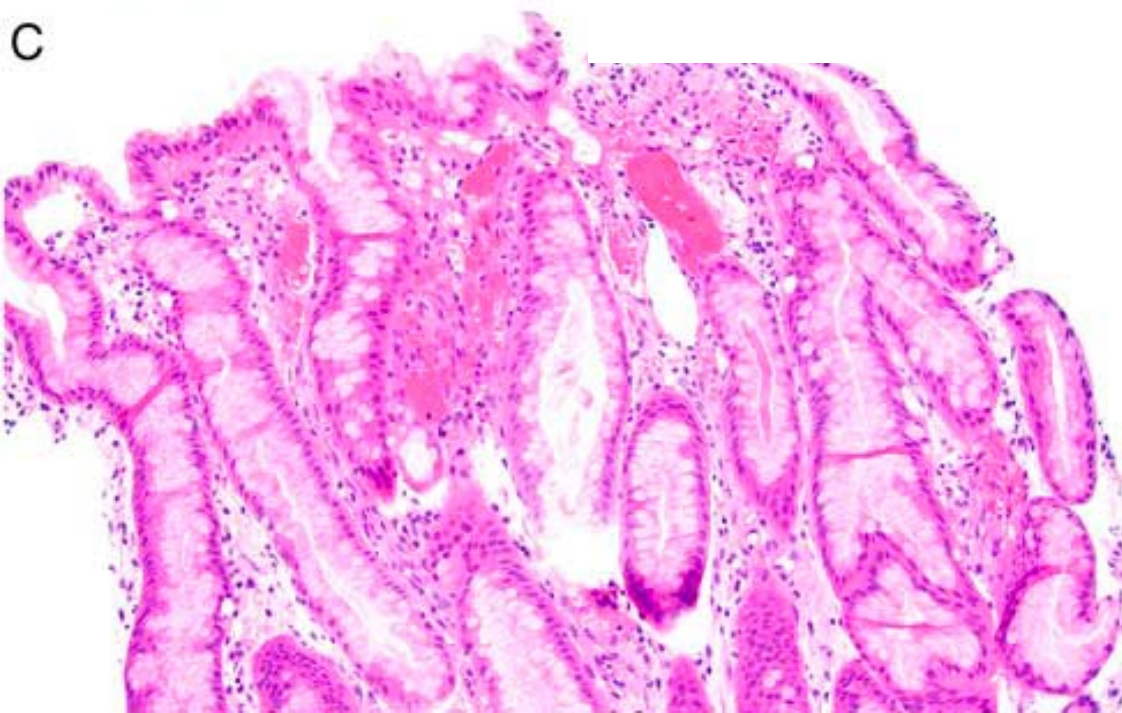




**mucosal hemorrhage-like variants**



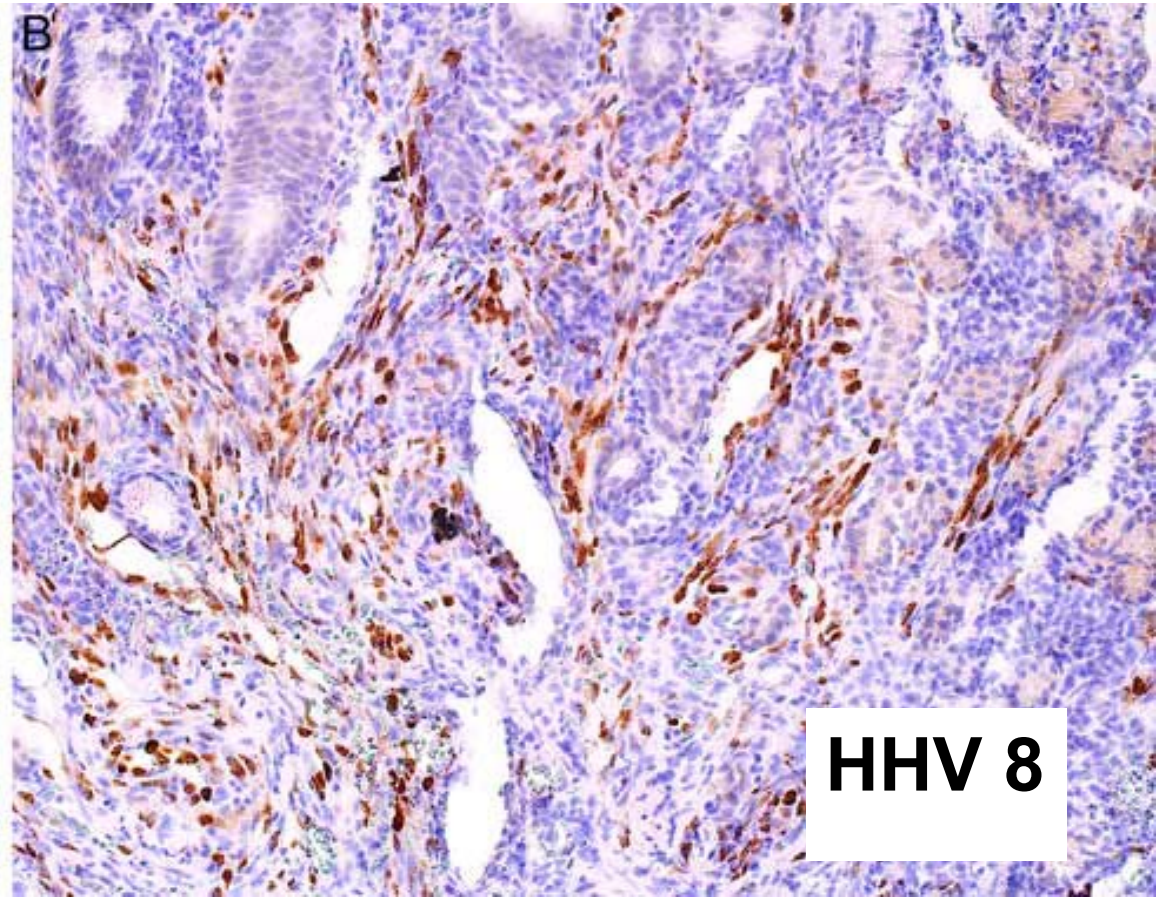
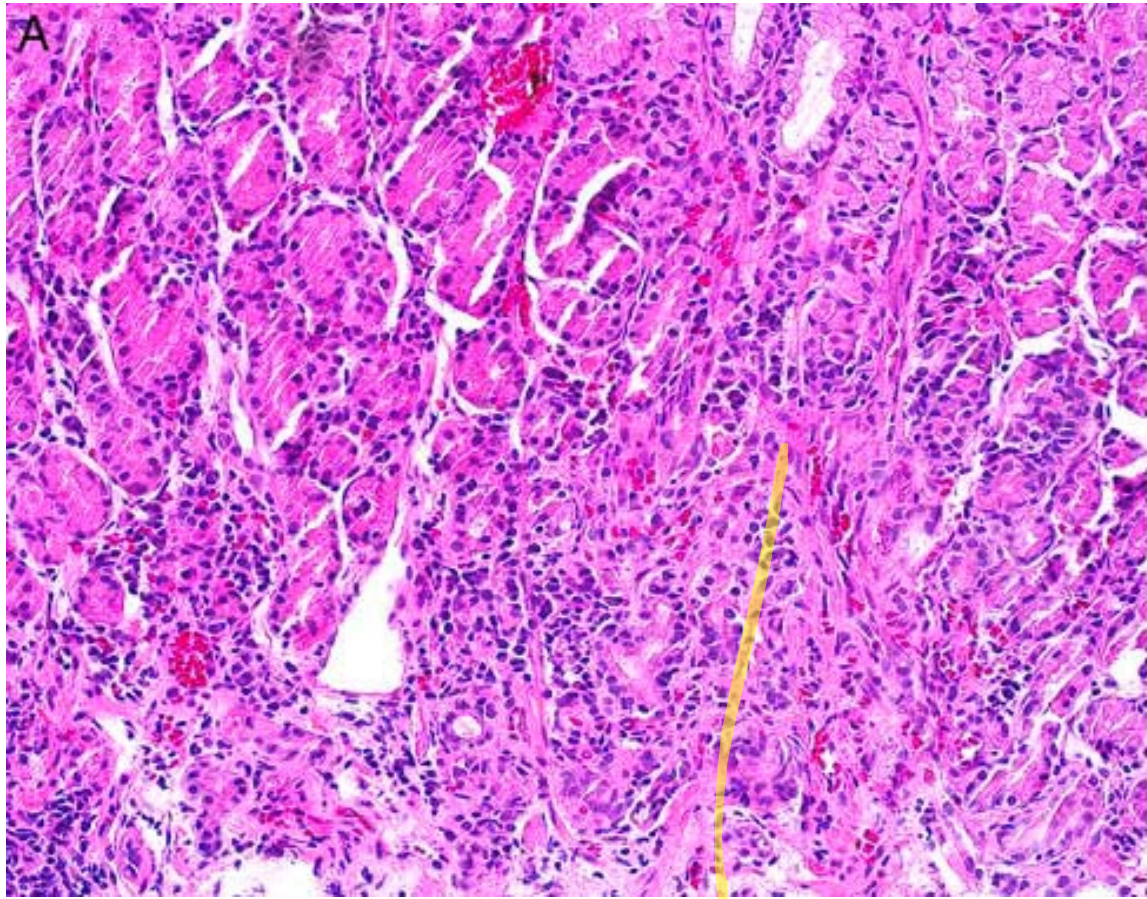
**HHV 8**



**HHV 8**

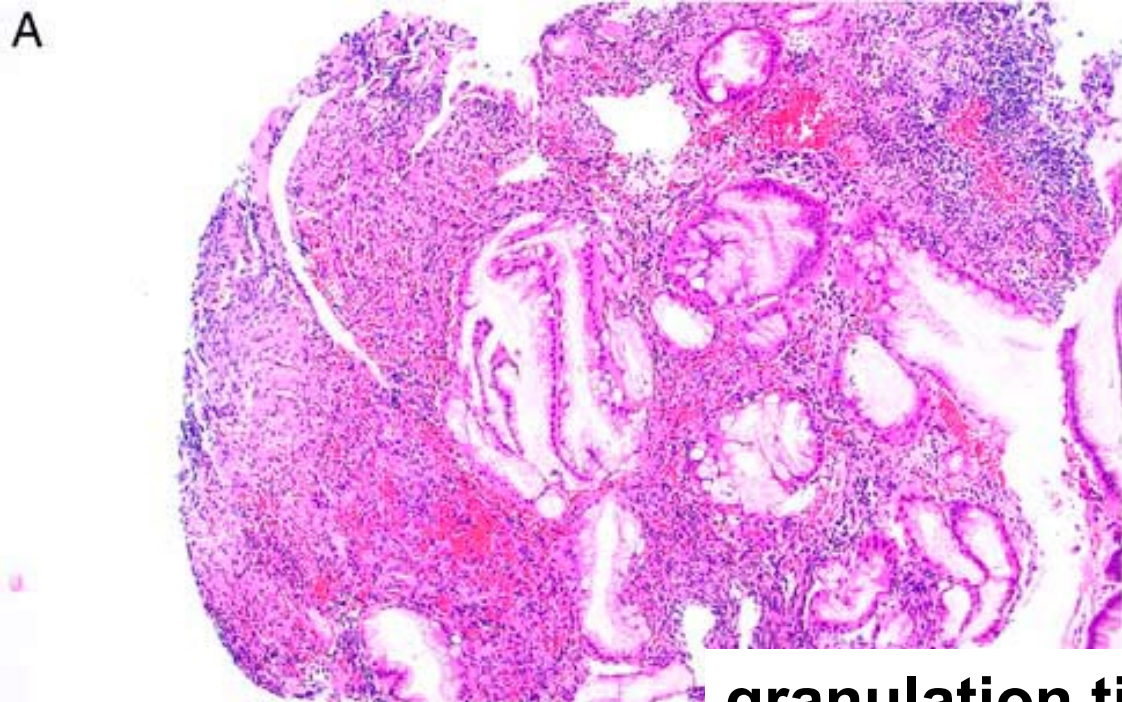


# mucosal inflammation–like variant

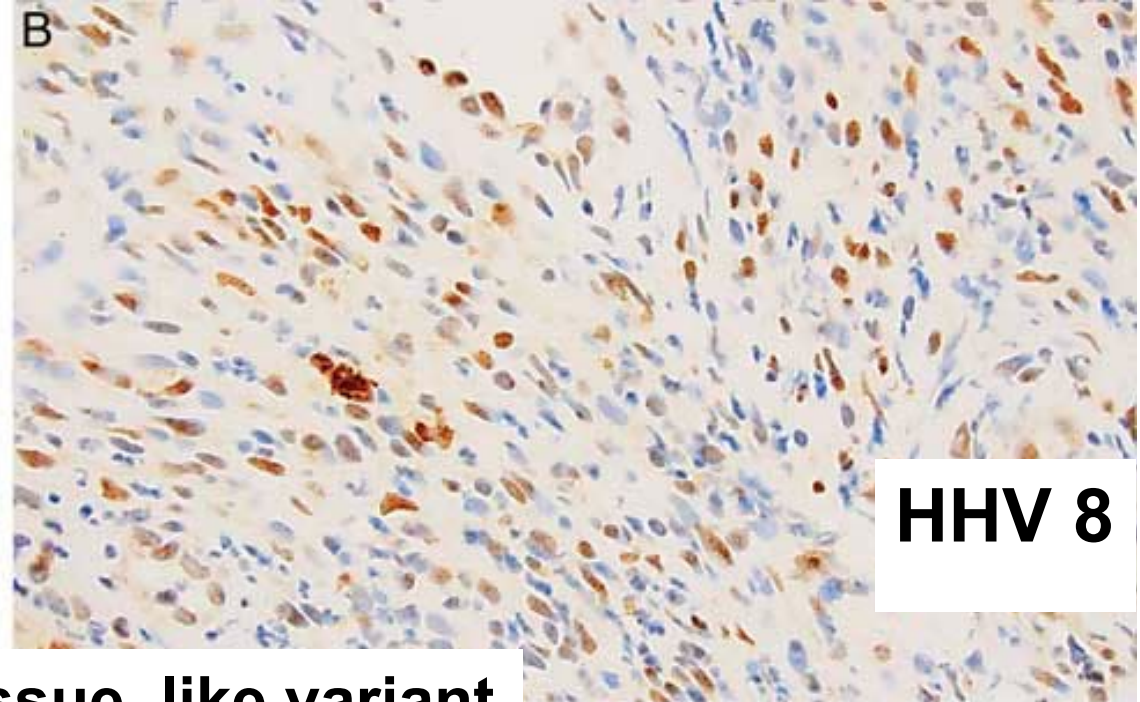


Am J Surg Pathol. 2022 Aug 17. PMID: 35973011

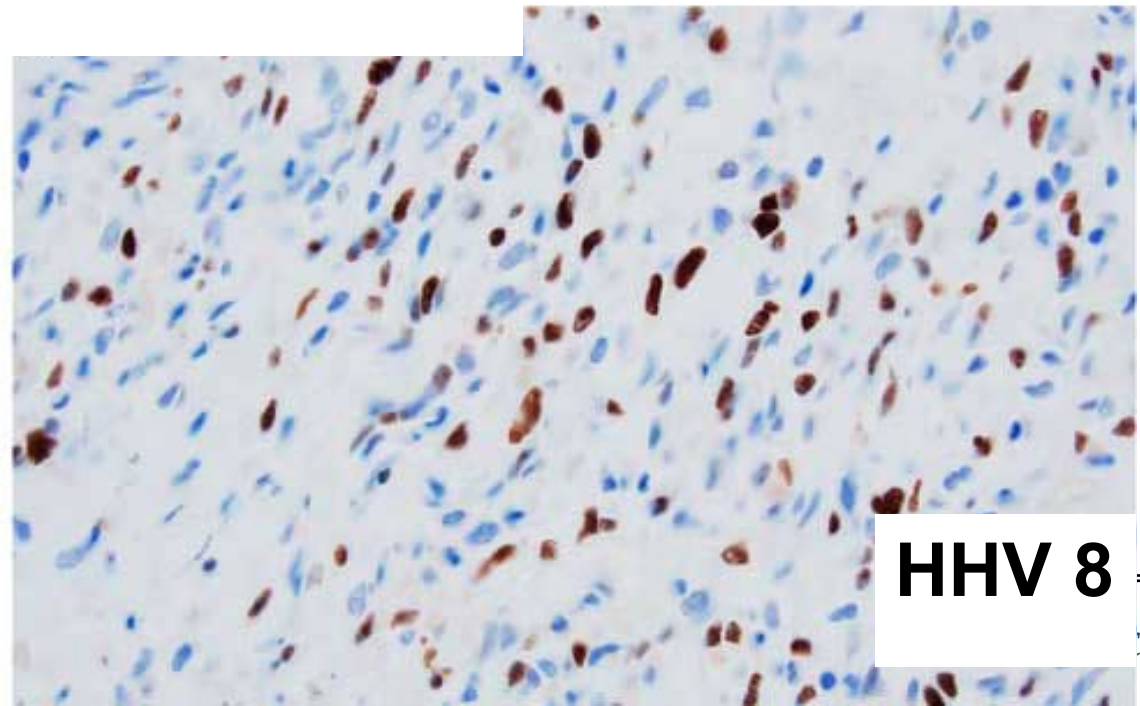
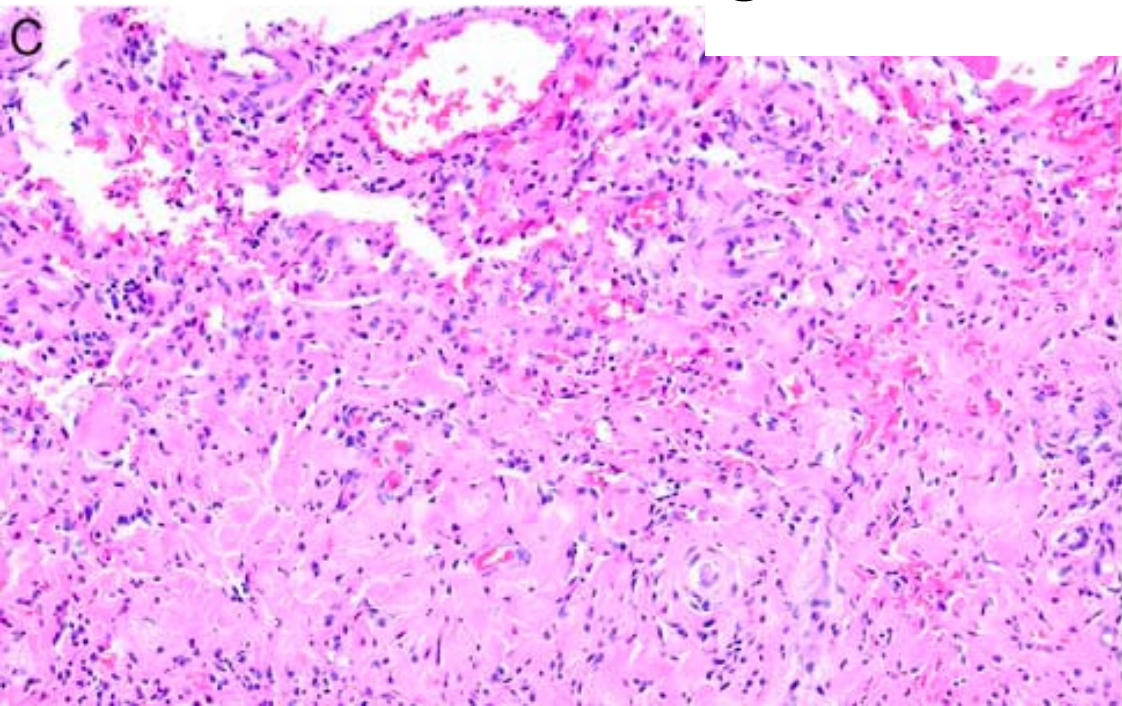




granulation tissue-like variant



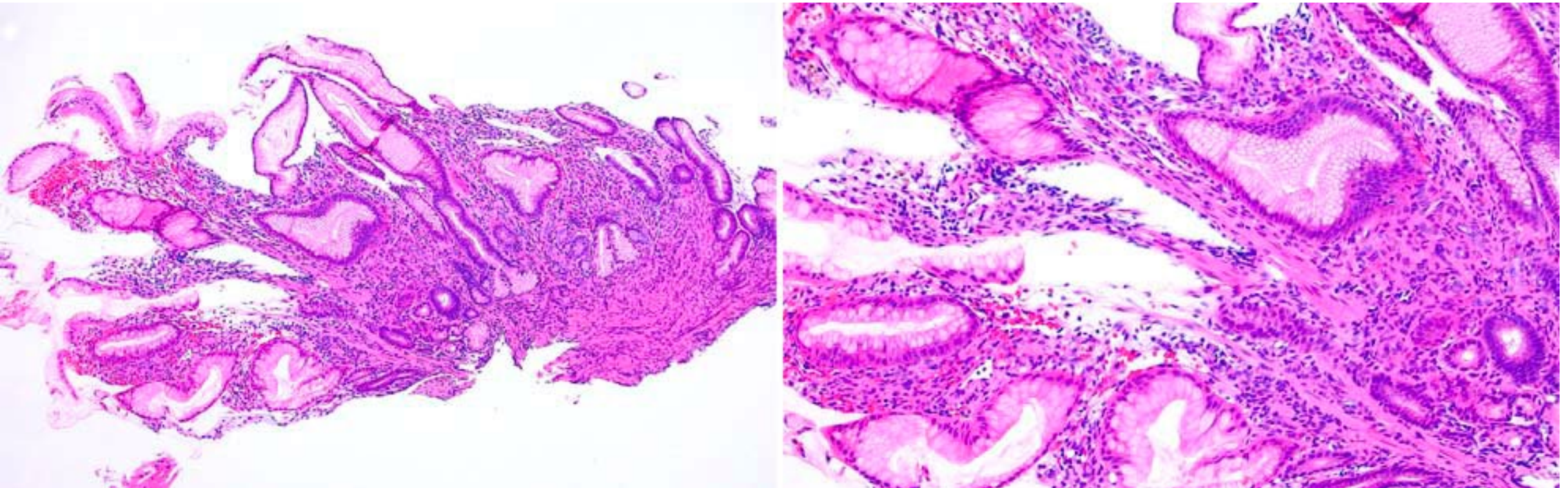
HHV 8



HHV 8



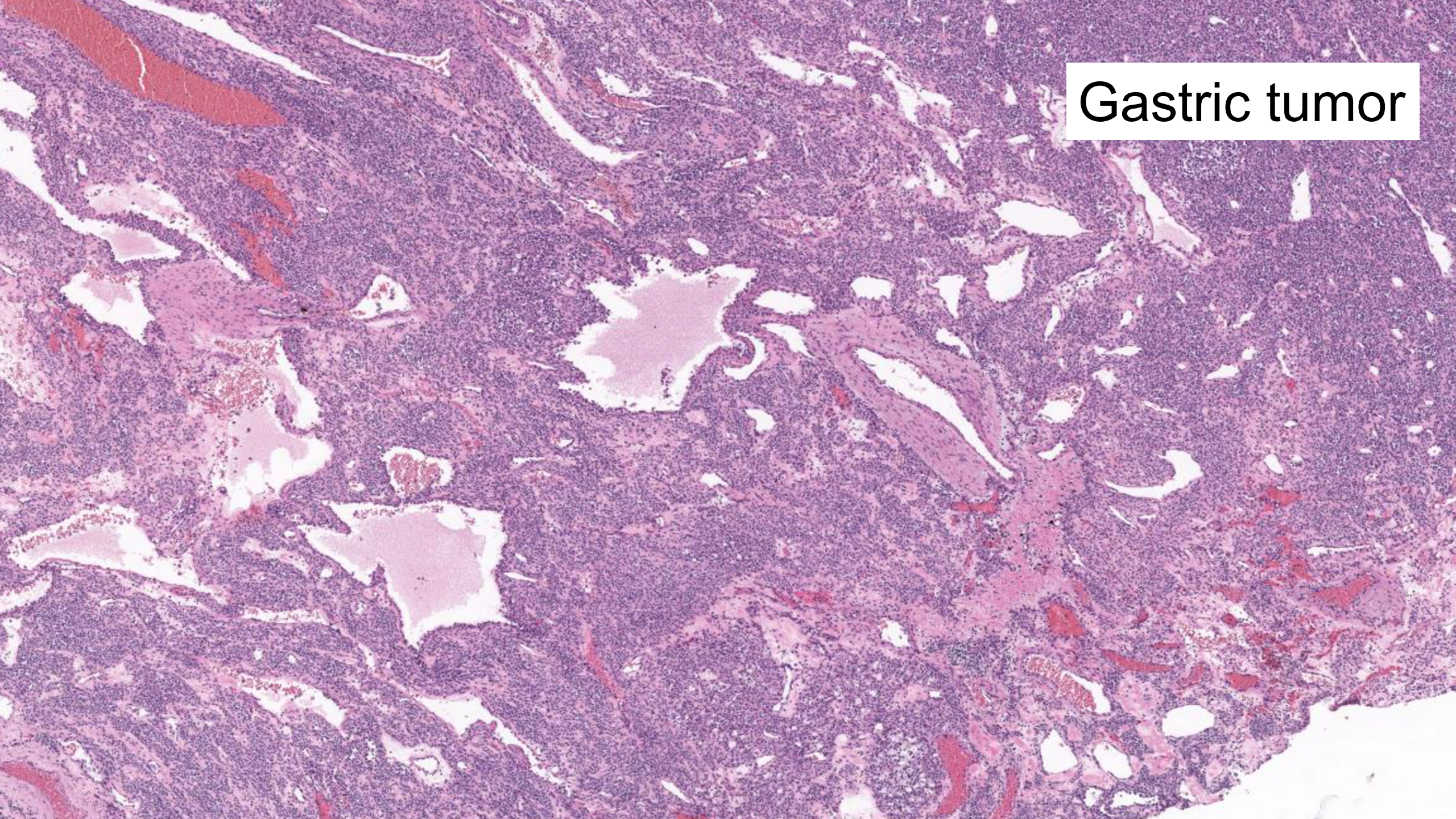
# Mucosal prolapse–like variant



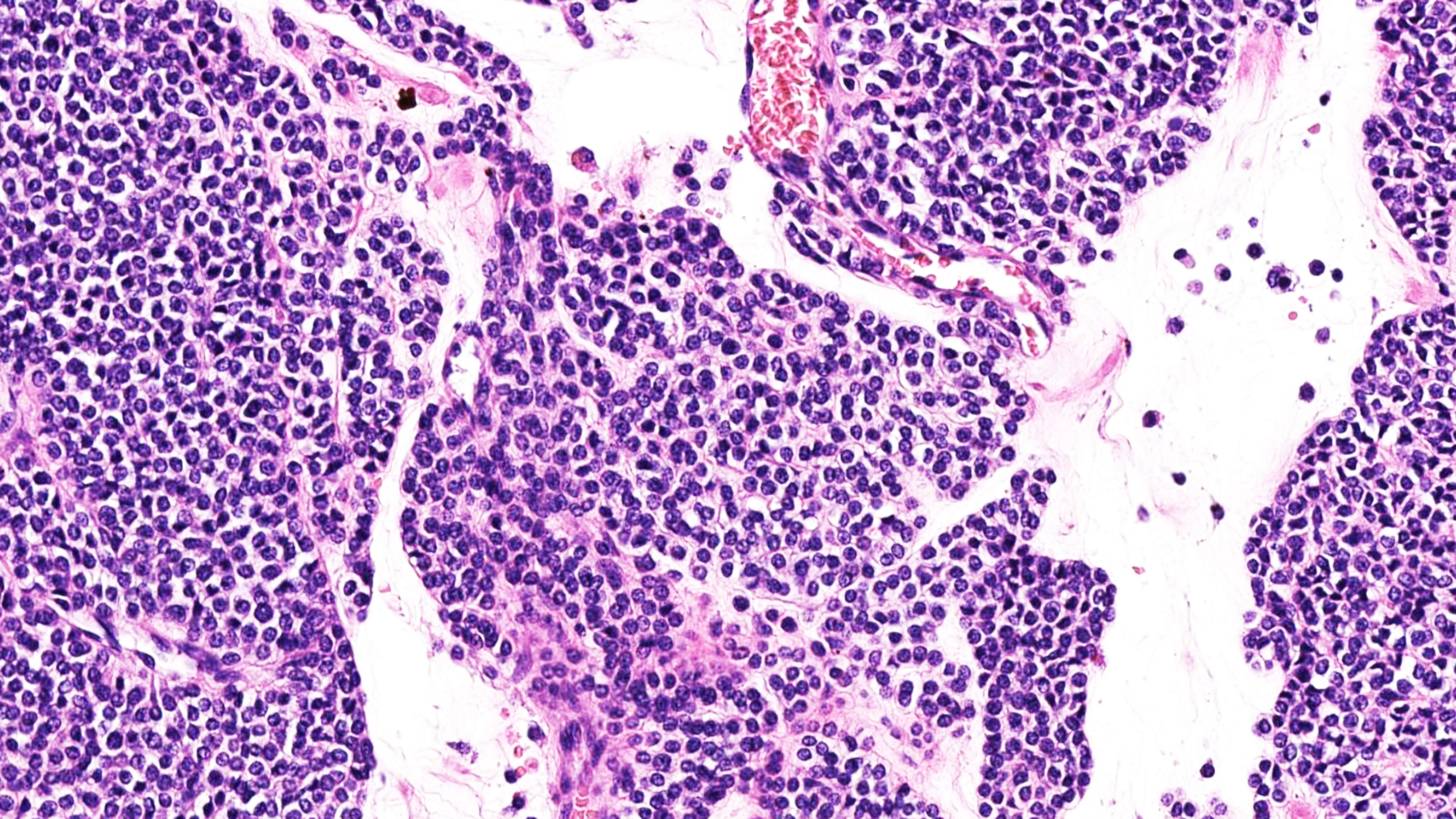
Am J Surg Pathol. 2022 Aug 17. PMID: 35973011.



Gastric tumor

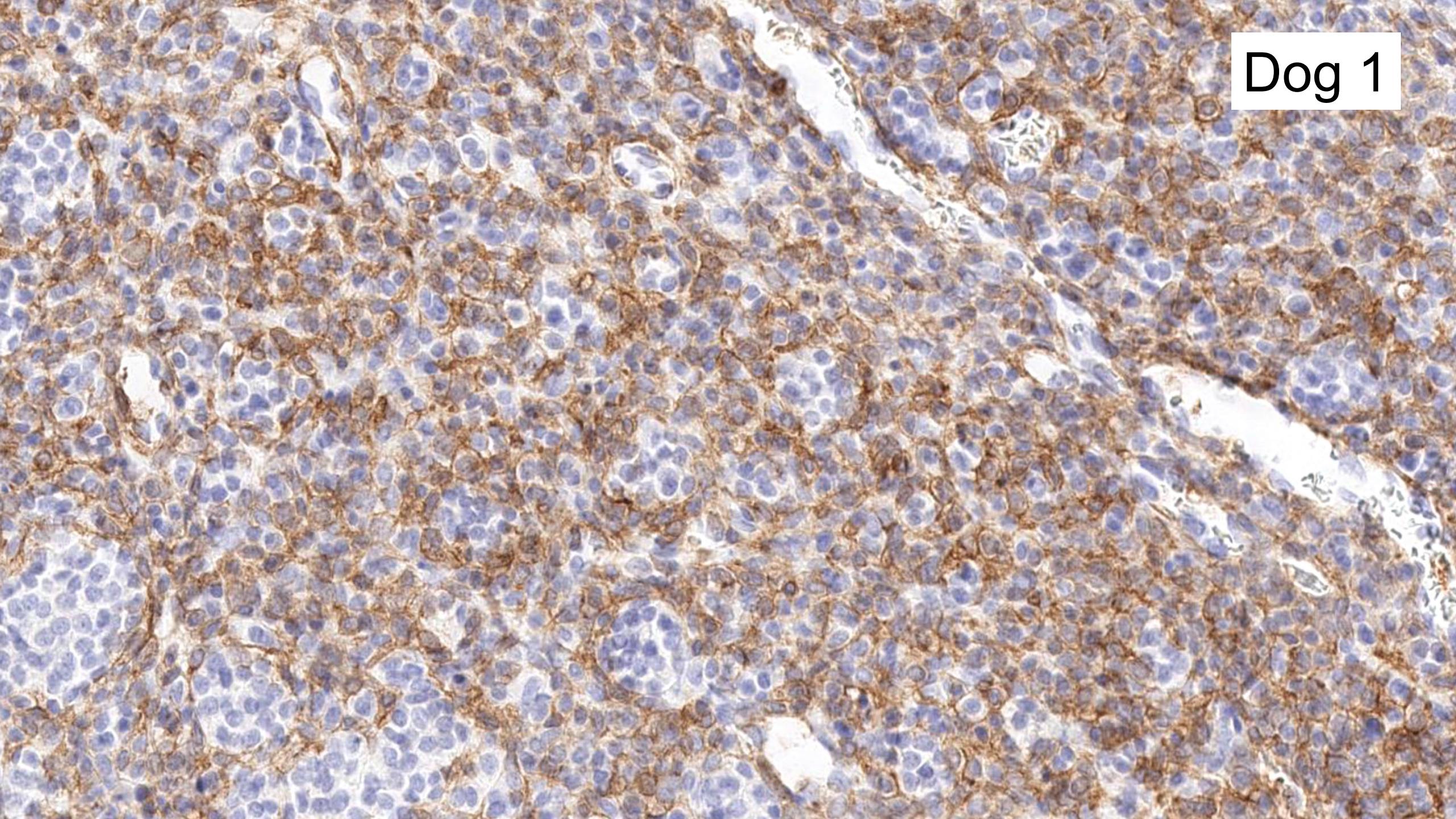






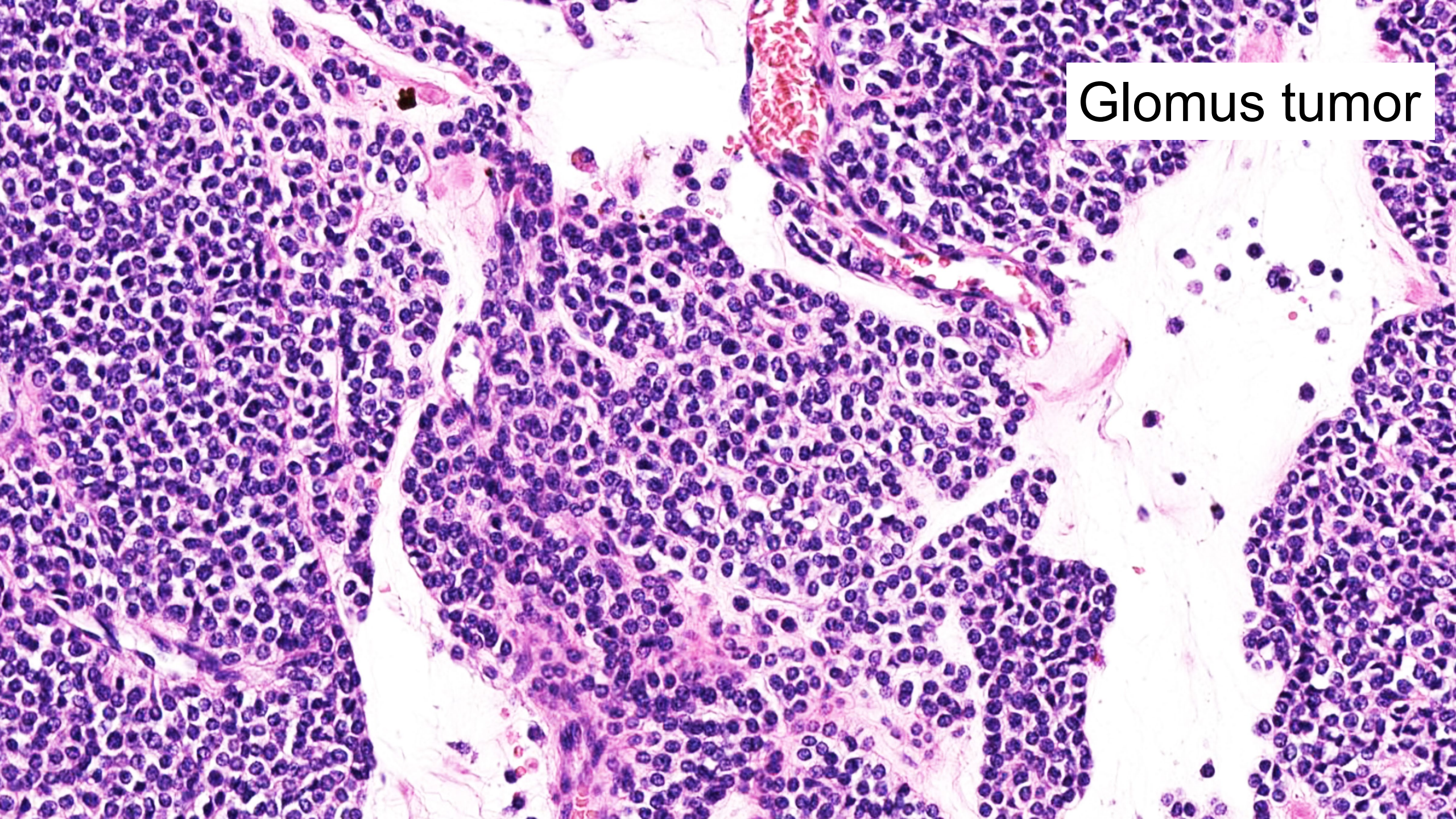


Dog 1



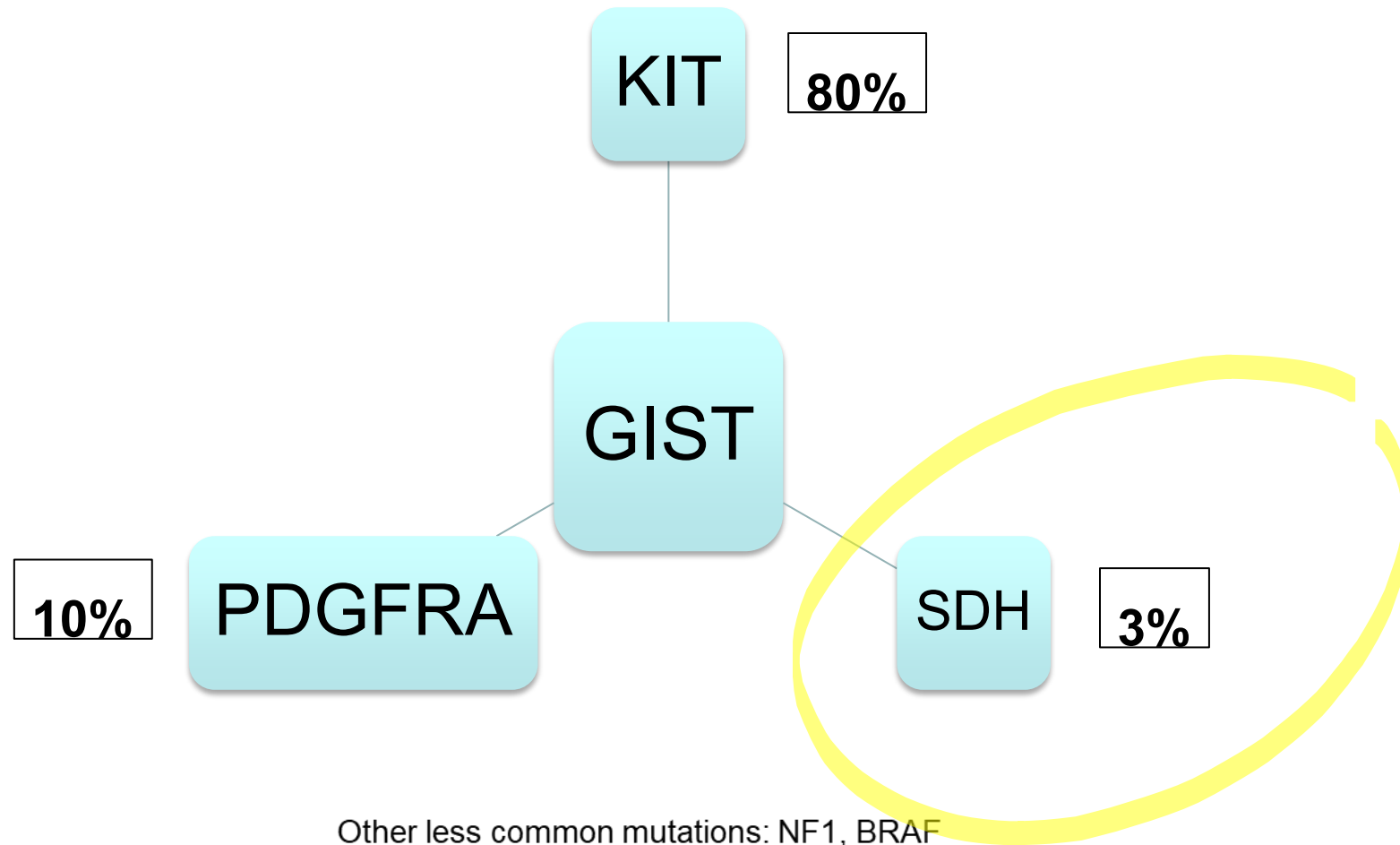


Glomus tumor



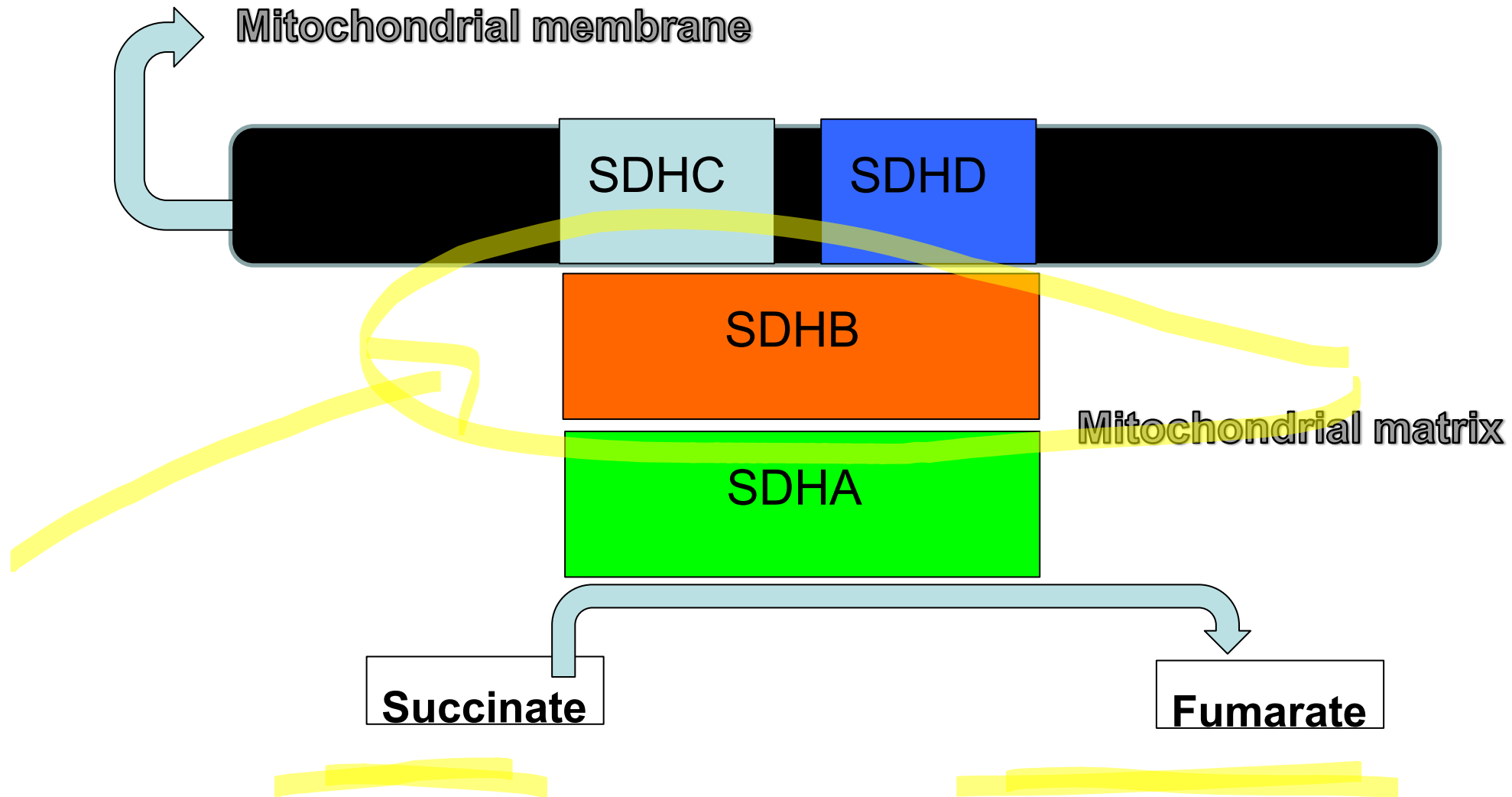


# GENETIC ALTERATIONS GIST



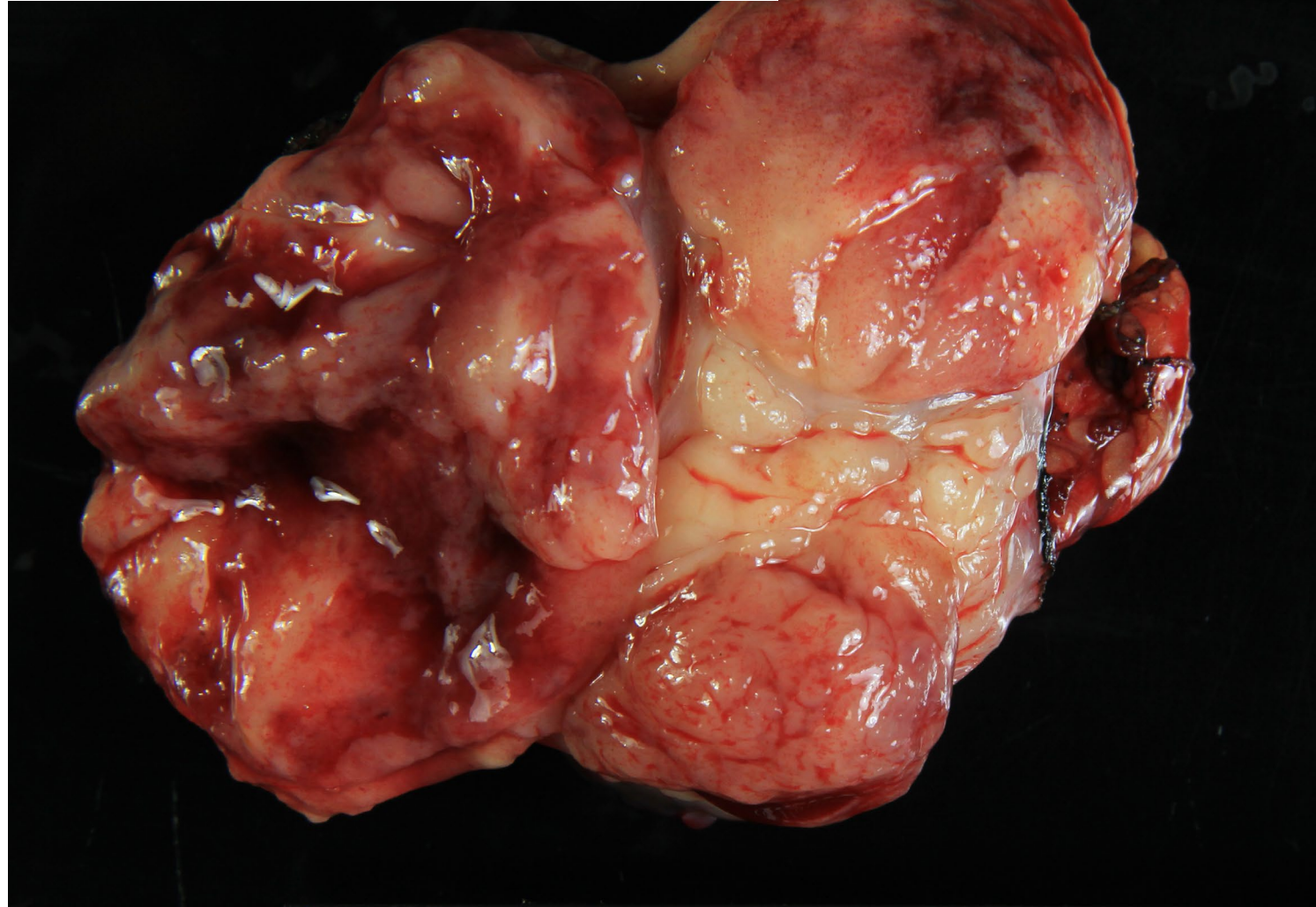


# SDH mutations in GIST






# SDH deficient GIST



Mass General Hospital Pathology Department

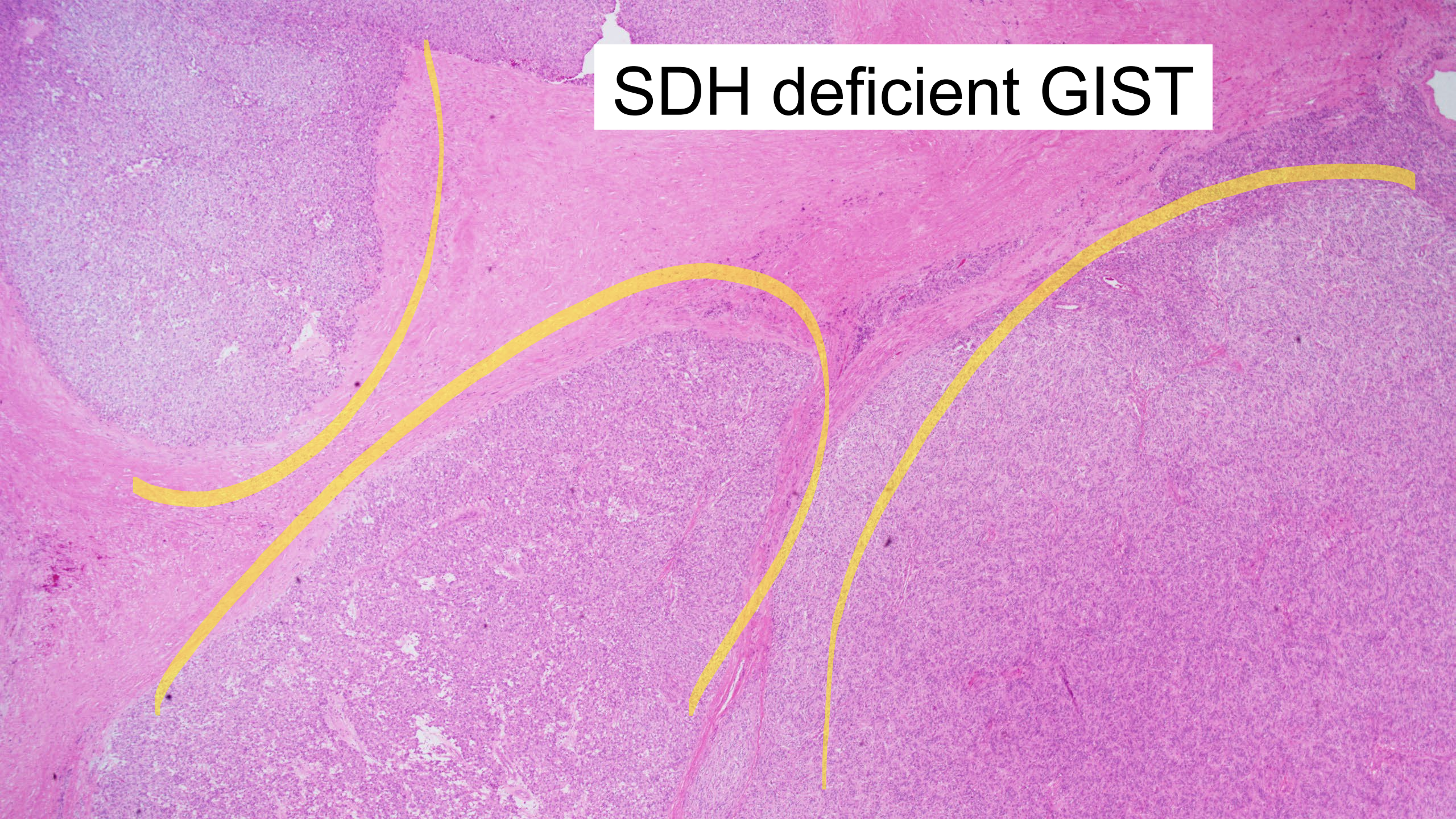

MASSACHUSETTS  
GENERAL HOSPITAL

HARVARD  
MEDICAL SCHOOL

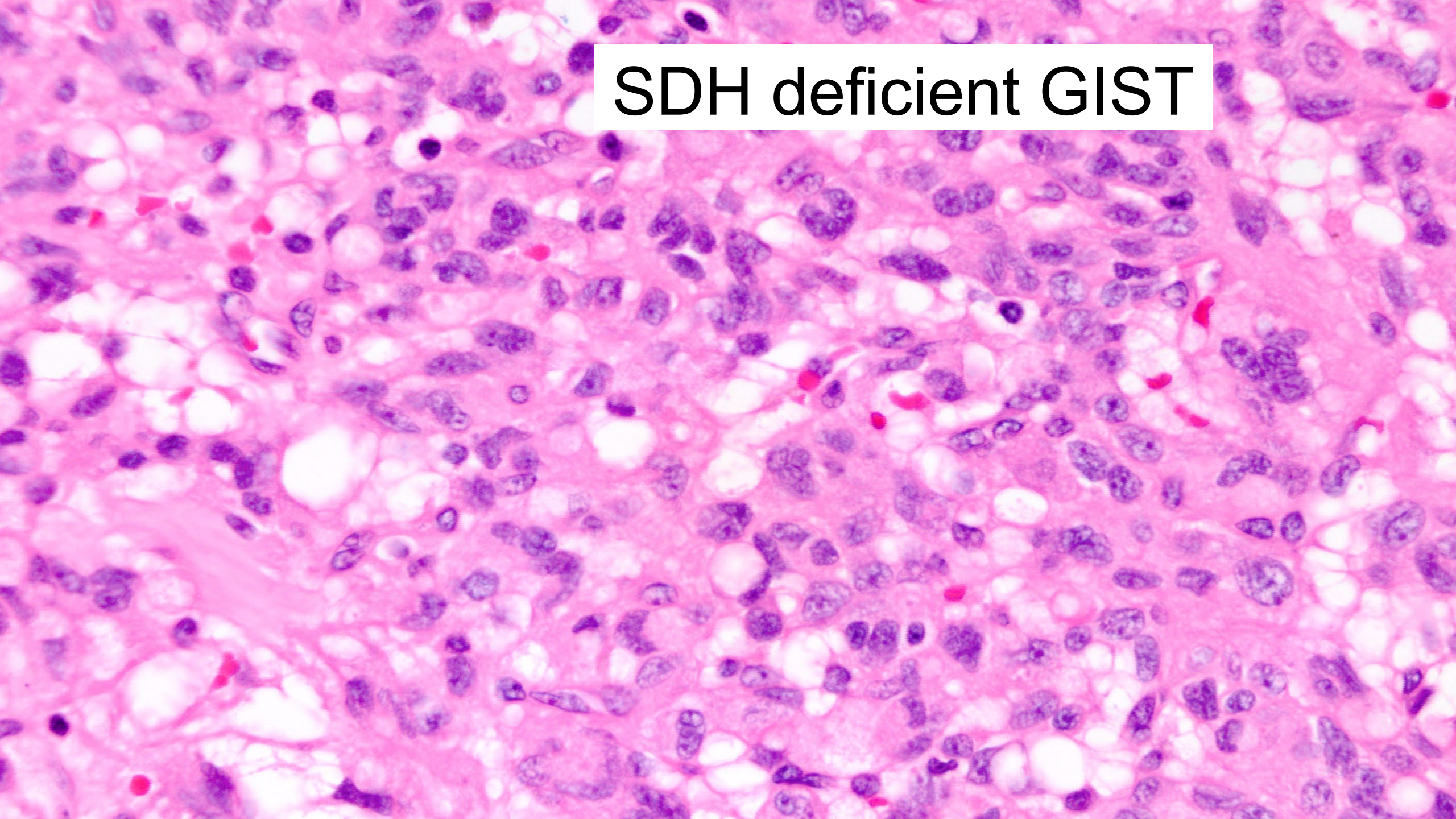


# SDH deficient GIST





# SDH deficient GIST





SDHB

Surrogate marker for the entire  
SDH complex



# SDH deficient GIST

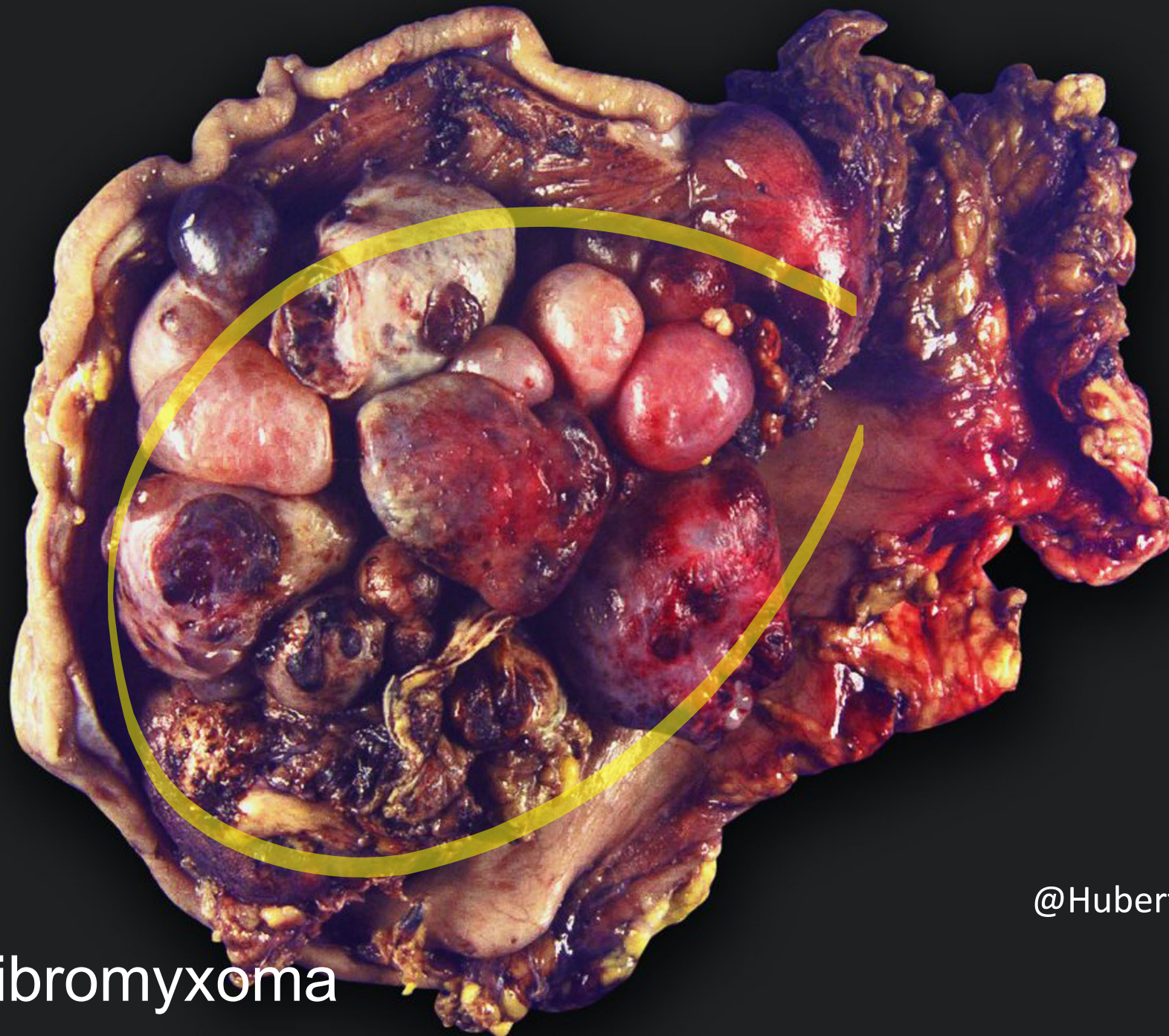- Majority <40
- Conventional criteria fail to predict aggressive behavior
- Association with syndrome
  - Carney Stratakis syndrome
  - Carney triad
- Do not respond to targeted therapy
  - Imatinib



# Plexiform Fibromyxoma

- 5<sup>th</sup> decade
- Benign tumor almost always arises in stomach (antrum)
  - Muscle layer
- Complete excision is curative
- Vascular invasion is often present and has no apparent significance
- *MALAT1-GLI1* fusions and *GLI1* polysomy





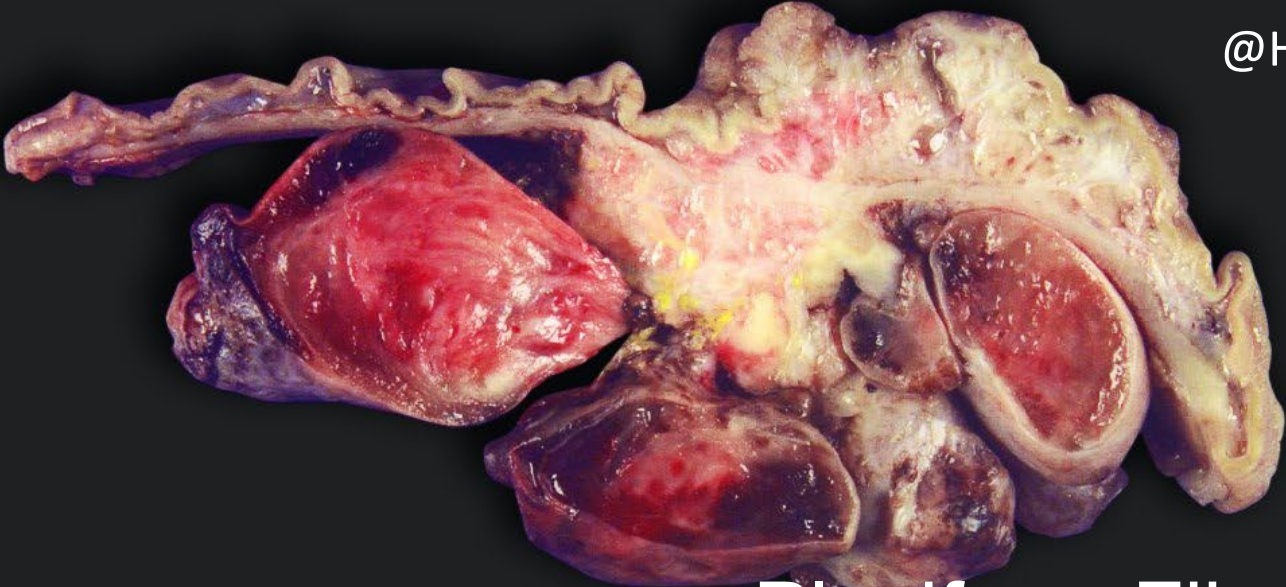
@HubertLauMD

Plexiform Fibromyxoma

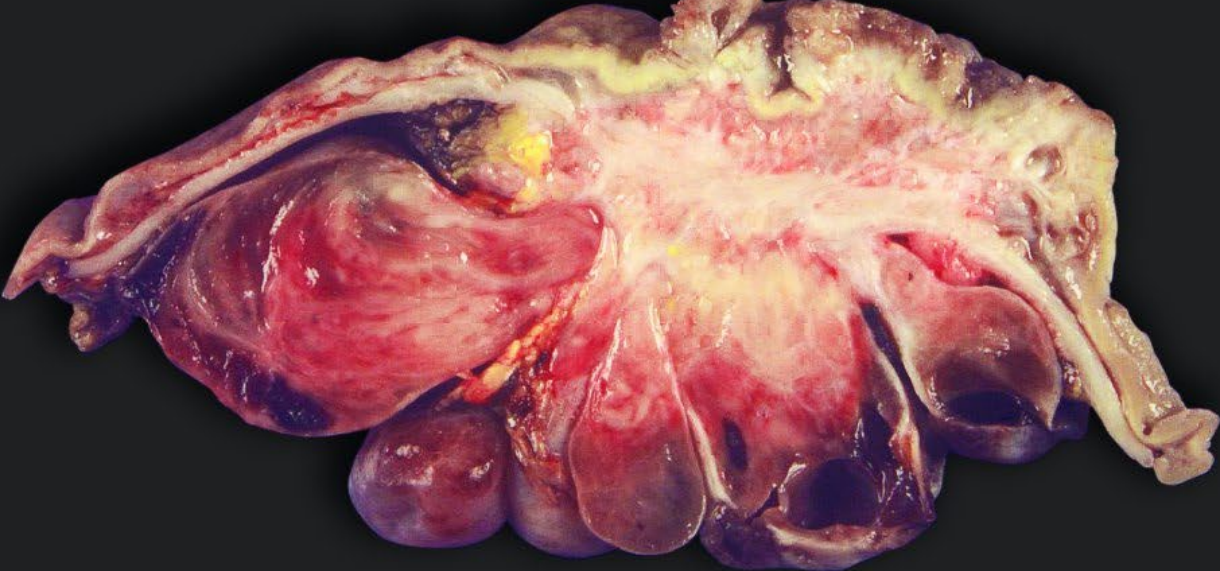

*cross-sections*

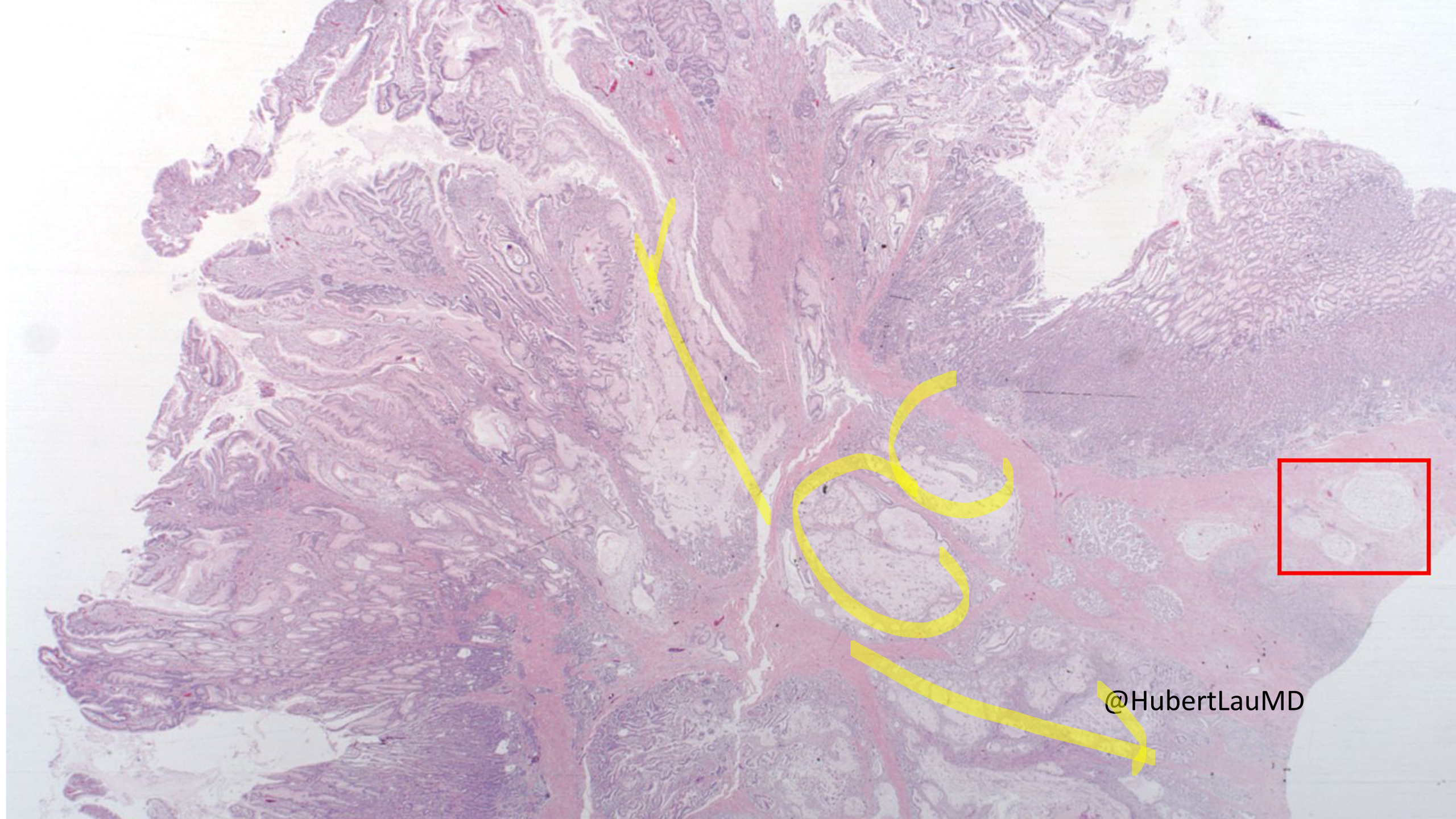
@HubertLauMD



# Plexiform Fibromyxoma

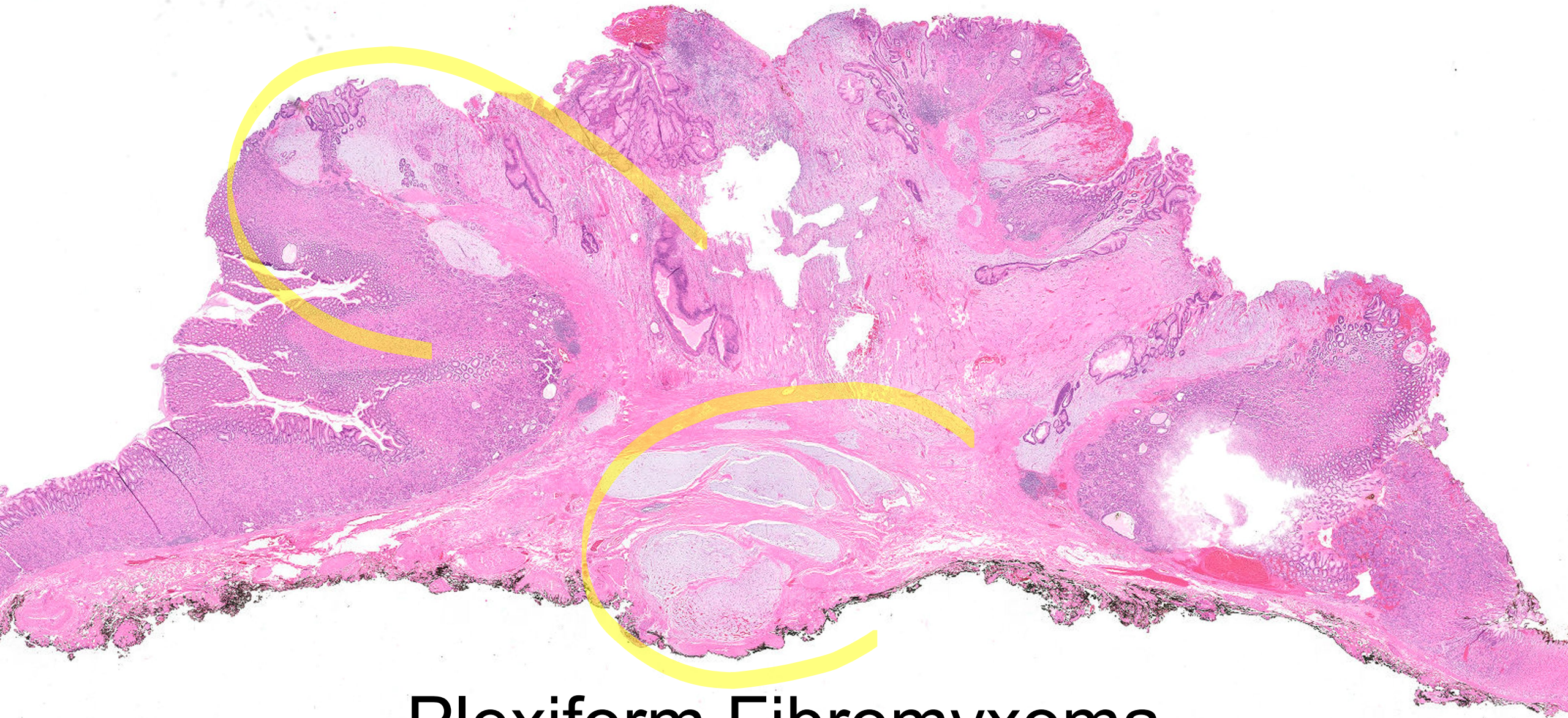





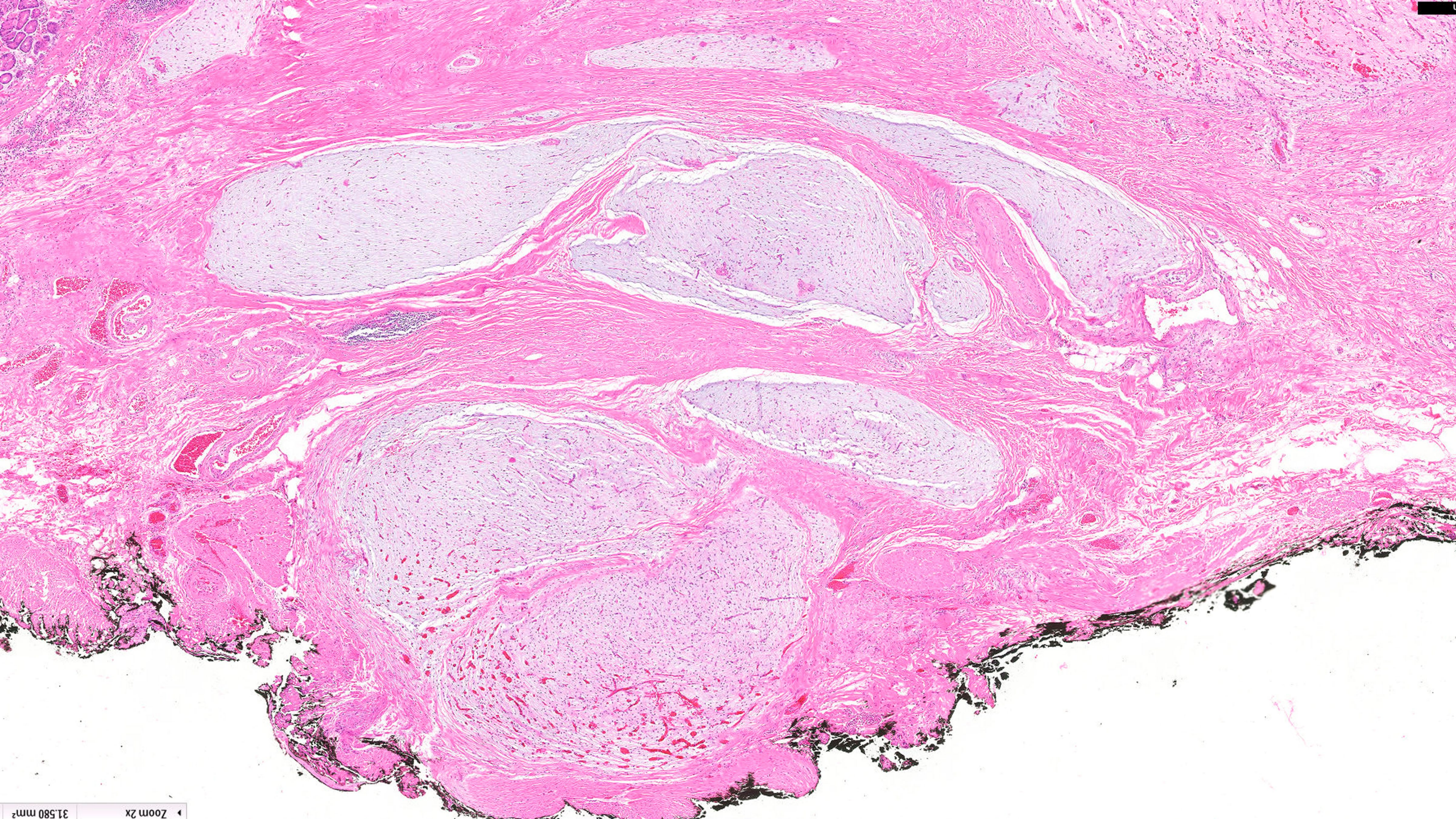
@HubertLauMD



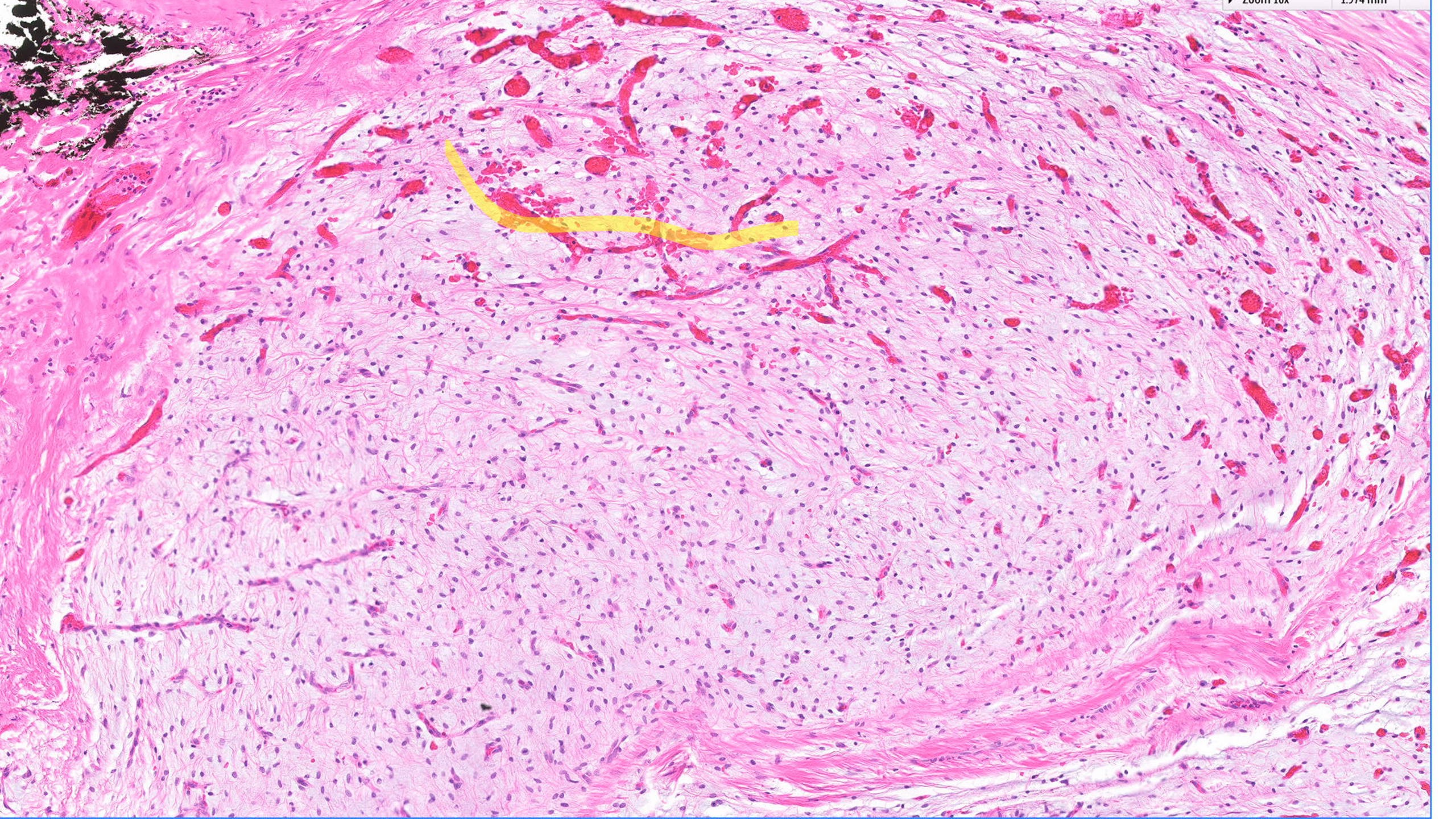


**Plexiform Fibromyxoma**

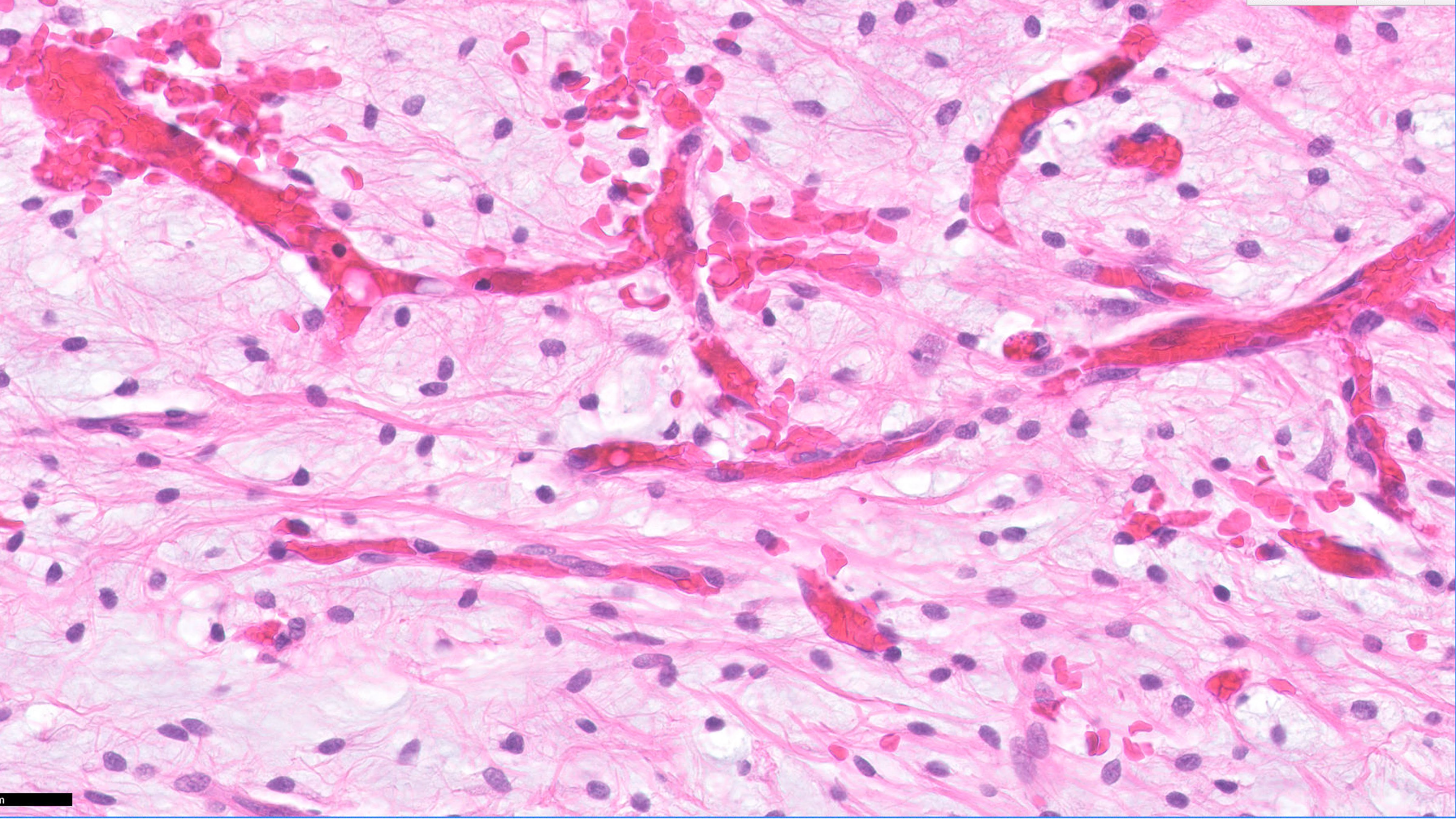











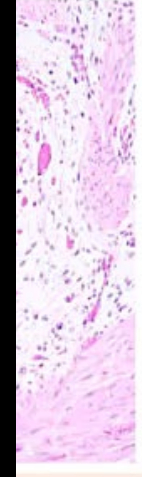




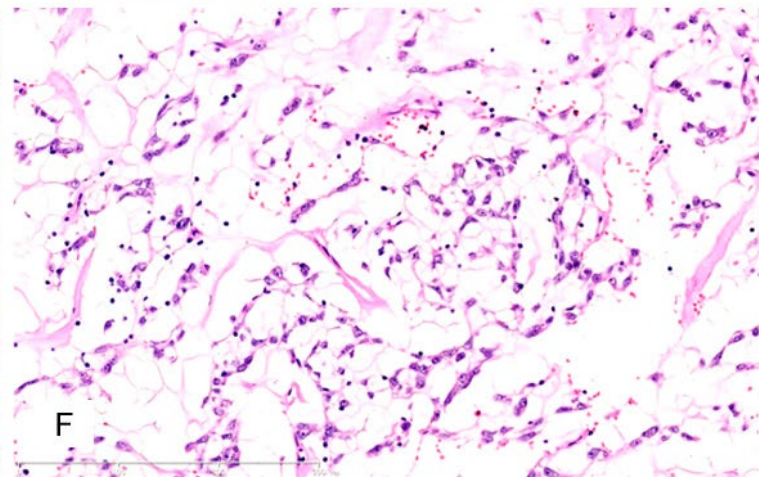
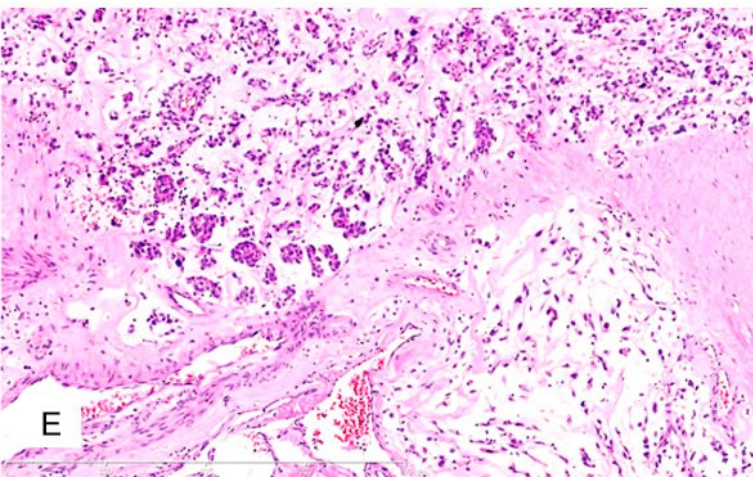
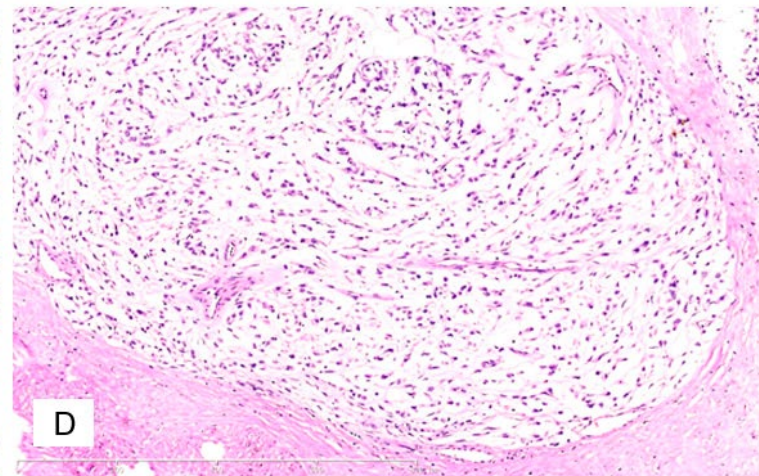
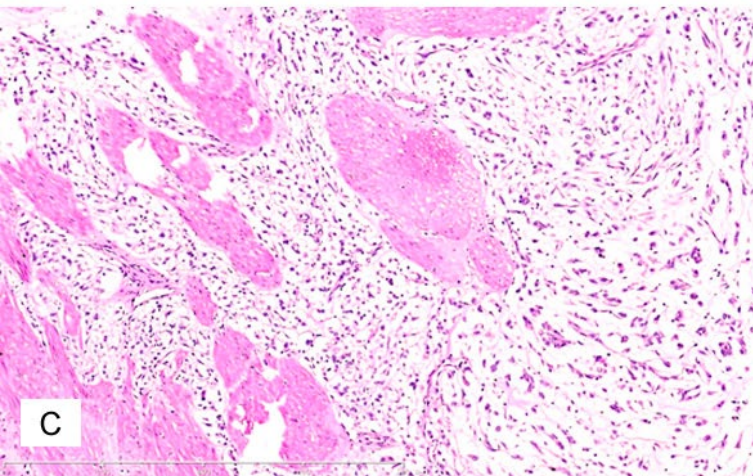
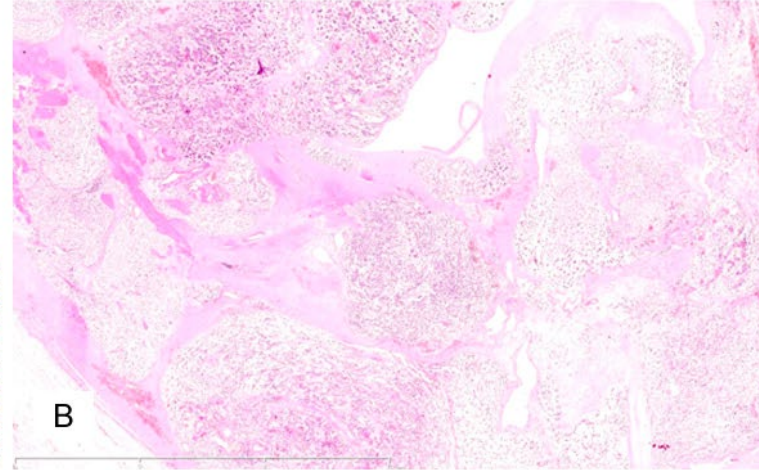
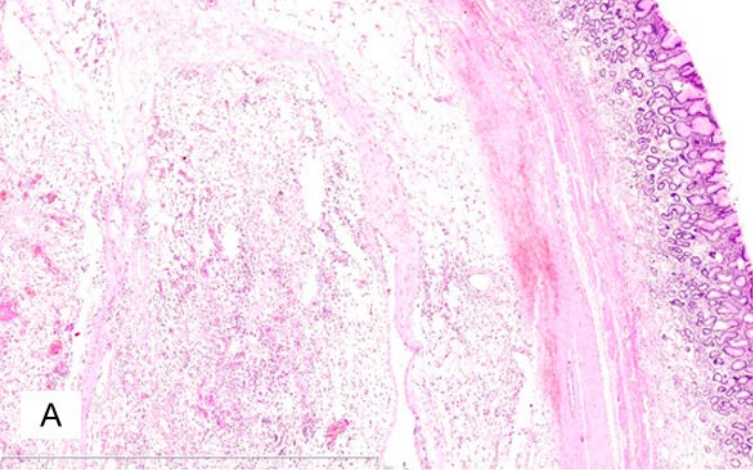
# GLI-1 FUNCTION



SMA







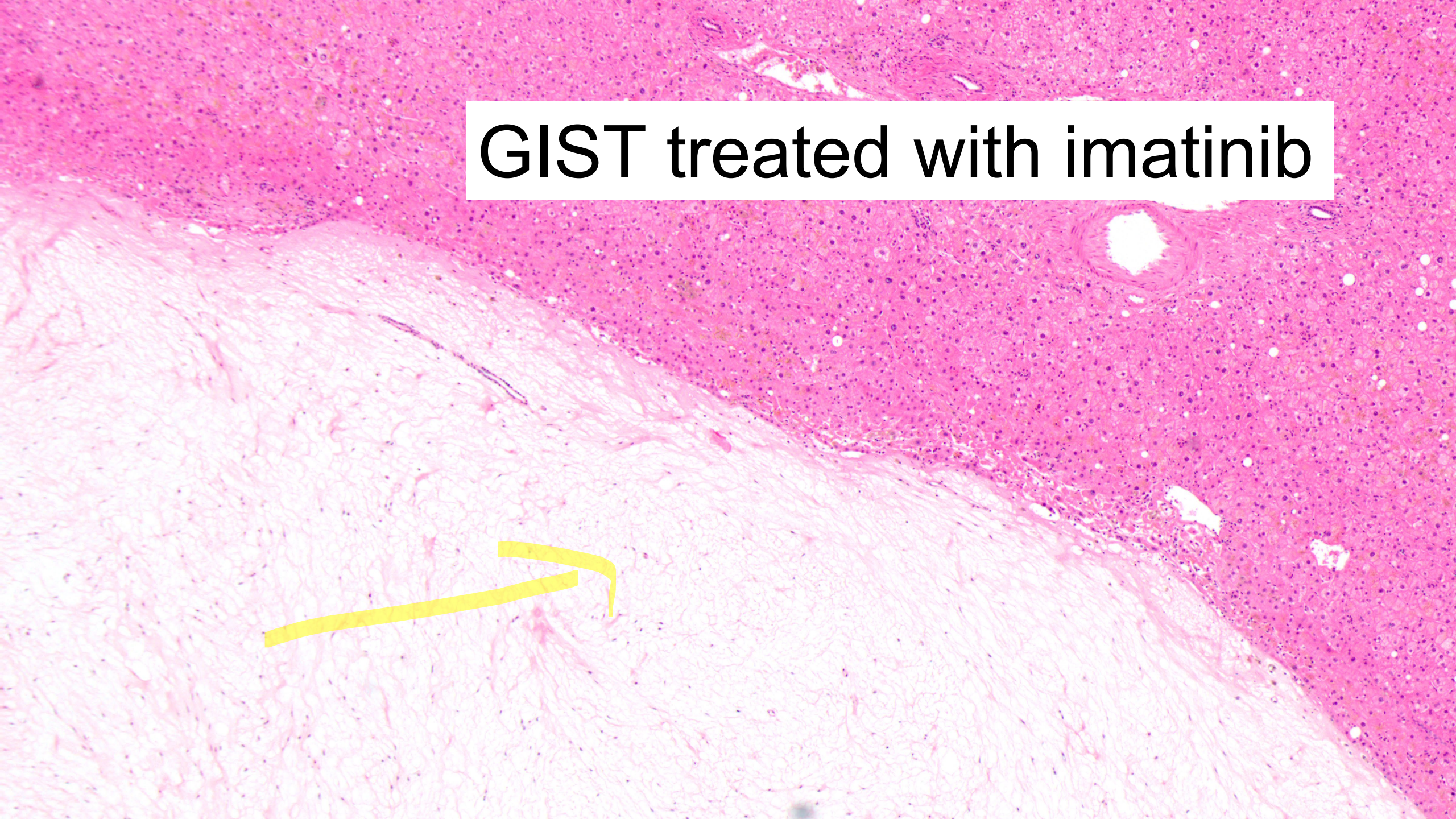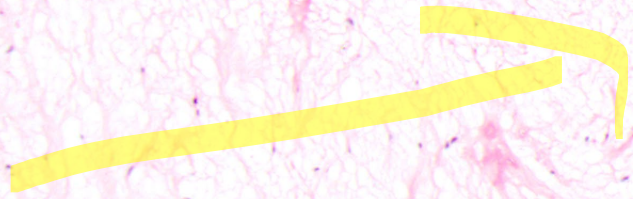
# Myxoid GIST



HARVARD  
MEDICAL SCHOOL



**GIST treated with imatinib**





# Plexiform Fibromyxoma

- 5<sup>th</sup> decade
- Benign tumor almost always arises in stomach (antrum)
- Complete excision is curative
- Vascular invasion is often present and has no apparent significance
- *MALAT1-GLI1* fusions and *GLI1* polysomy

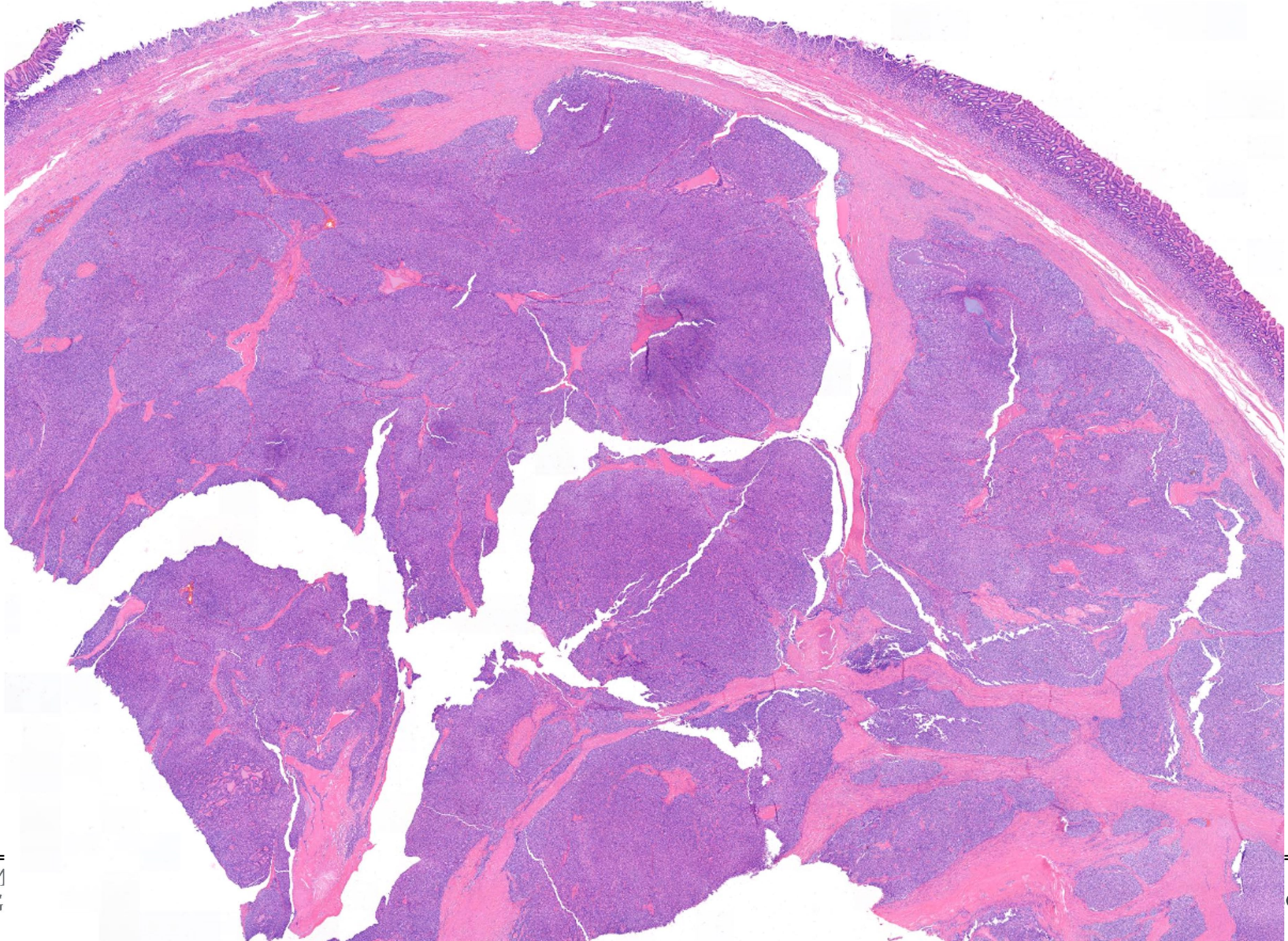


# Gastroblastoma

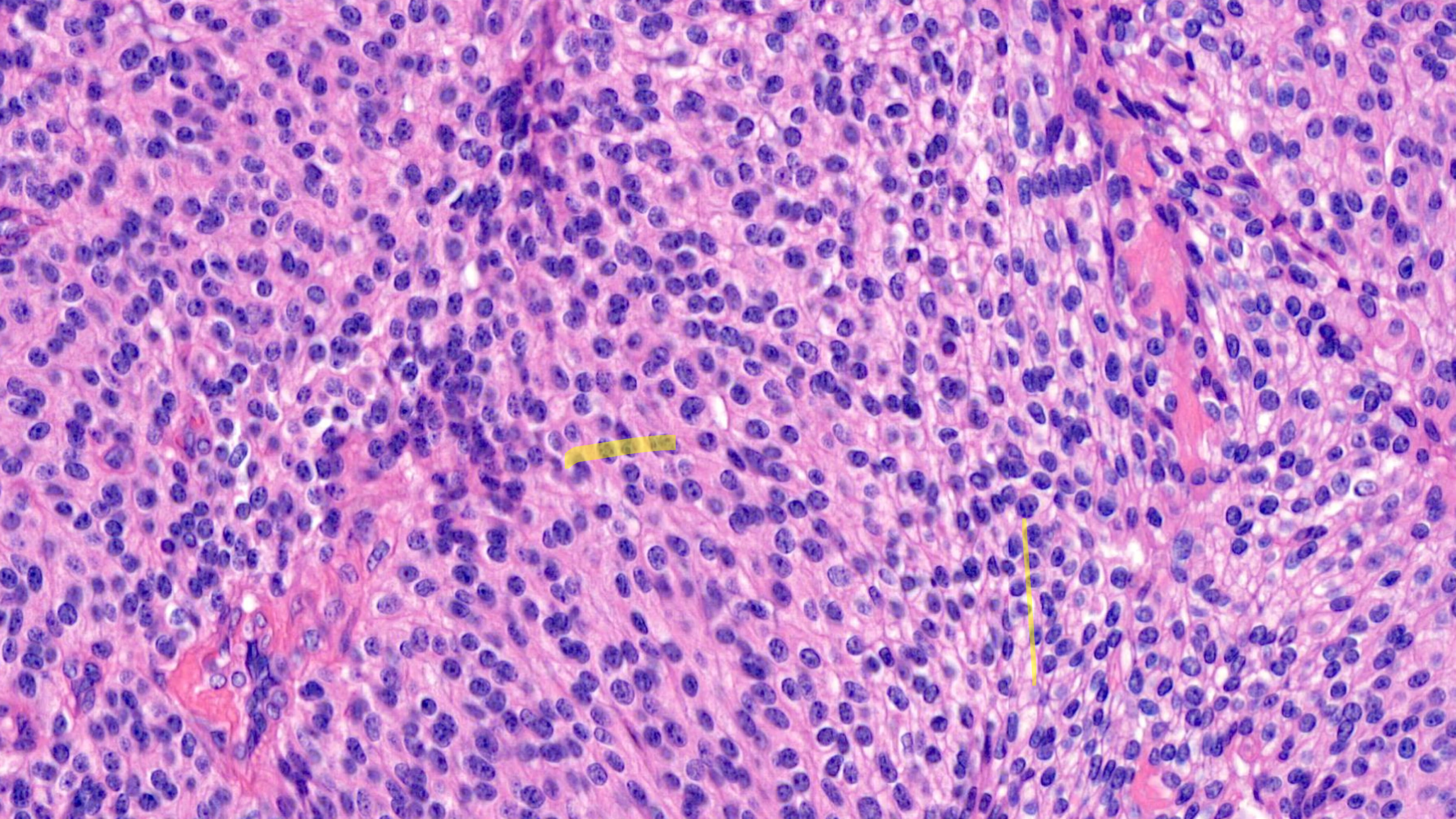
*MALAT1-GLI1*



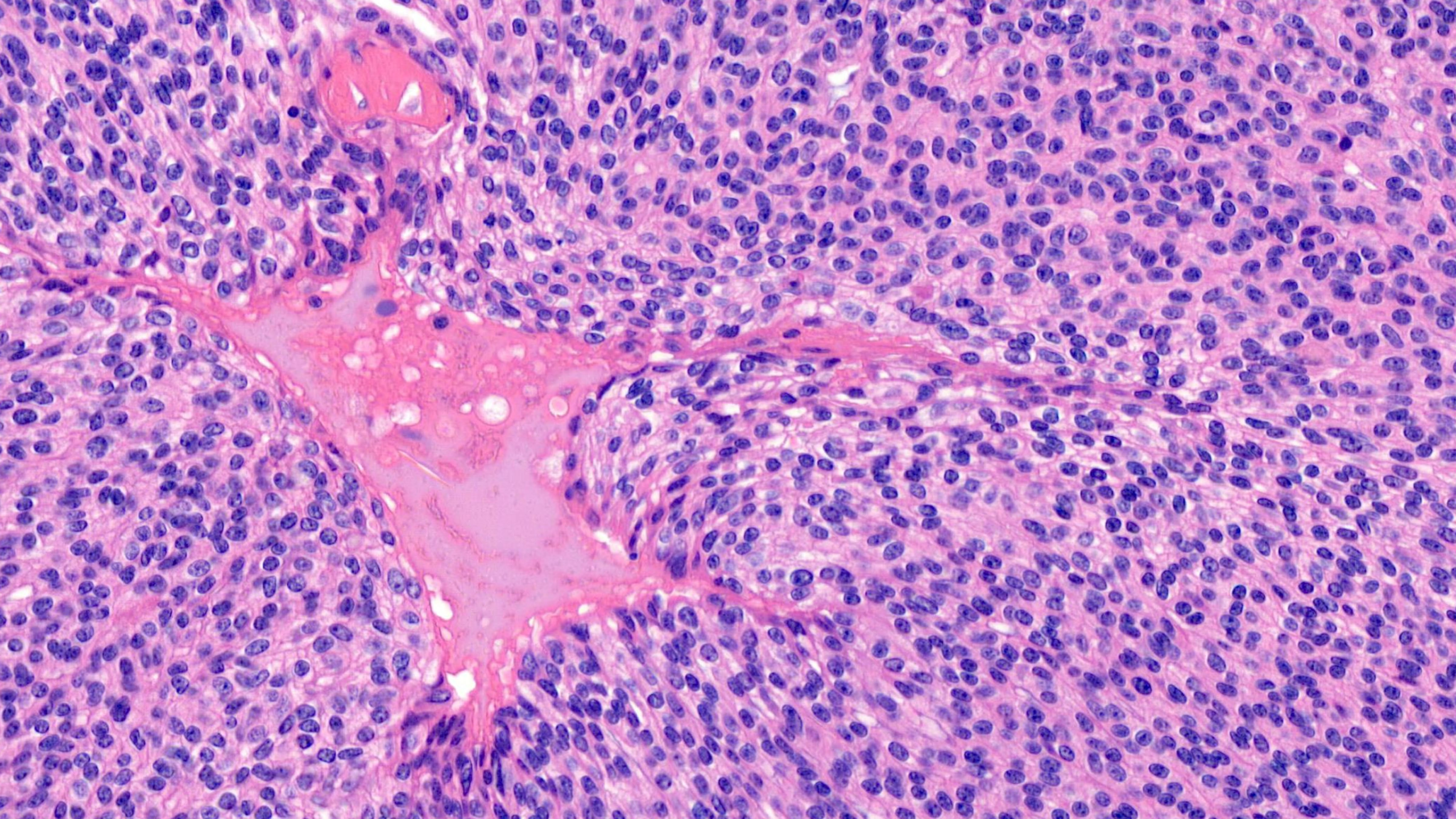






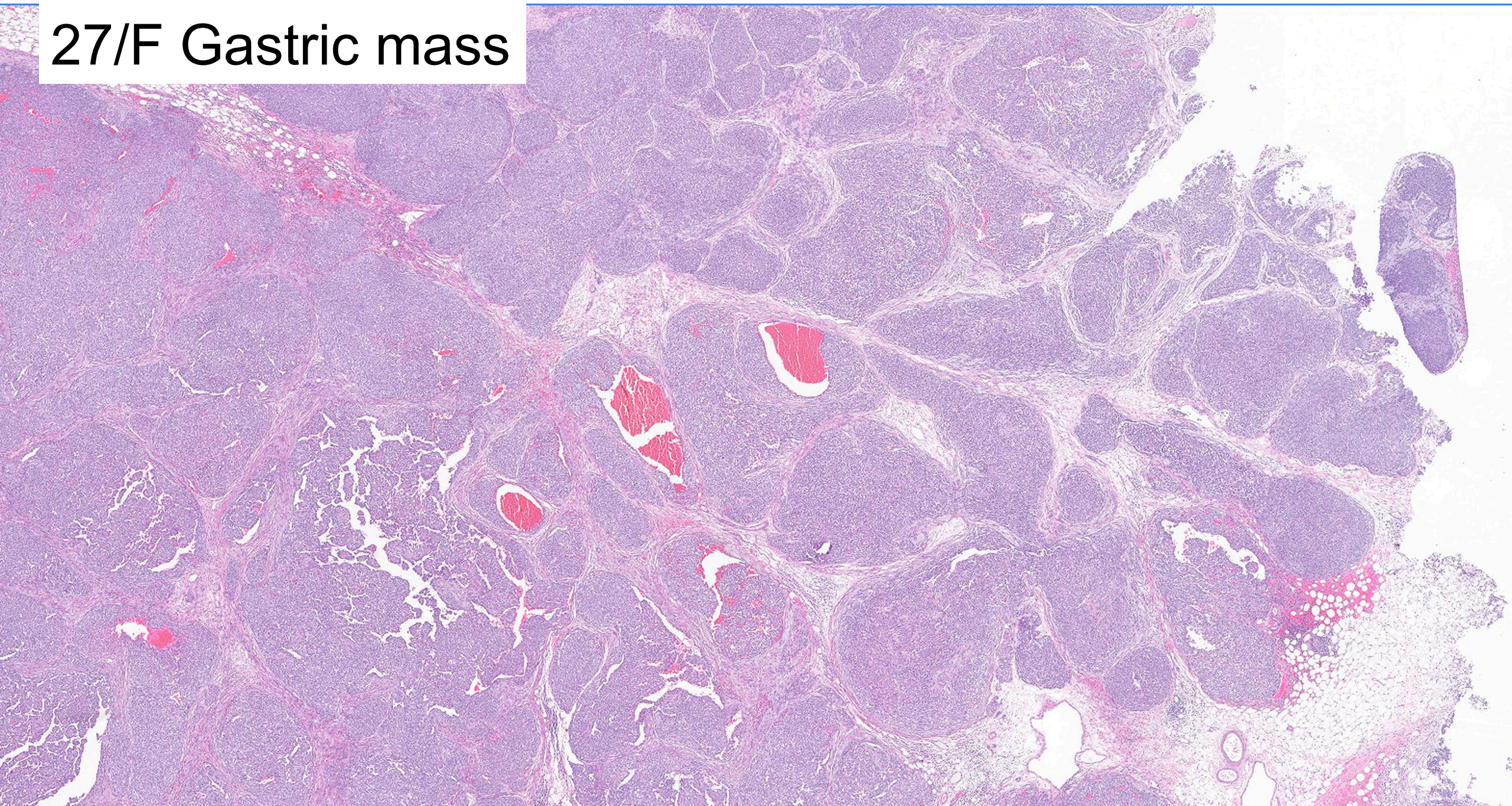




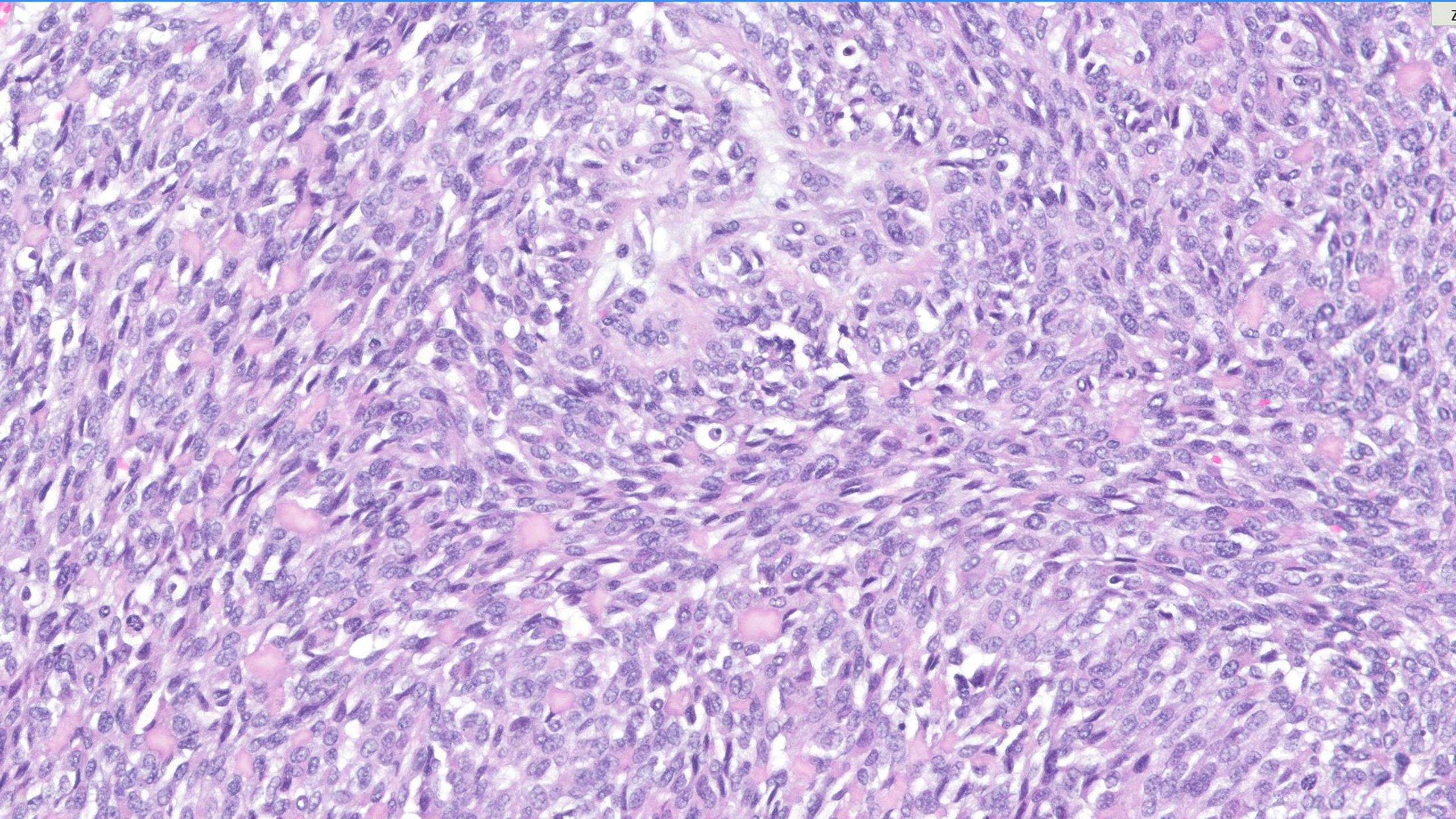




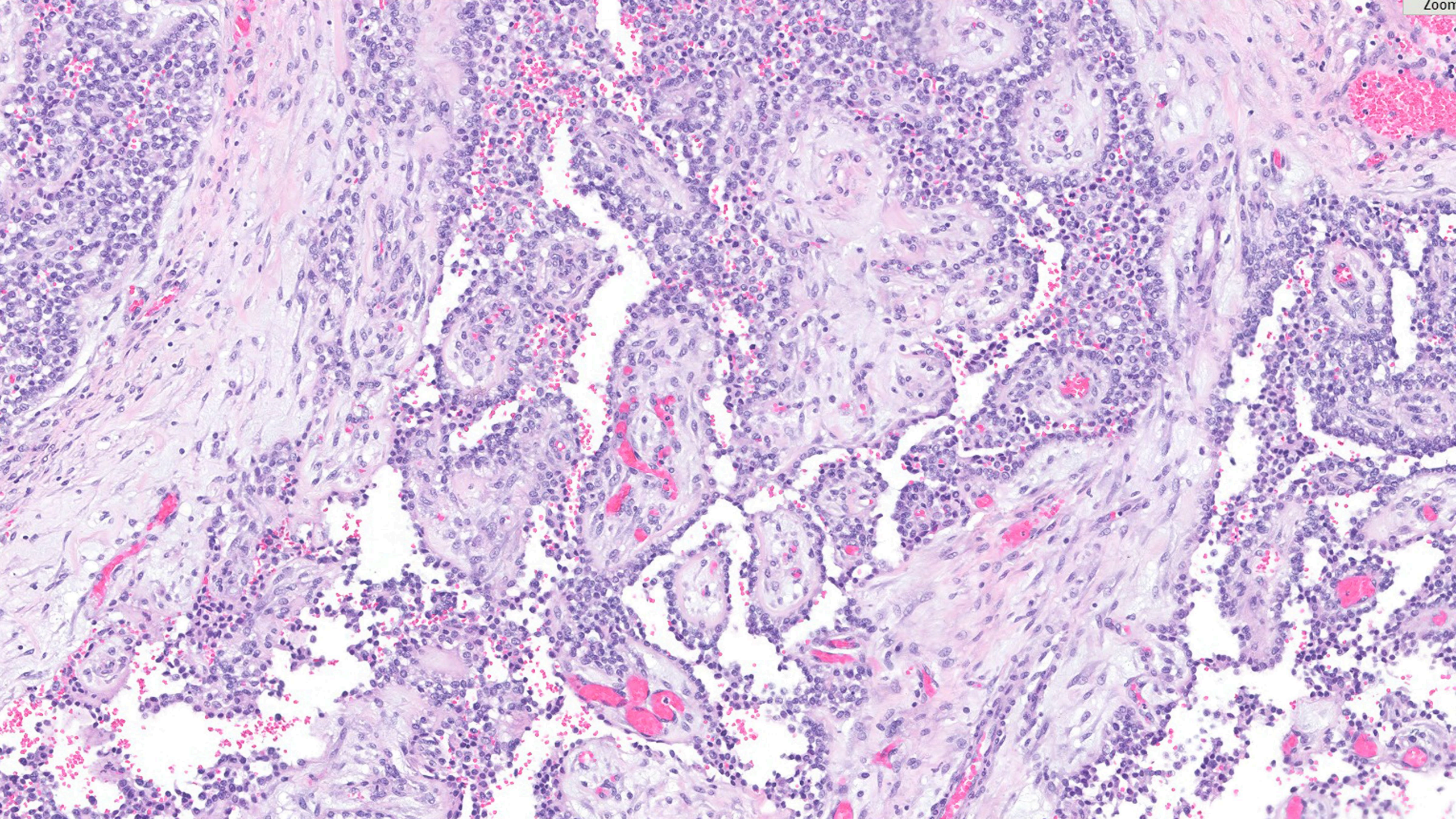
27/F Gastric mass



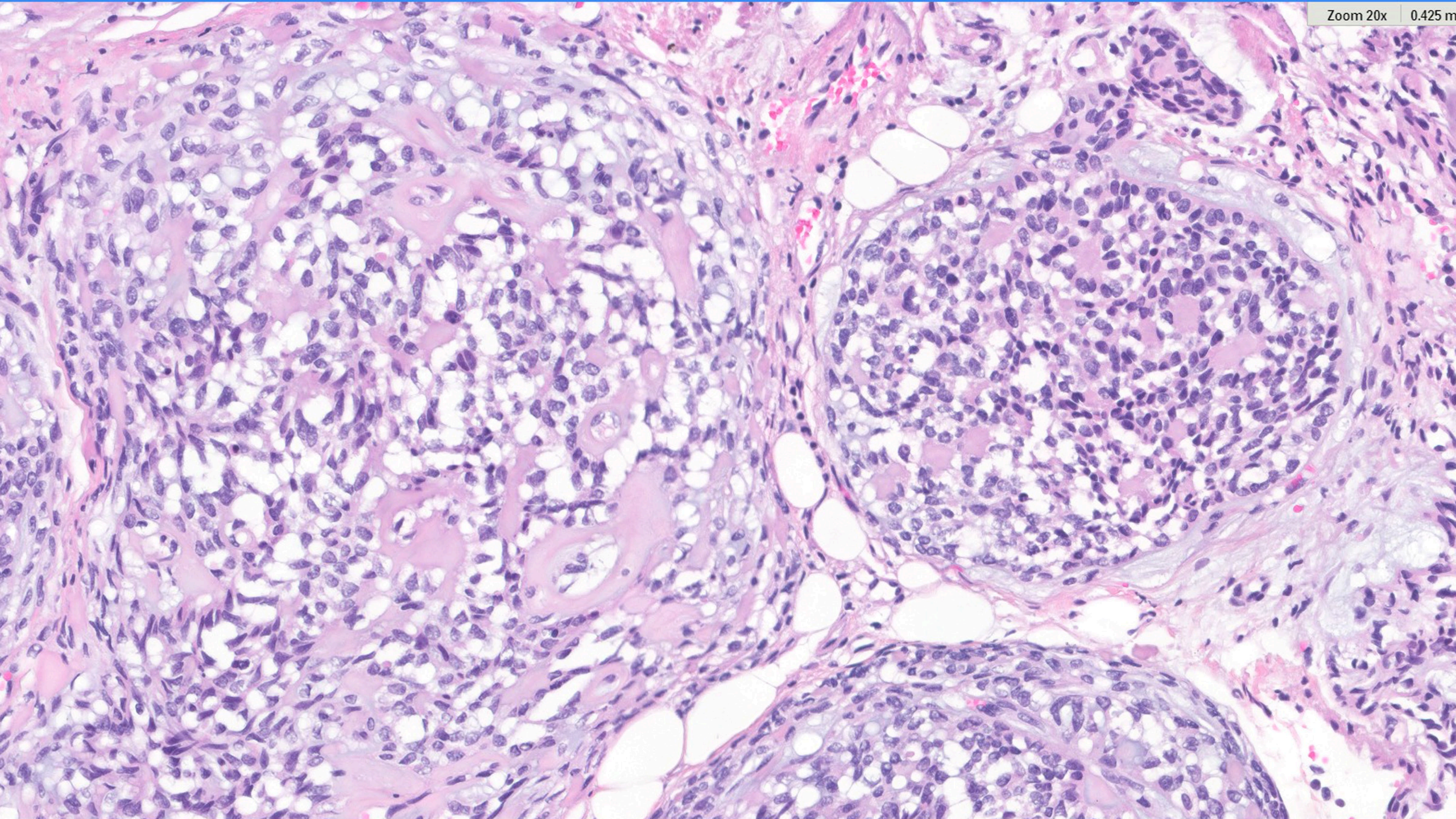




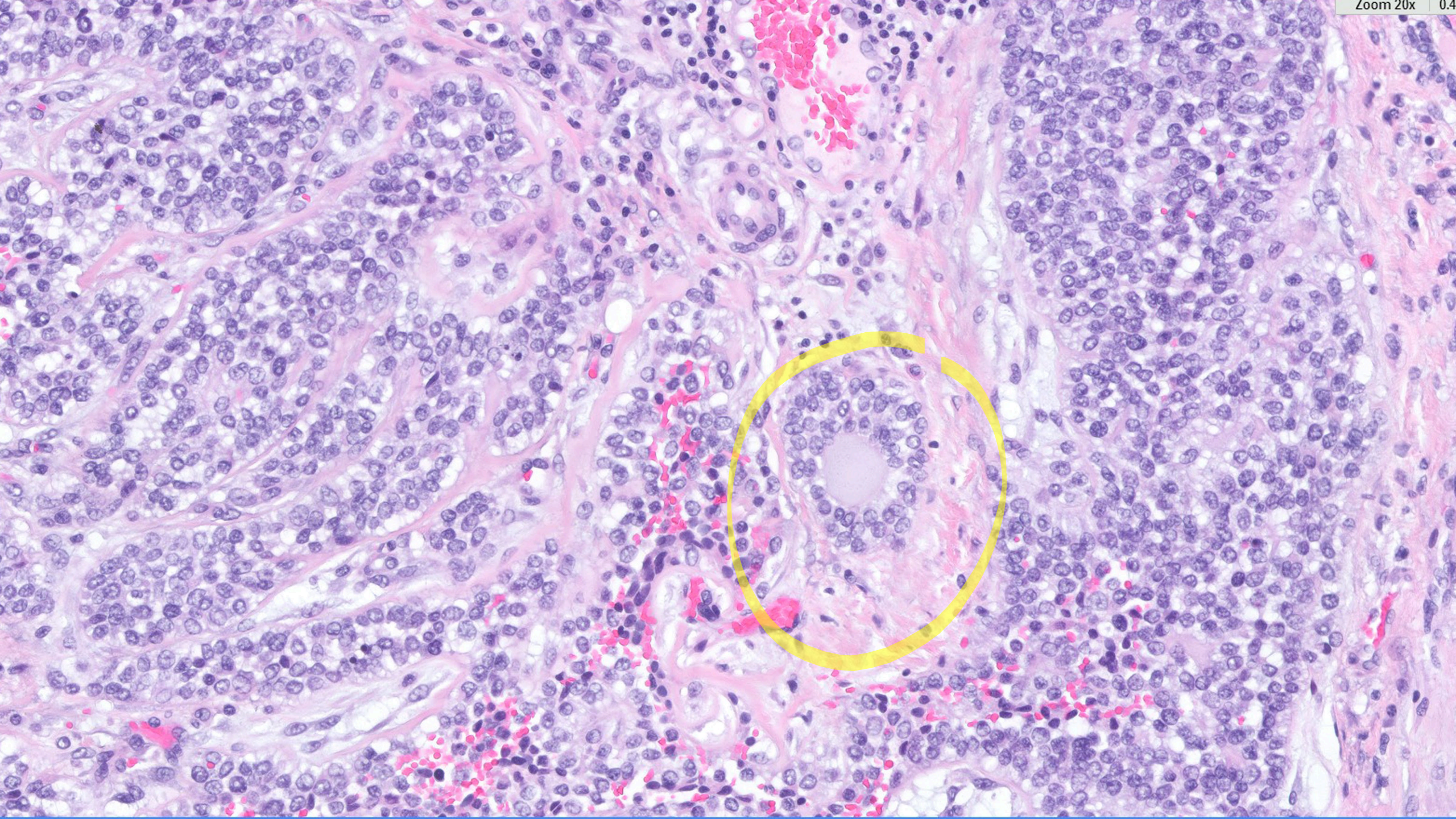




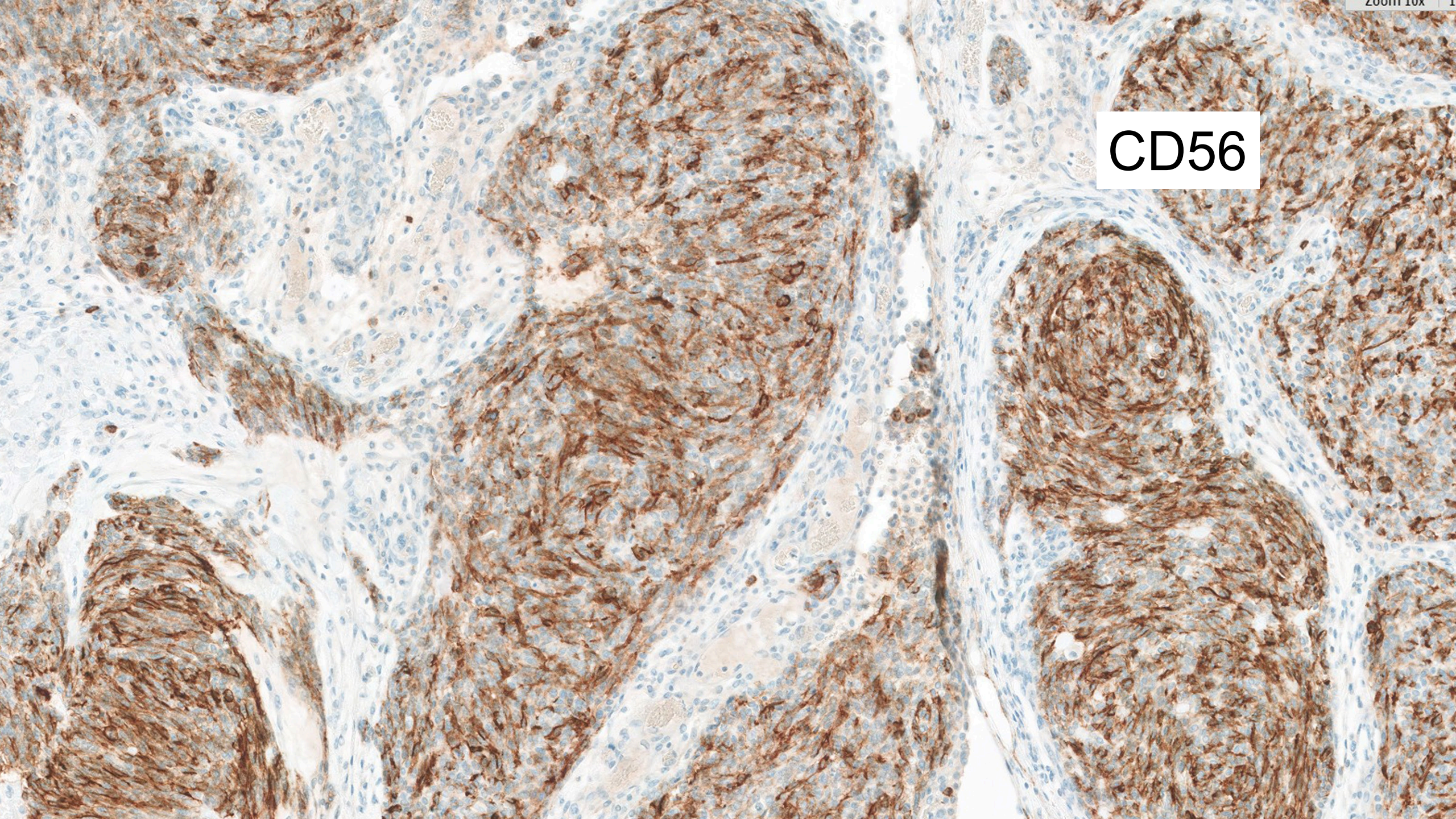








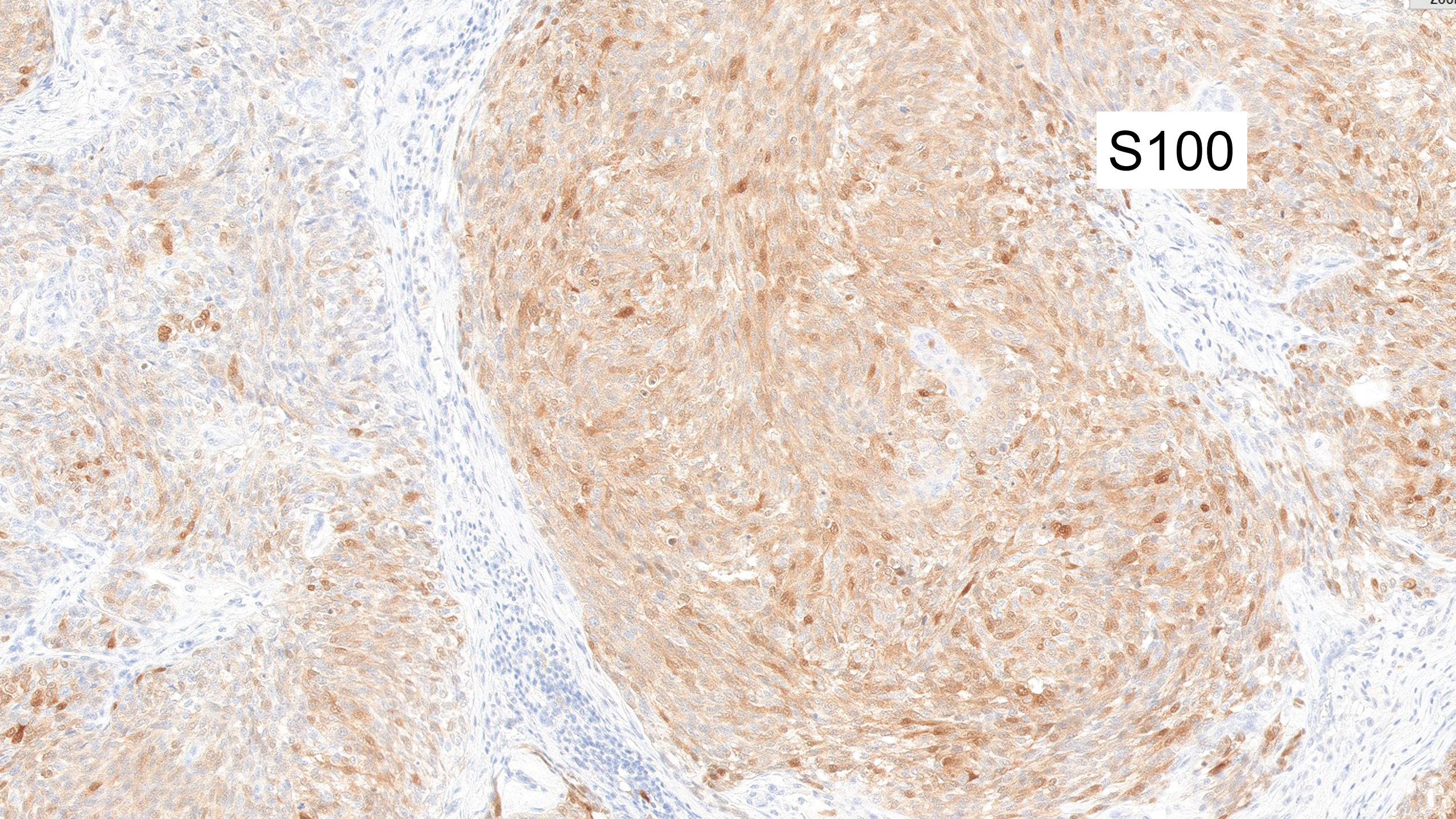




CD56

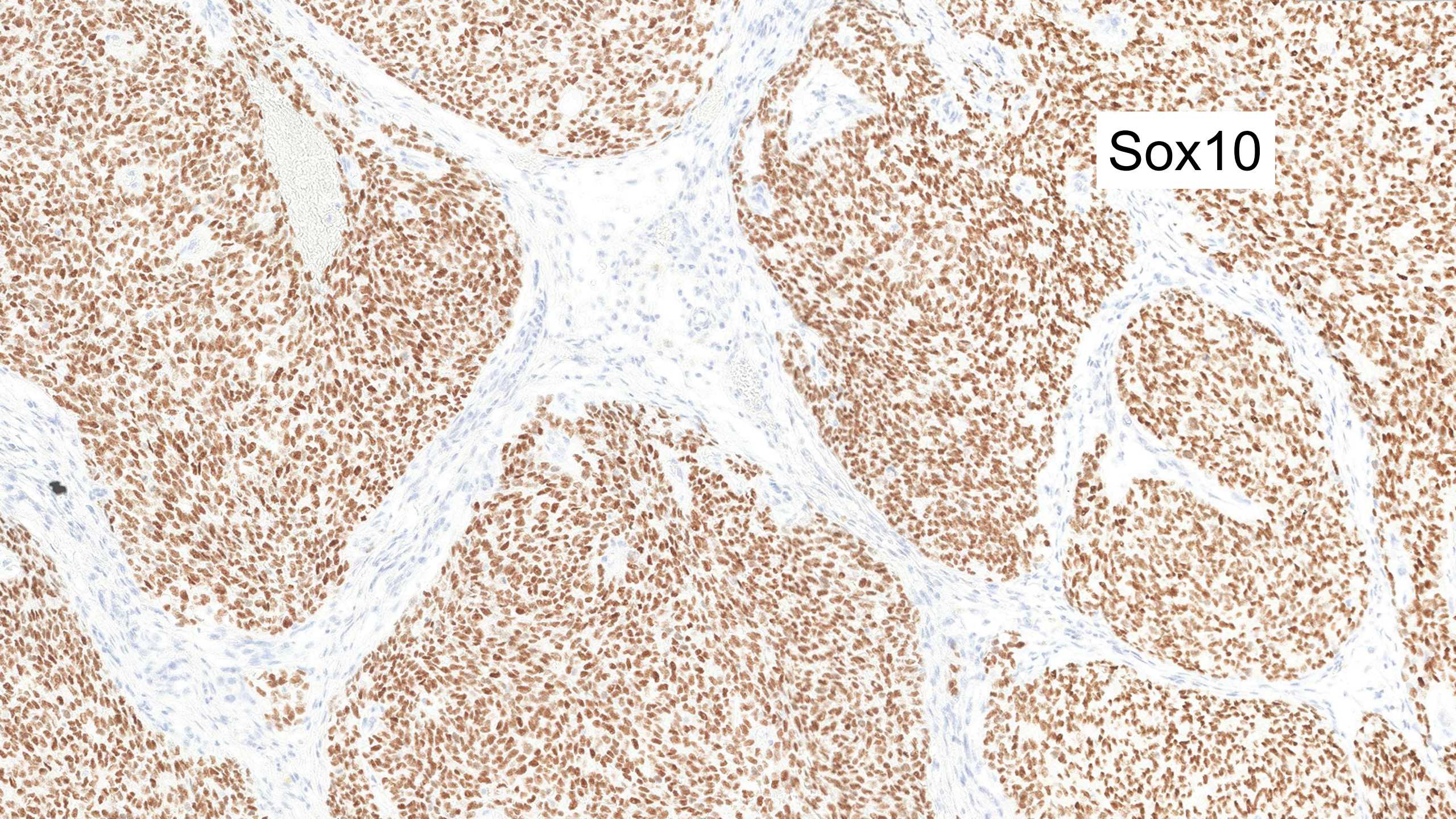


S100





Sox10





# **EWSR1-ATF1**

## **GI tract Clear Cell Sarcoma**

**Malignant Gastrointestinal neuroectodermal tumor**





# GI Clear Cell Sarcoma

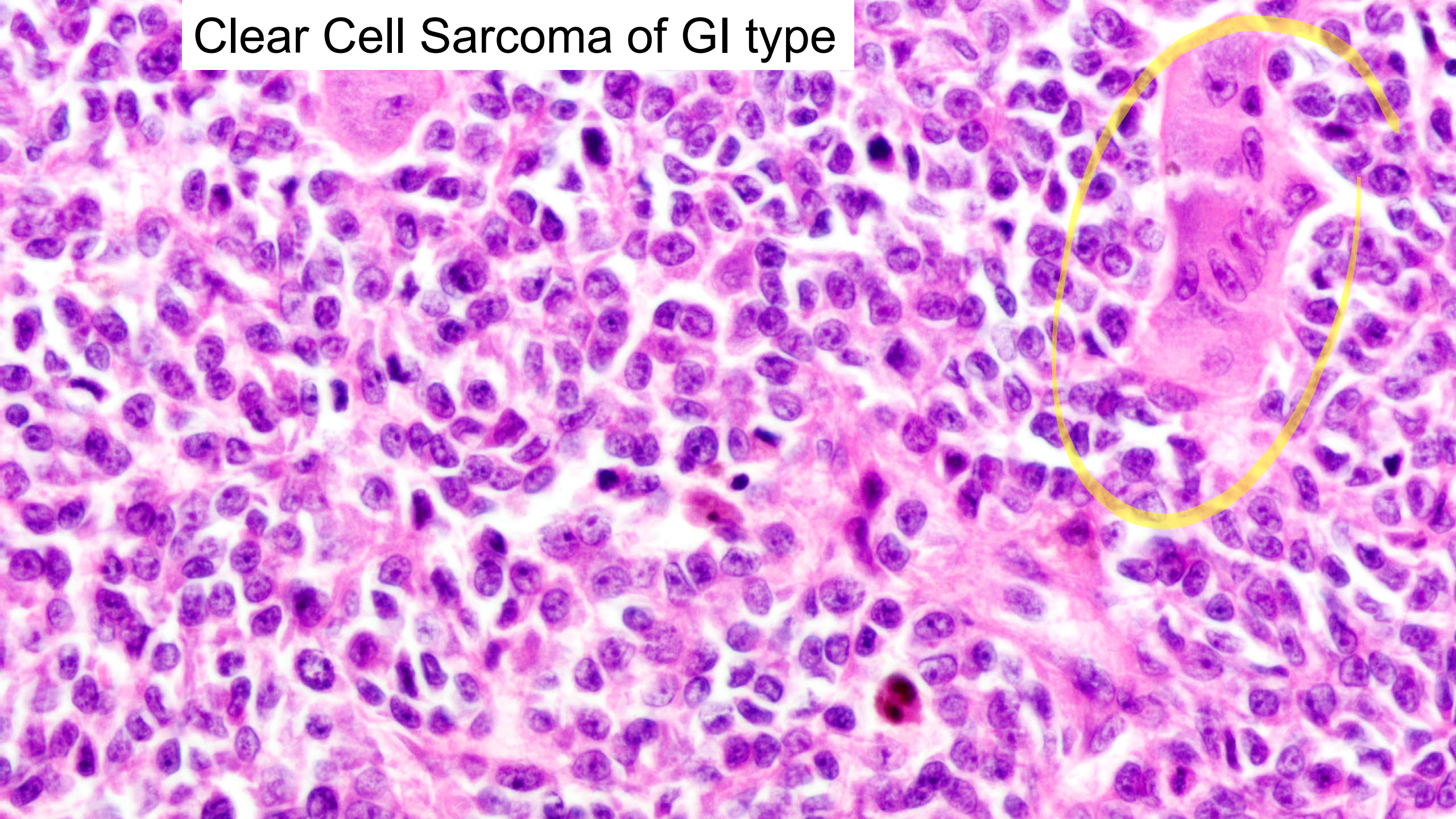


A high-magnification histological slide showing a dense population of cells with clear cytoplasm and hyperchromatic nuclei, characteristic of GI Clear Cell Sarcoma. The cells are arranged in a disorganized pattern with some mitotic figures. A yellow curved line highlights a specific area of the tissue.

**Keratin negative  
S100 positive**

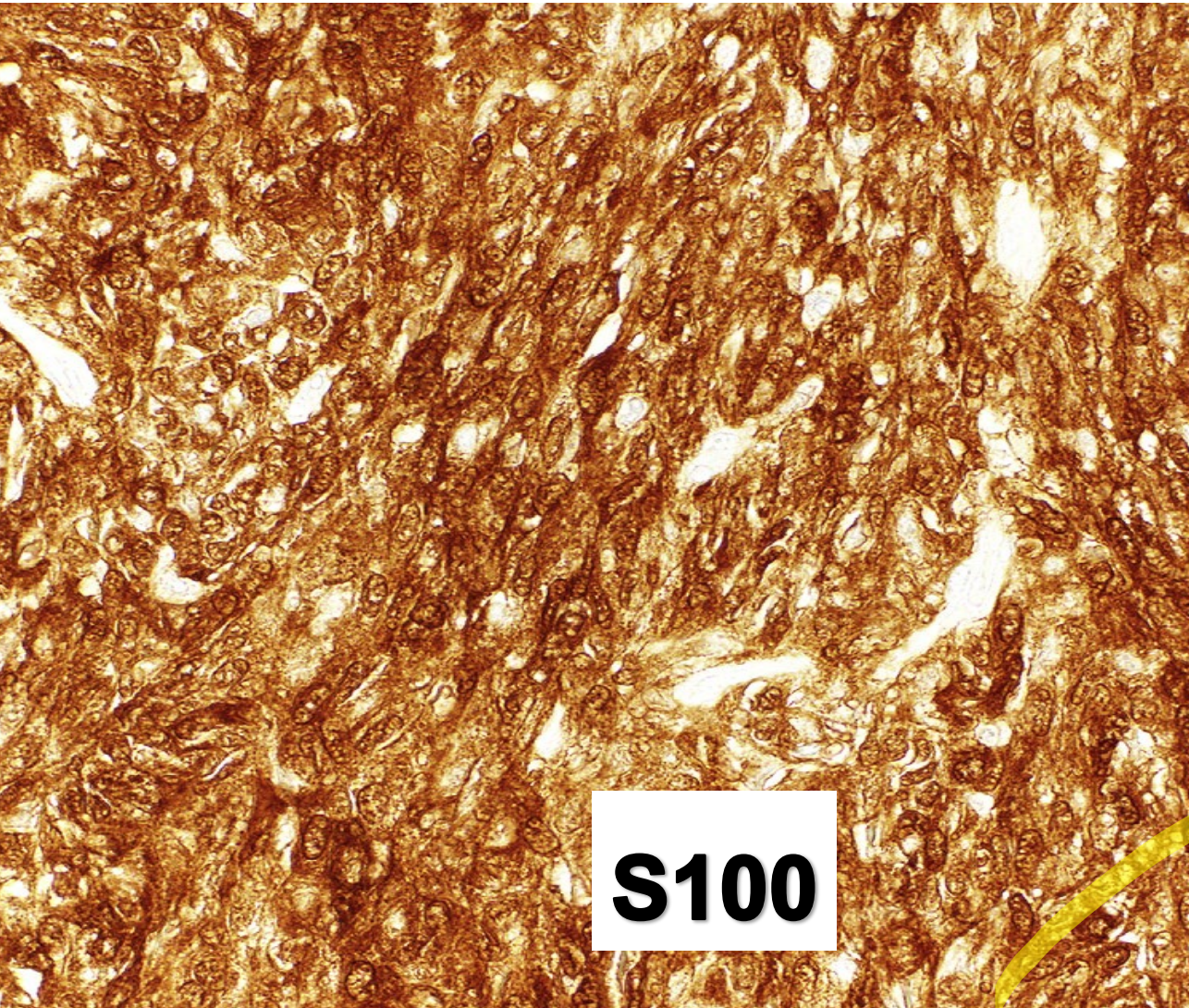


# Clear Cell Sarcoma of GI type





# GI Clear Cell Sarcoma

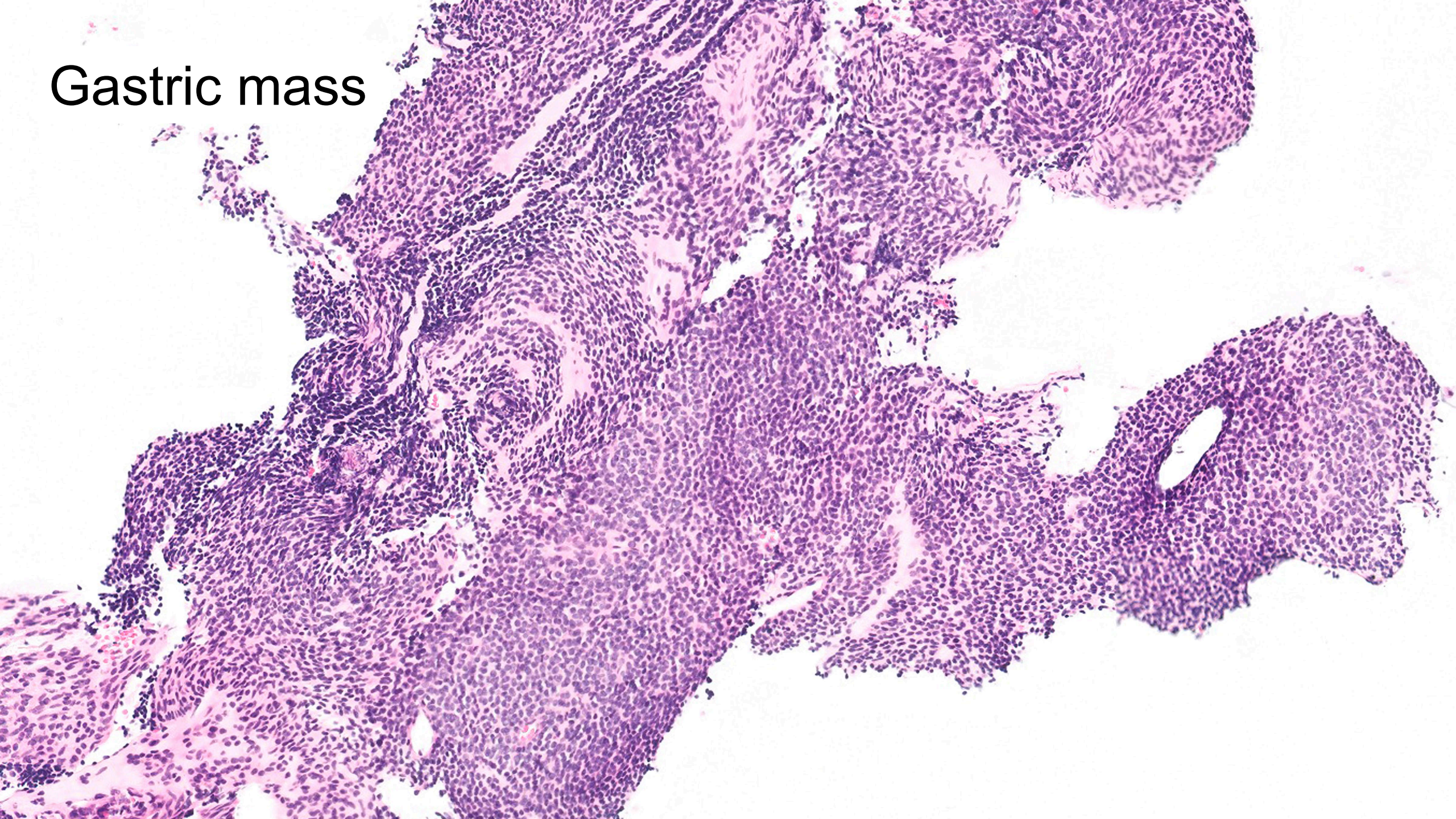


## Immunohistochemistry

- Positive
  - S100
- Negative
  - HMB-45, Mart-1, MiTF
- EWSR1-ATF1 or
- EWSR1-CREB1 fusion
- Aggressive clinical course



Gastric mass

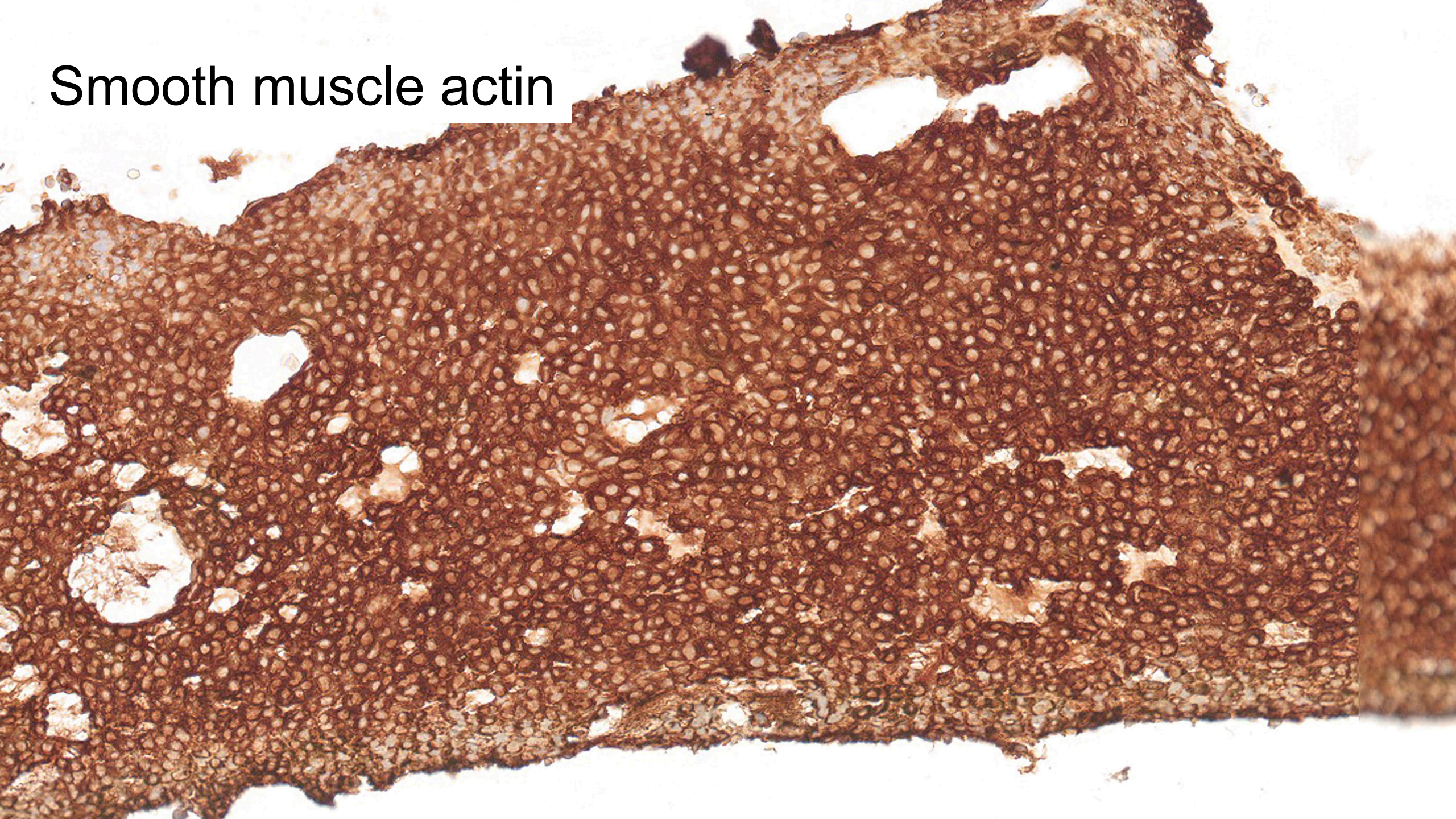





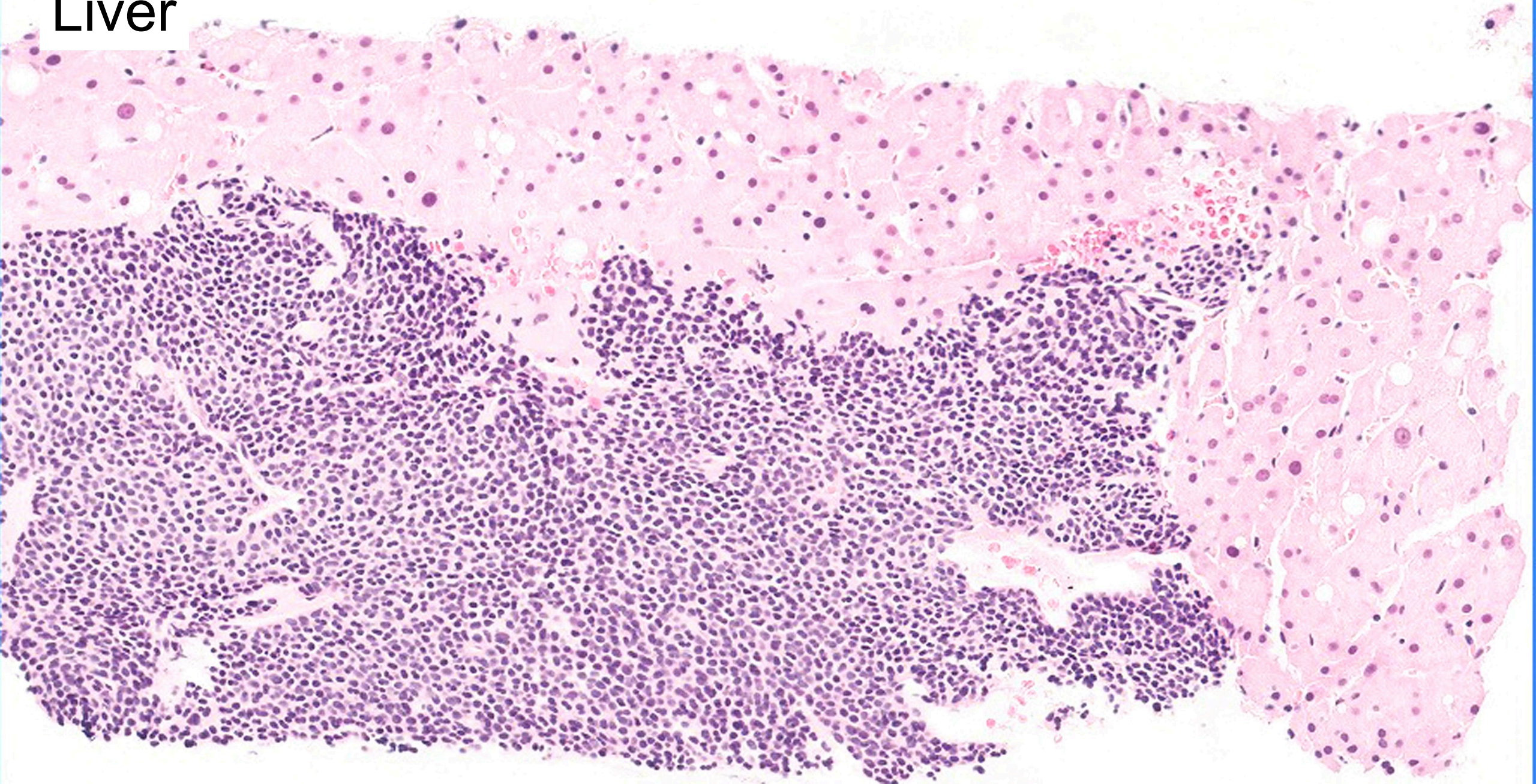


Smooth muscle actin

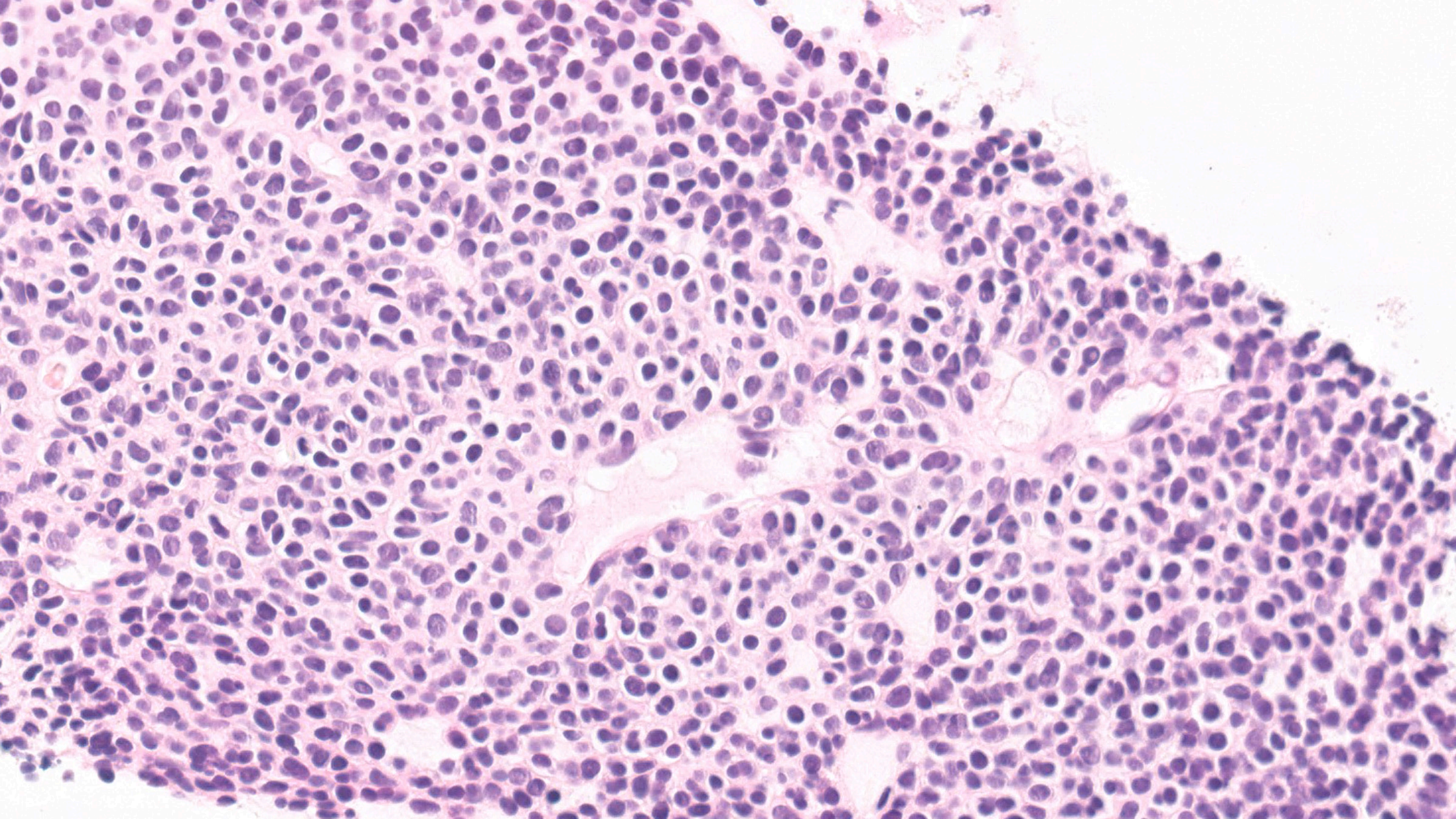




Liver











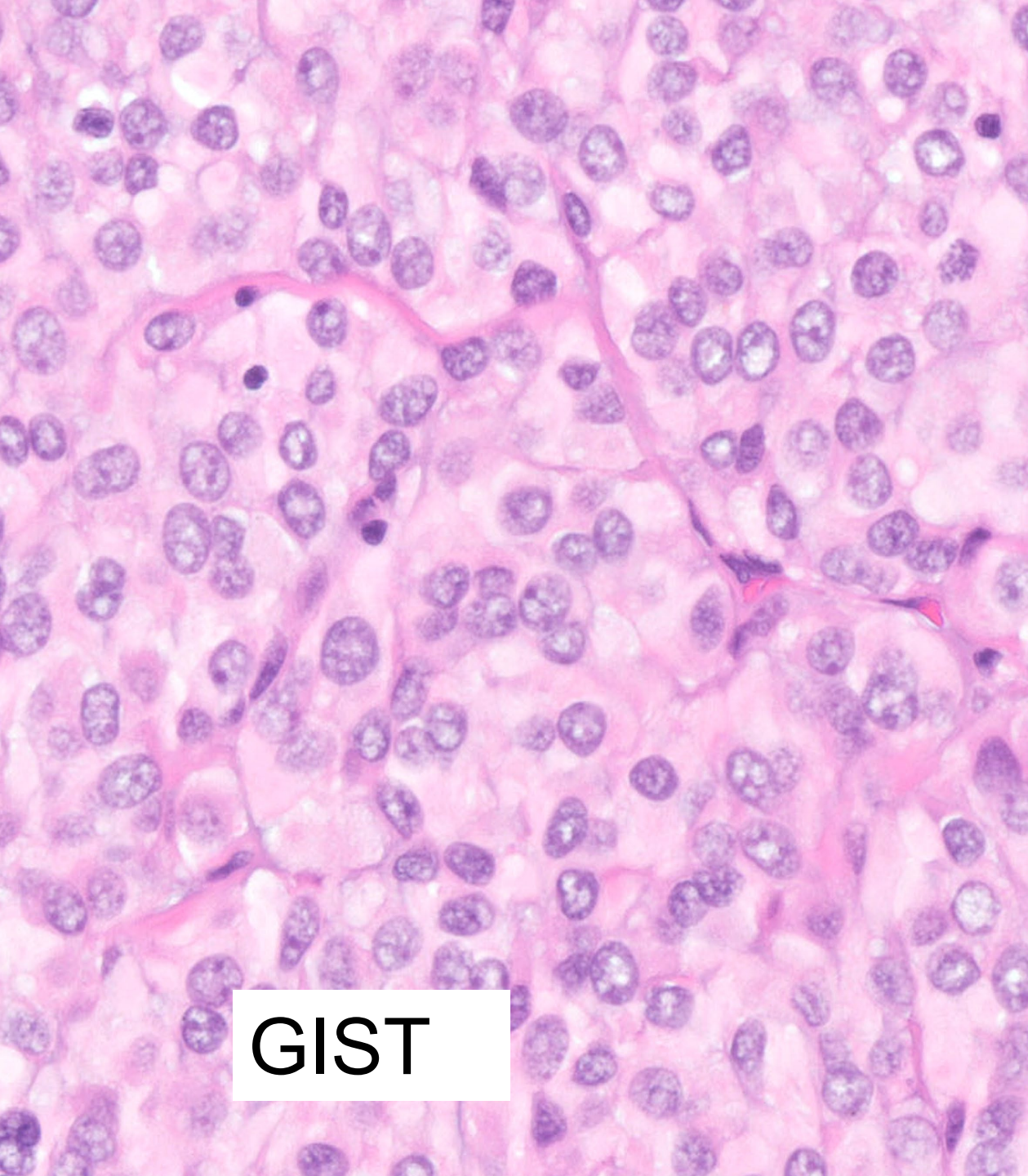


# Malignant Glomus

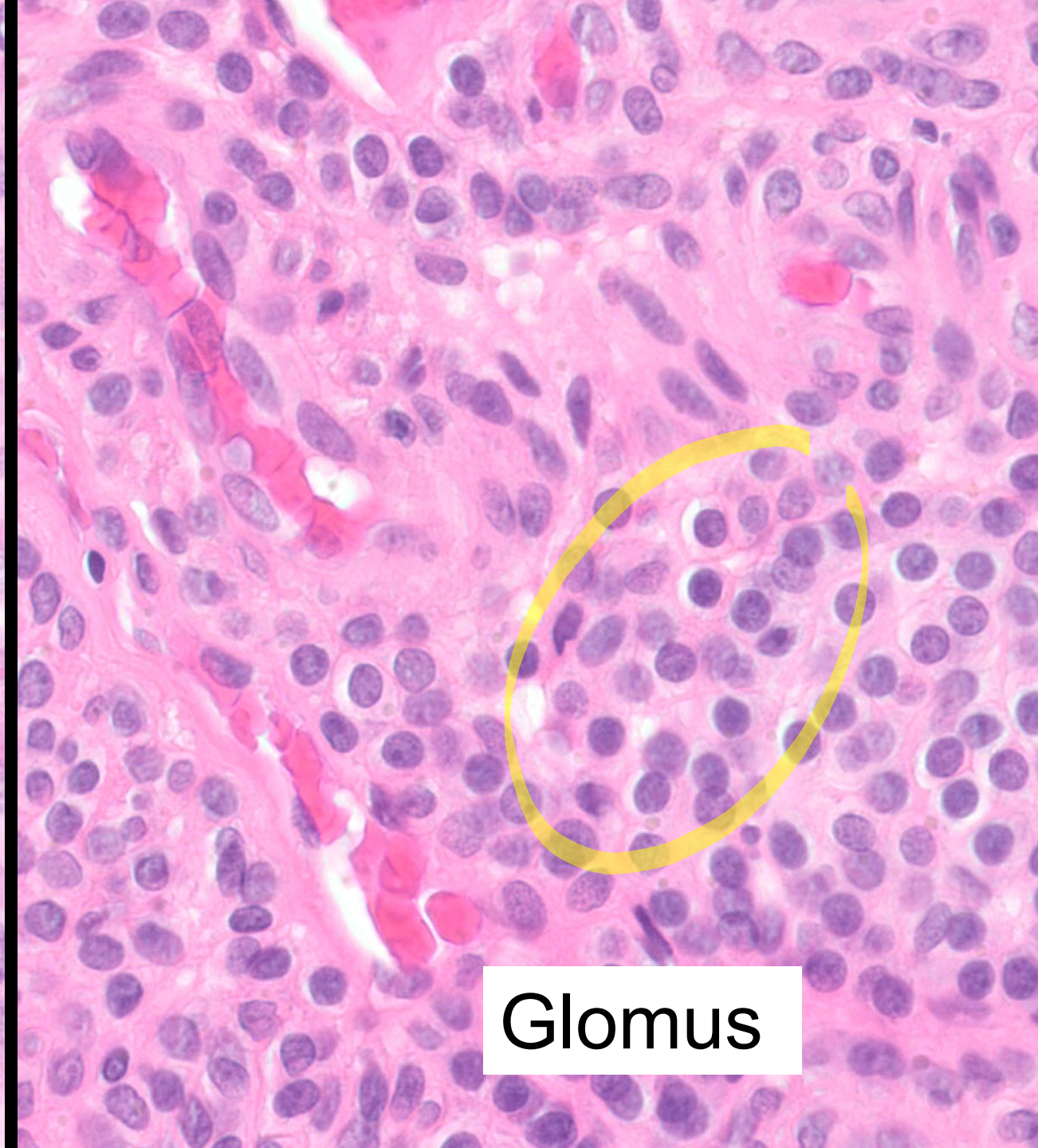
- Marked nuclear atypia (with any level of mitotic activity) or atypical mitotic figures
- An infiltrative growth pattern, high cellularity, and spindled morphology are also features significantly more common in malignant glomus tumors







GIST



Glomus



# Deep leiomyomas (muscularis propria)

In order of frequency

Esophagus

Stomach

Small intestine

Colon

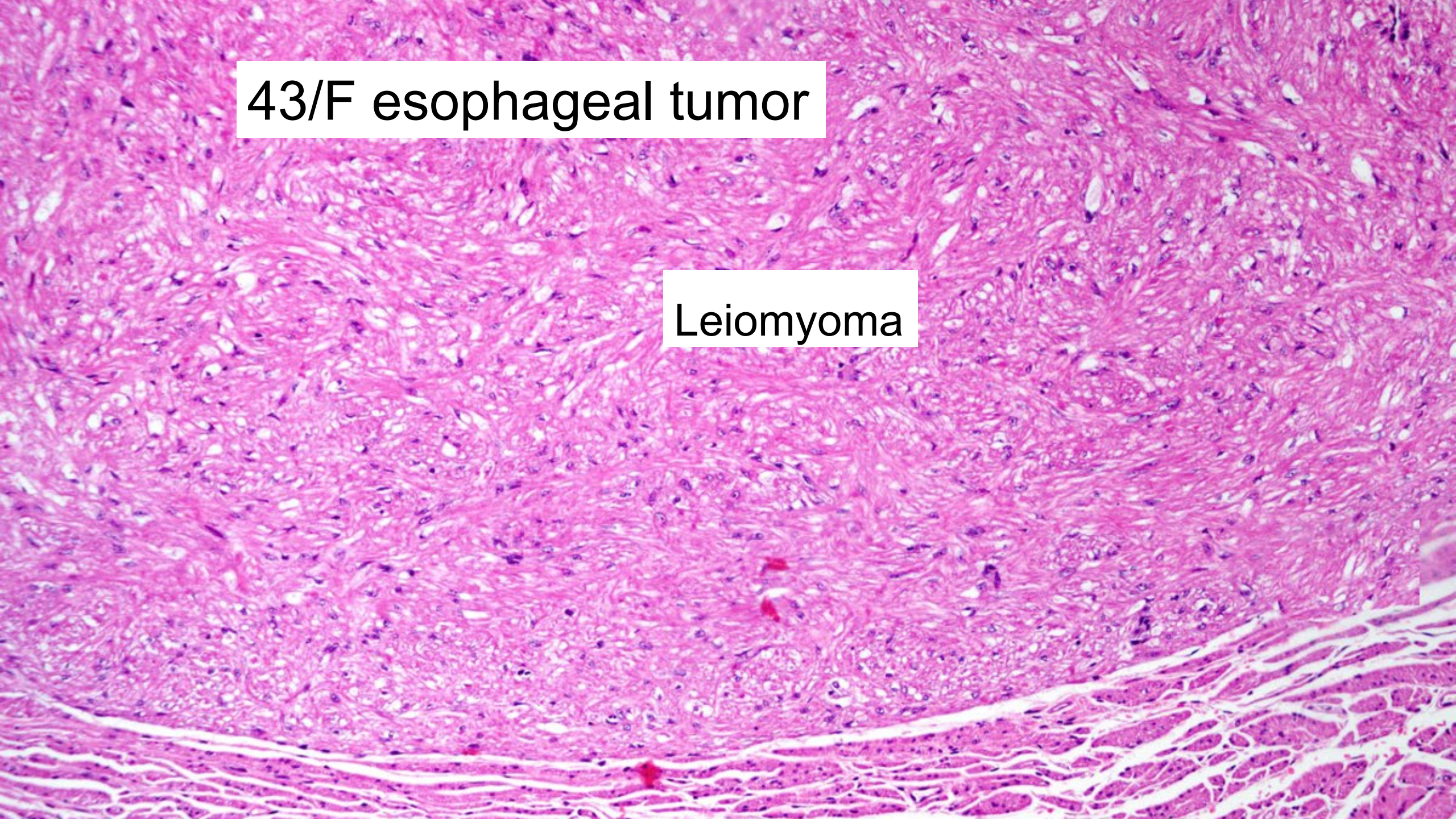
# **muscularis propria**



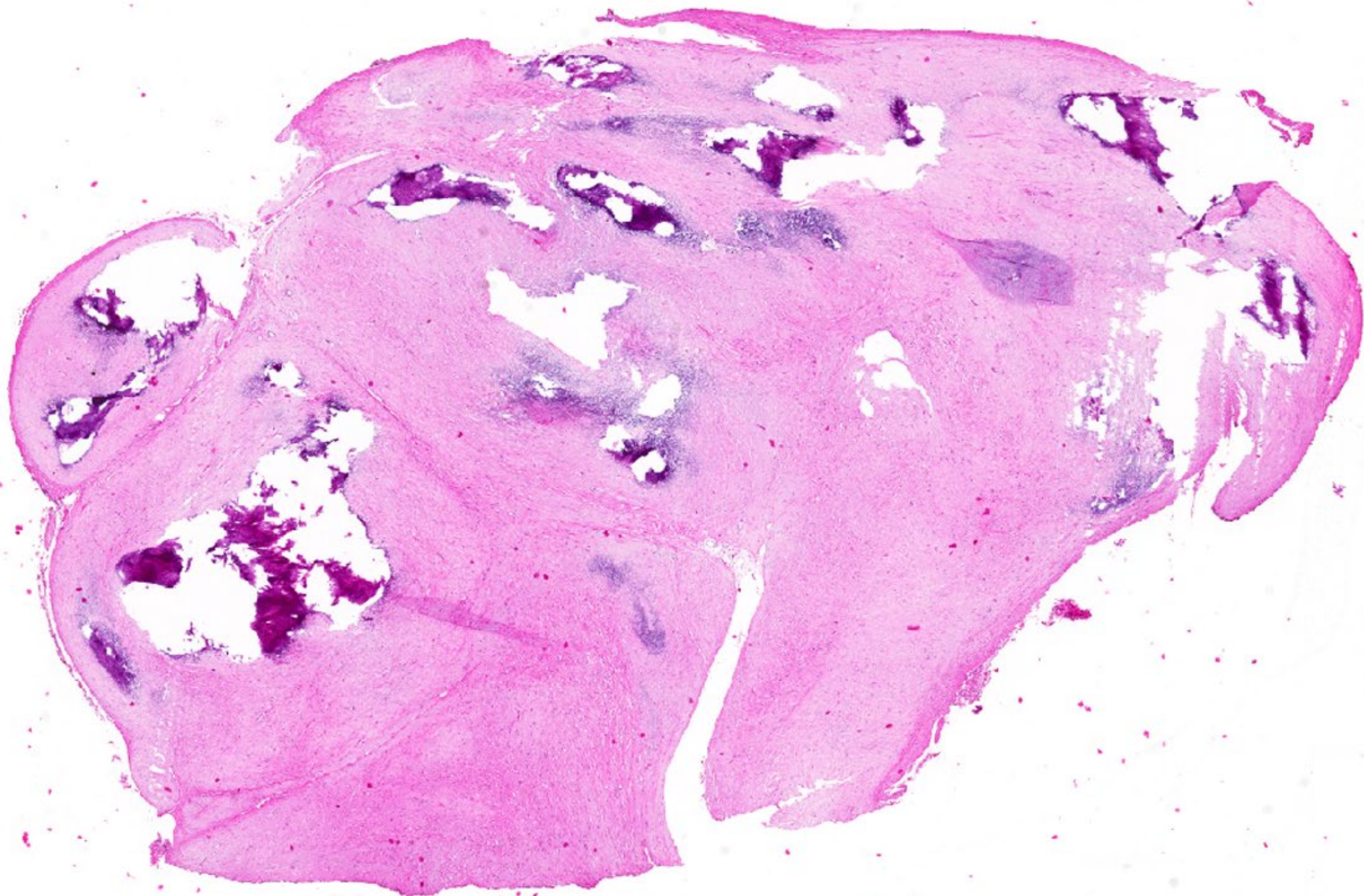


43/F esophageal tumor

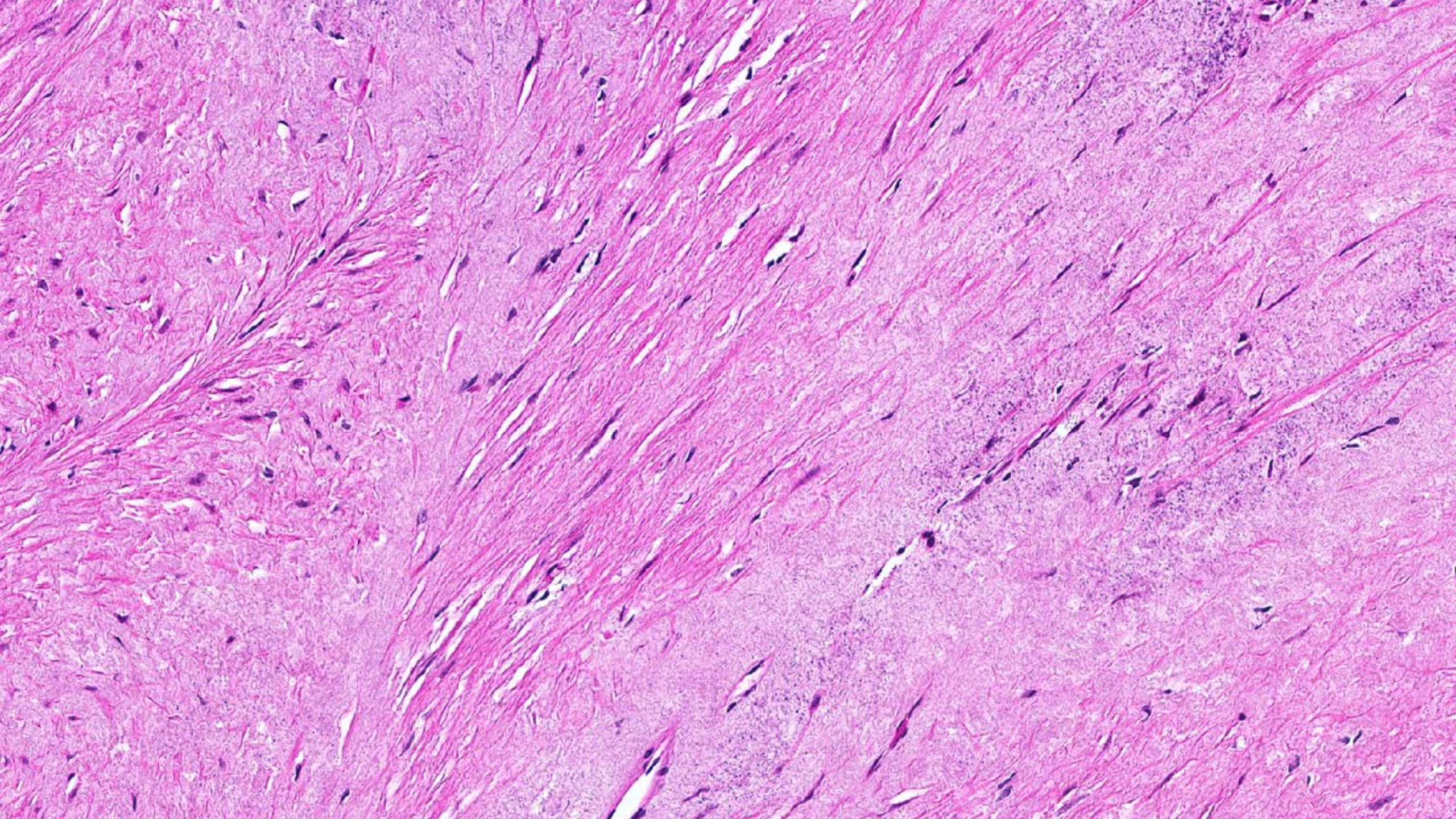
Leiomyoma





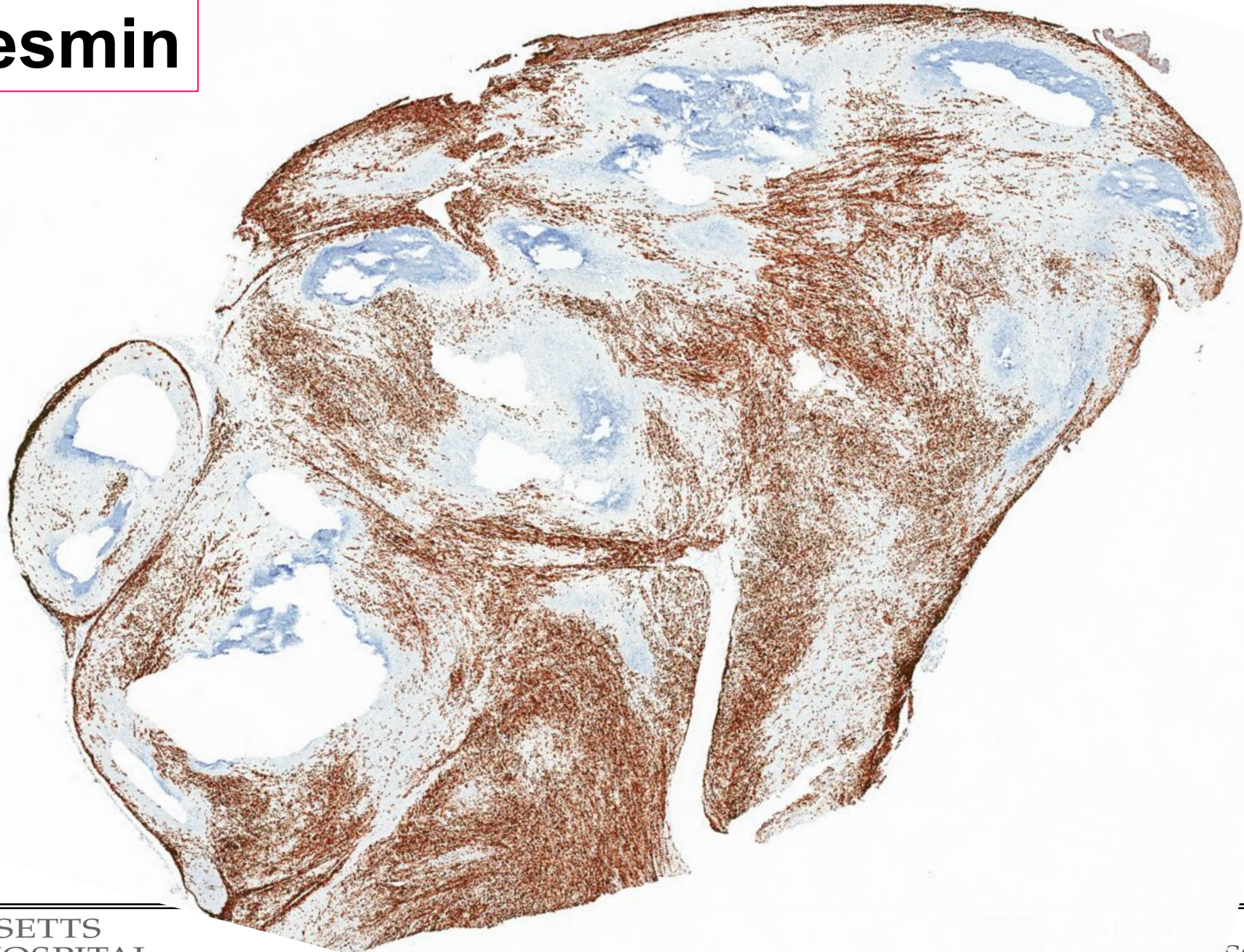









# Desmin



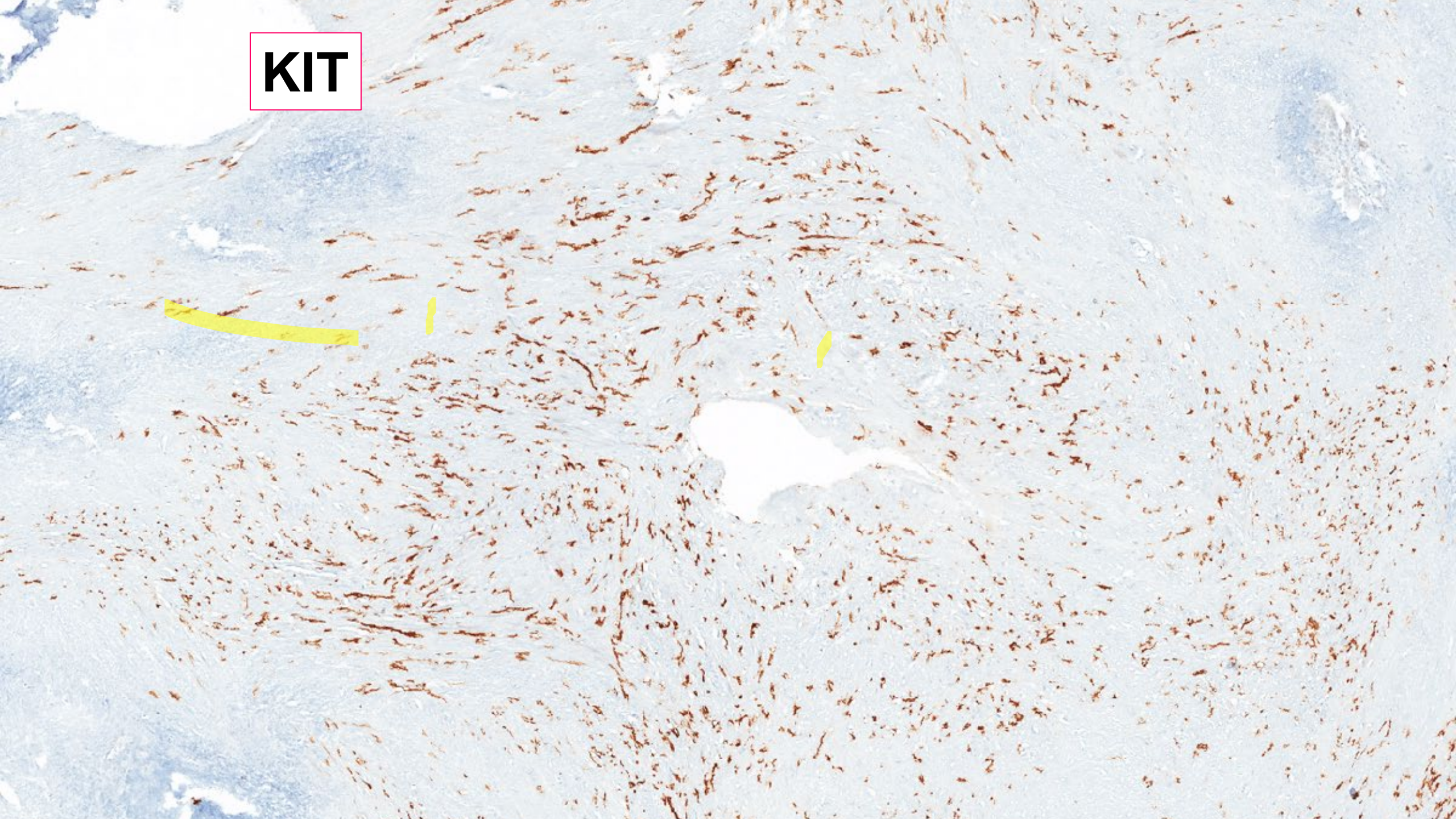


# Desmin



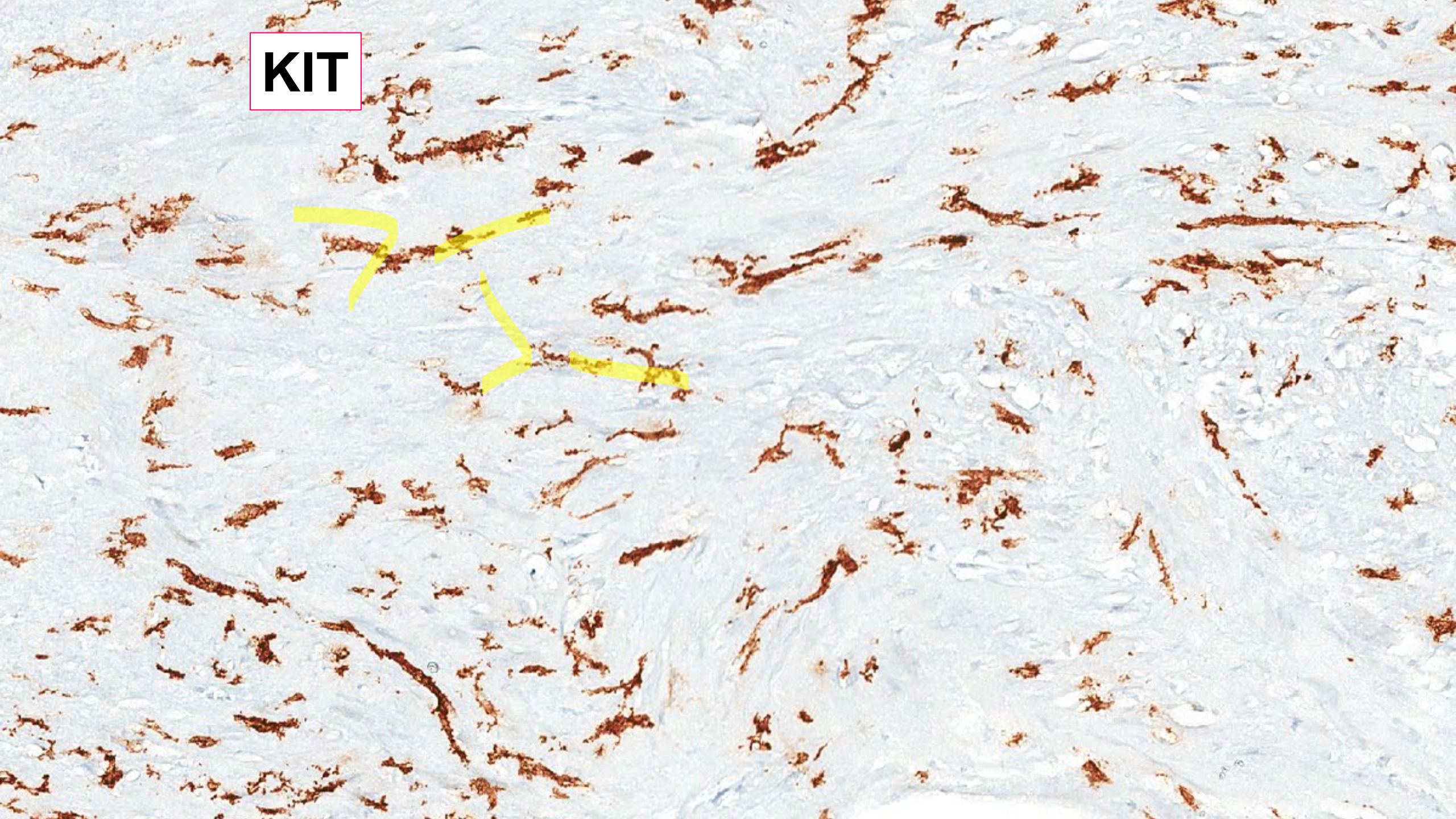


**KIT**





**KIT**





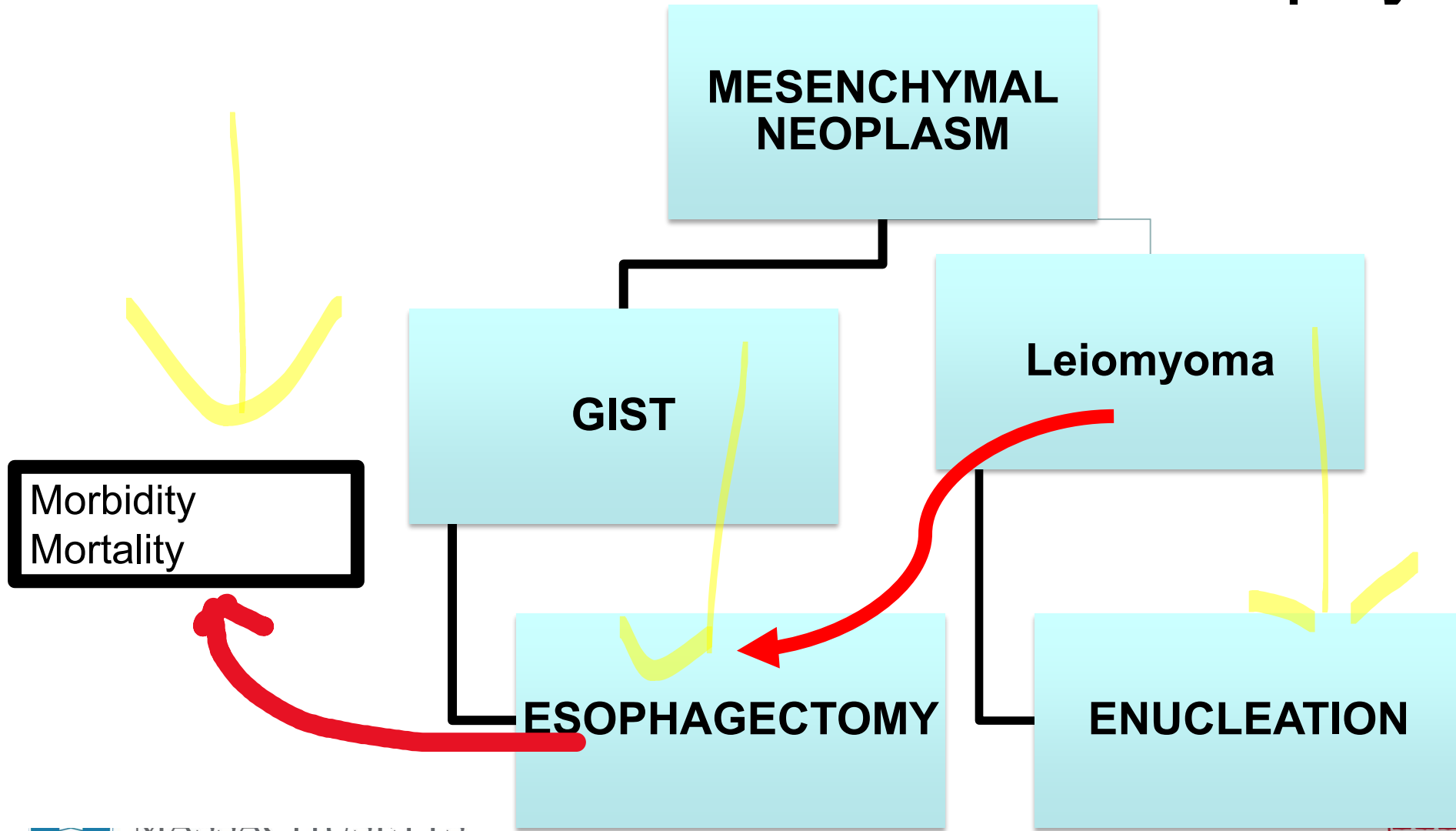
A histological slide showing smooth muscle tissue stained with hematoxylin and eosin (H&E). The tissue consists of bundles of spindle-shaped smooth muscle cells with elongated, cigar-shaped nuclei. The background is a dense network of pink-stained collagen fibers. Two white text boxes are overlaid on the image, containing diagnostic questions.

**GIST with desmin?**

**Leiomyoma with  
interstitial cells of Cajal?**



# Pay Particular Attention to Esophageal Lesions on needle biopsy







**KIT**

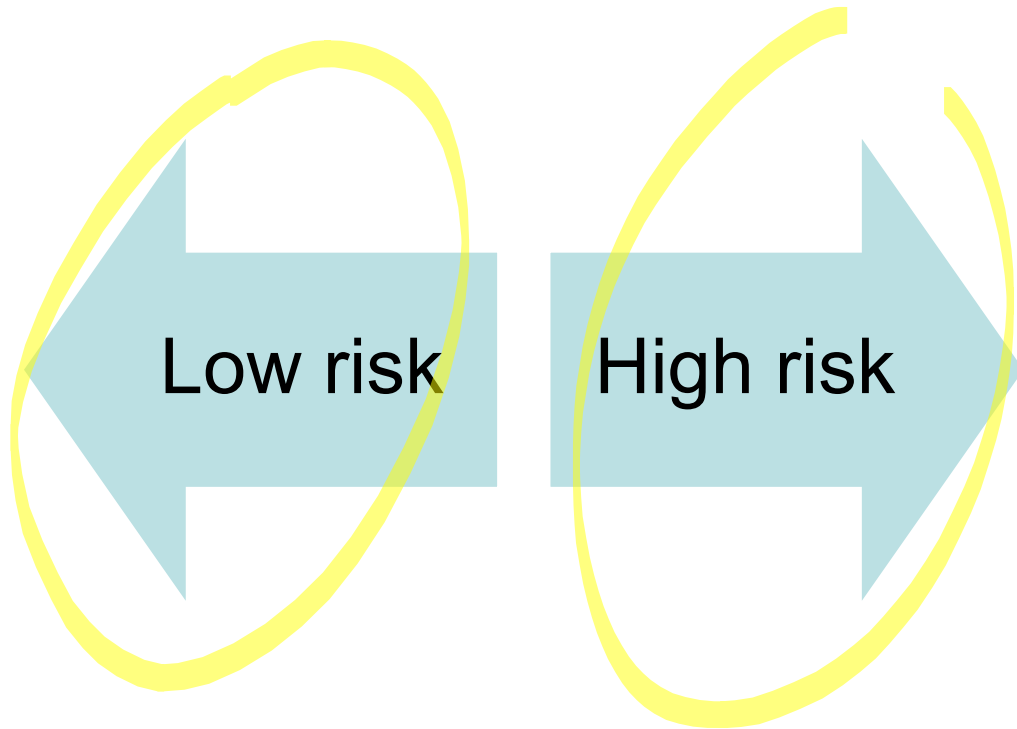
**Upper GI leiomyomas show**

**Reactive interstitial cells of Cajal  
in a leiomyoma**

Deshpande A, Nelson D, Corless CL, Deshpande V, O'Brien MJ. Leiomyoma of the gastrointestinal tract with interstitial cells of Cajal: a mimic of gastrointestinal stromal tumor. *Am J Surg Pathol.* 2014 Jan;38(1):72-7.



# Esophagus



# Colon

Moderate-to-severe atypia  
High cellularity  
Abnormal differentiation  
Tumor necrosis  
Mucosal ulceration  
Lamina propria involvement  
Serosal involvement

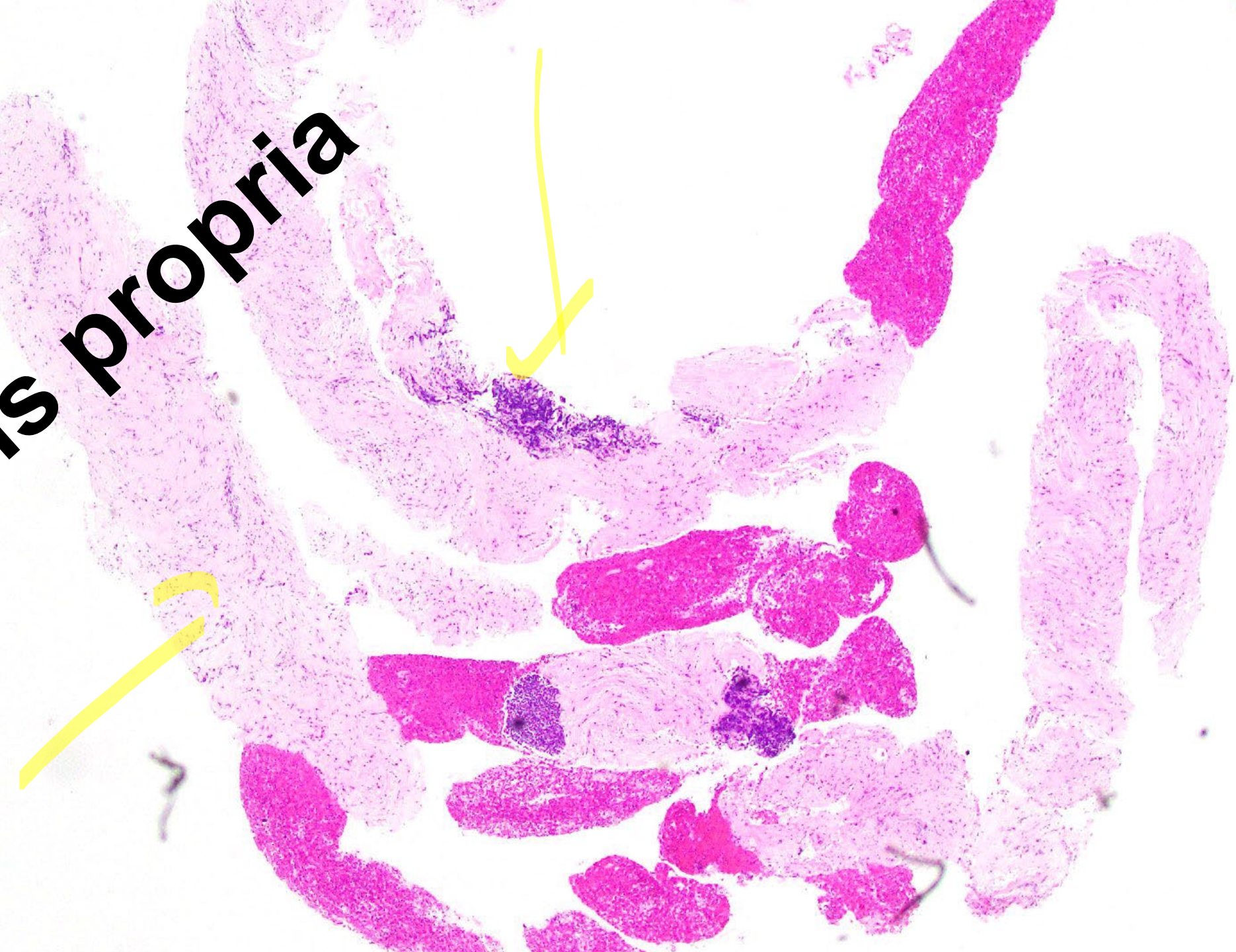
**> 10 cm**

**$\geq 3$  mitosis per 5 mm<sup>2</sup>**

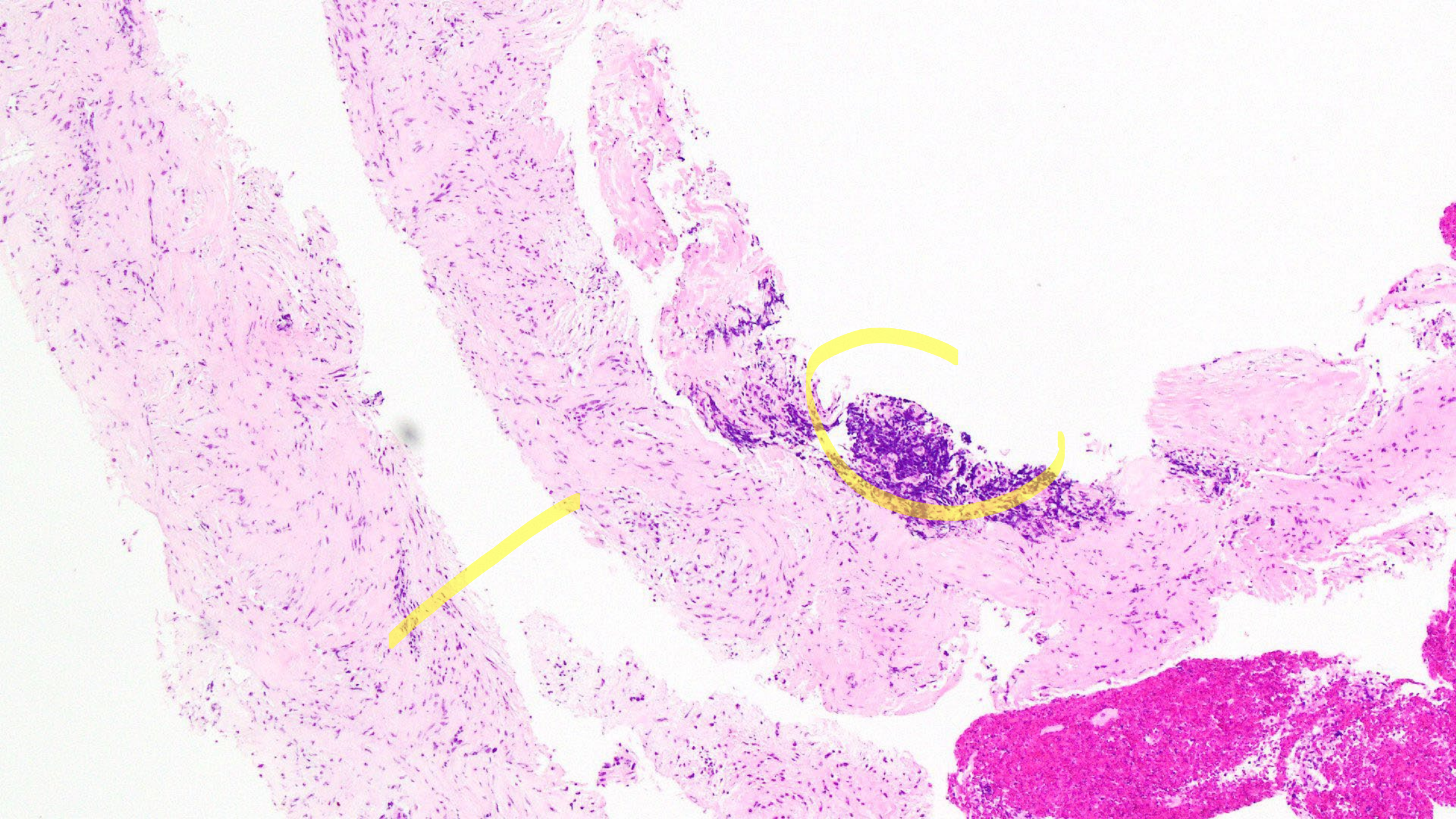
Mod Pathol. 2020 Jul;33(7):1410-1419



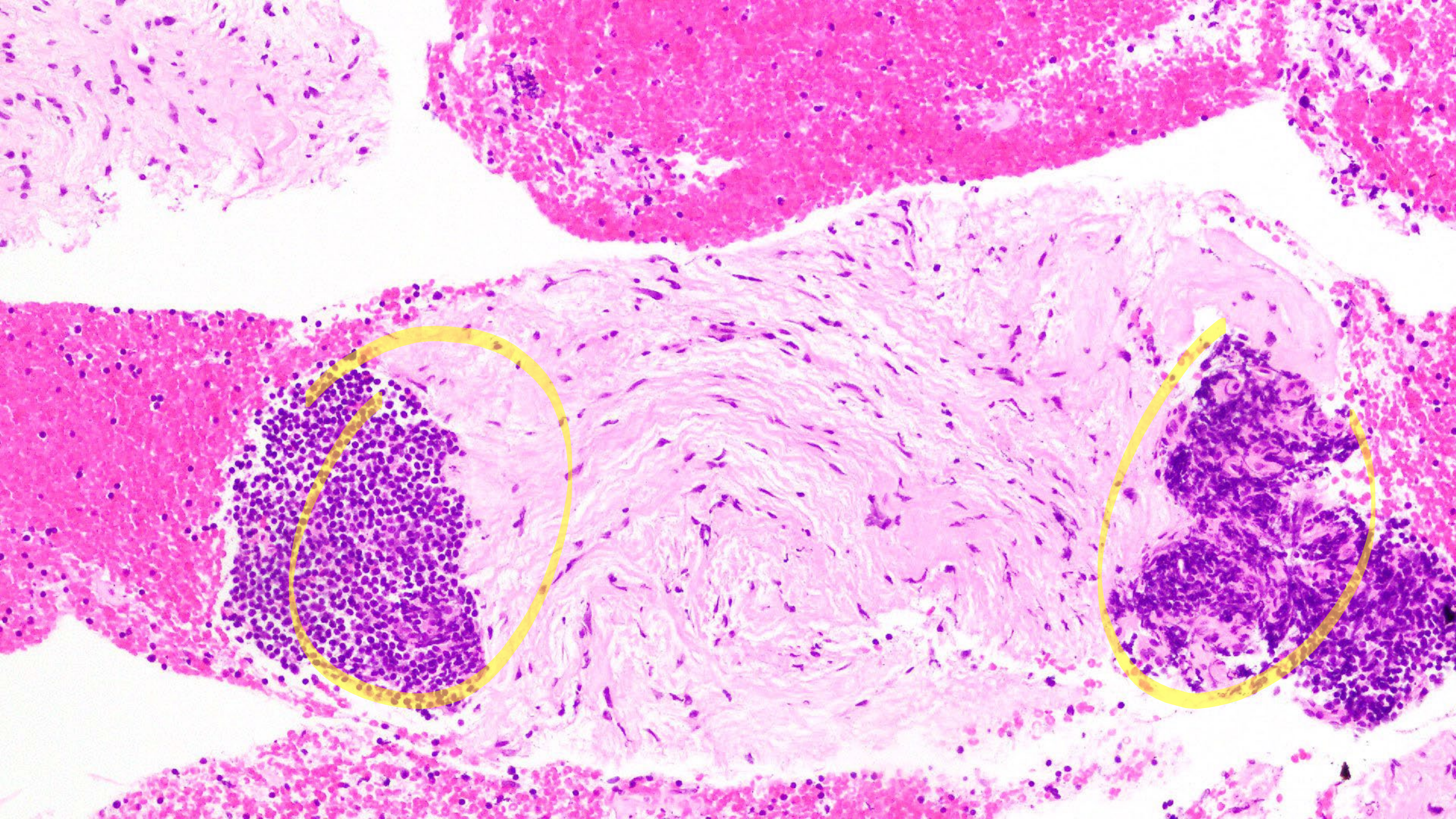
**muscularis propria**



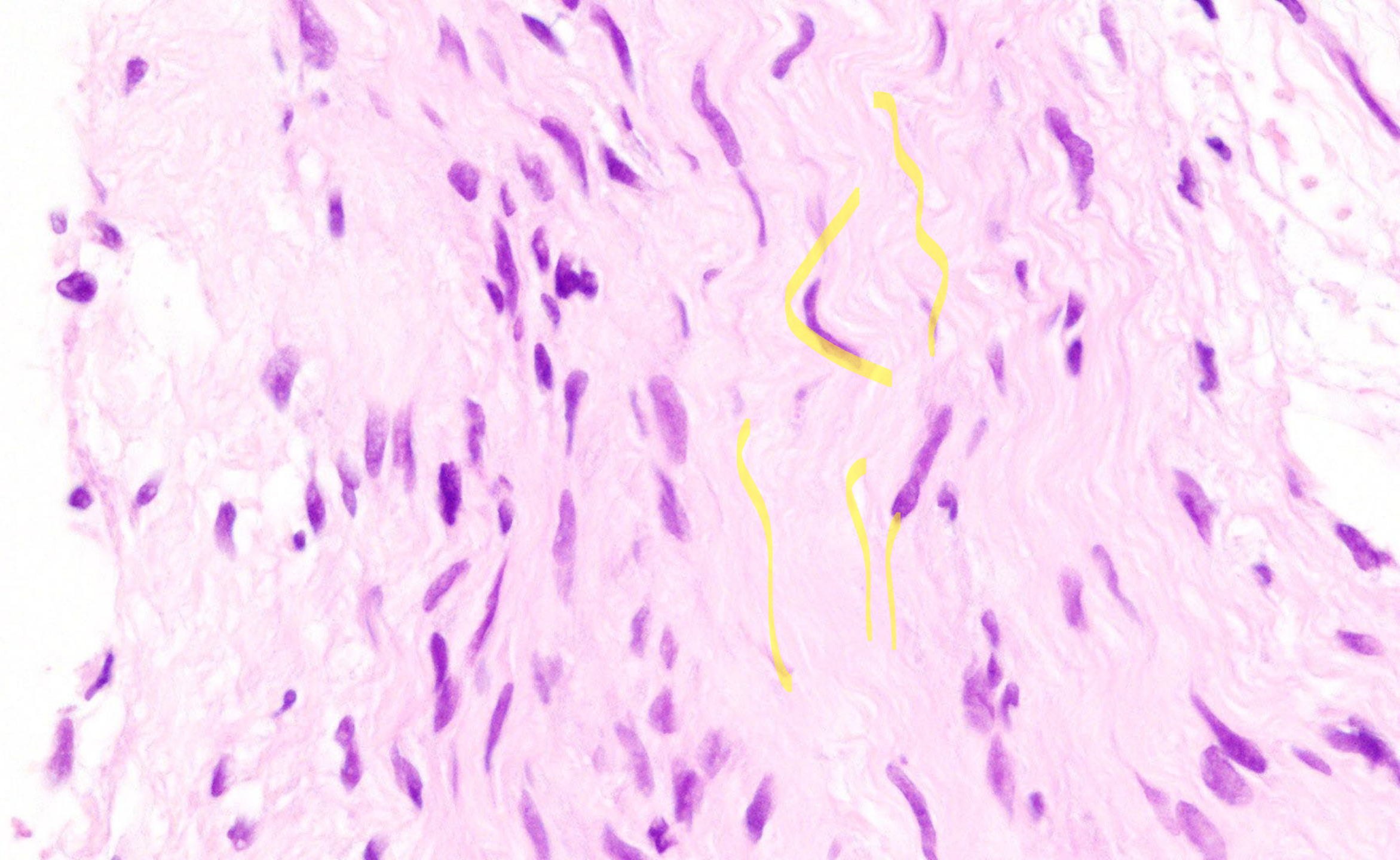




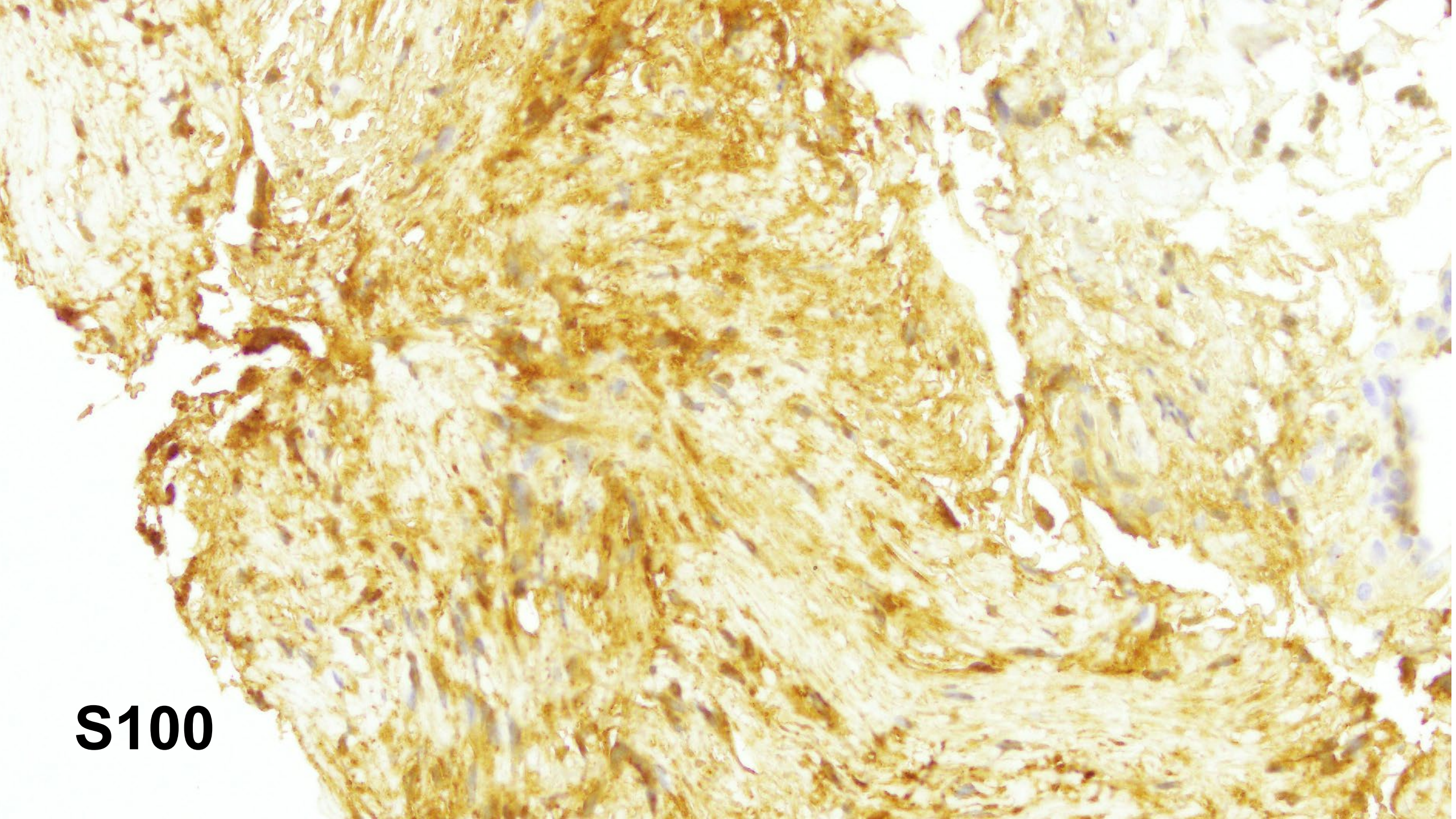








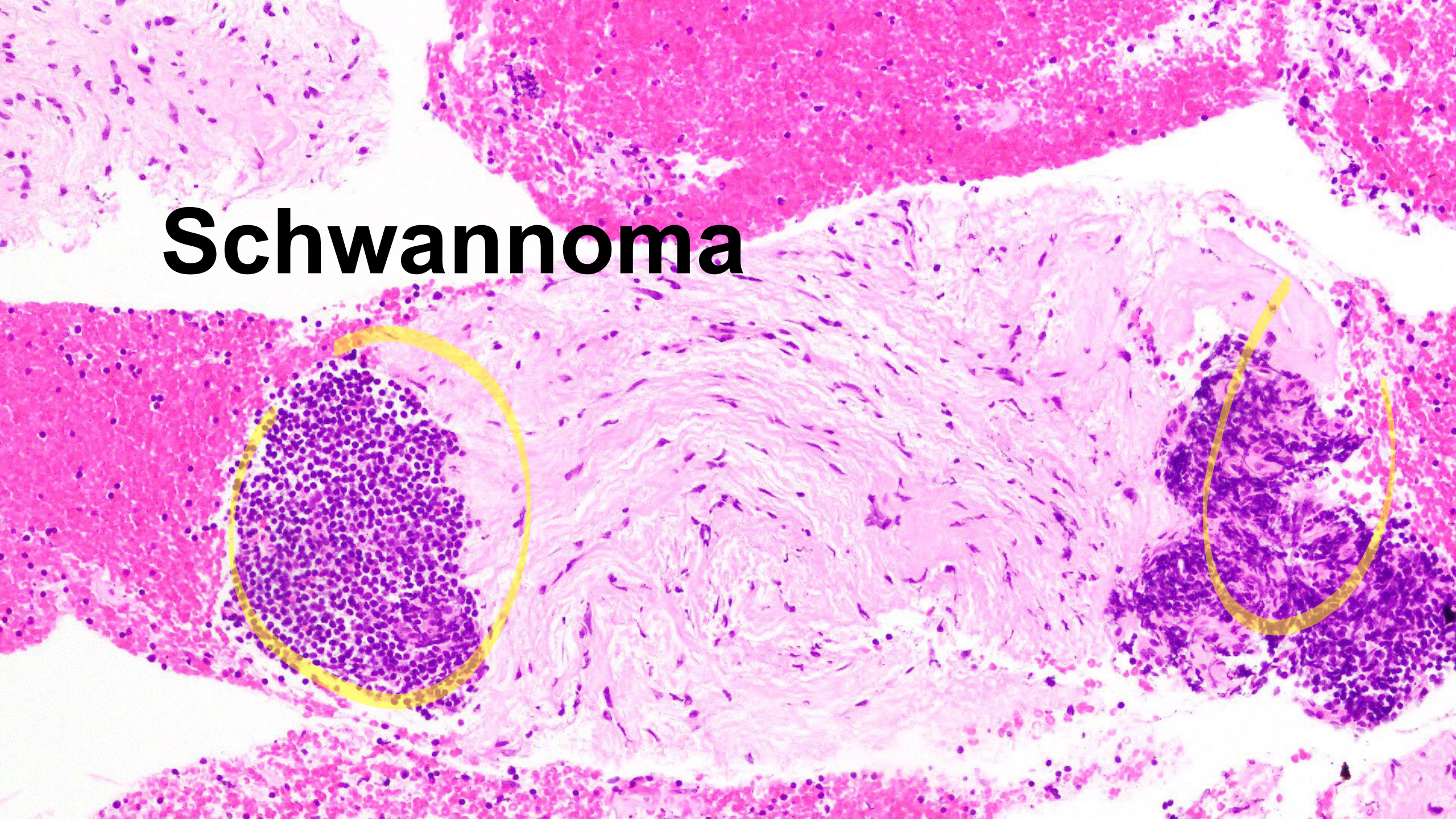




**S100**



# Schwannoma





|               | <b>Keratin</b> | <b>CD117</b> | <b>DOG1</b> | <b>CD34</b> | <b>SMA</b> | <b>Desmin</b> | <b>S100</b> |
|---------------|----------------|--------------|-------------|-------------|------------|---------------|-------------|
| GIST          | -              | +            | +           | 70%         | 30-40%     | Very rare     | Very rare   |
| Smooth muscle | -/+            | -            | -           | 10-15%      | +          | +             | Very rare   |
| Fibromatosis  | -              | -            | -           | Very rare   | +          | Very rare     | -           |
| Schwannoma    | -              | -            | -           | -           | -          | -             | +           |





# Mucosal bumps

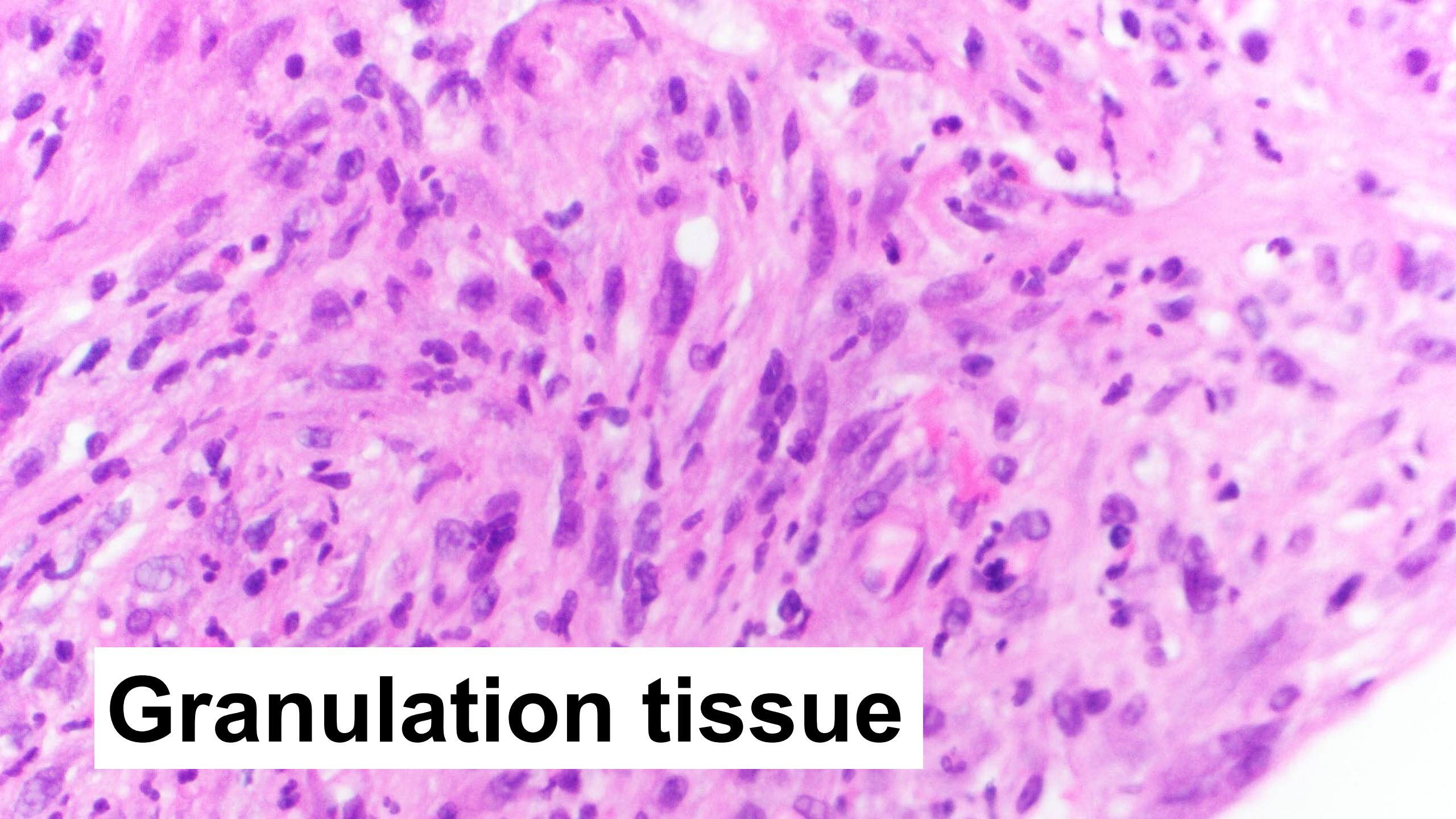




Most common bland spindle cell lesion in  
the mucosa?

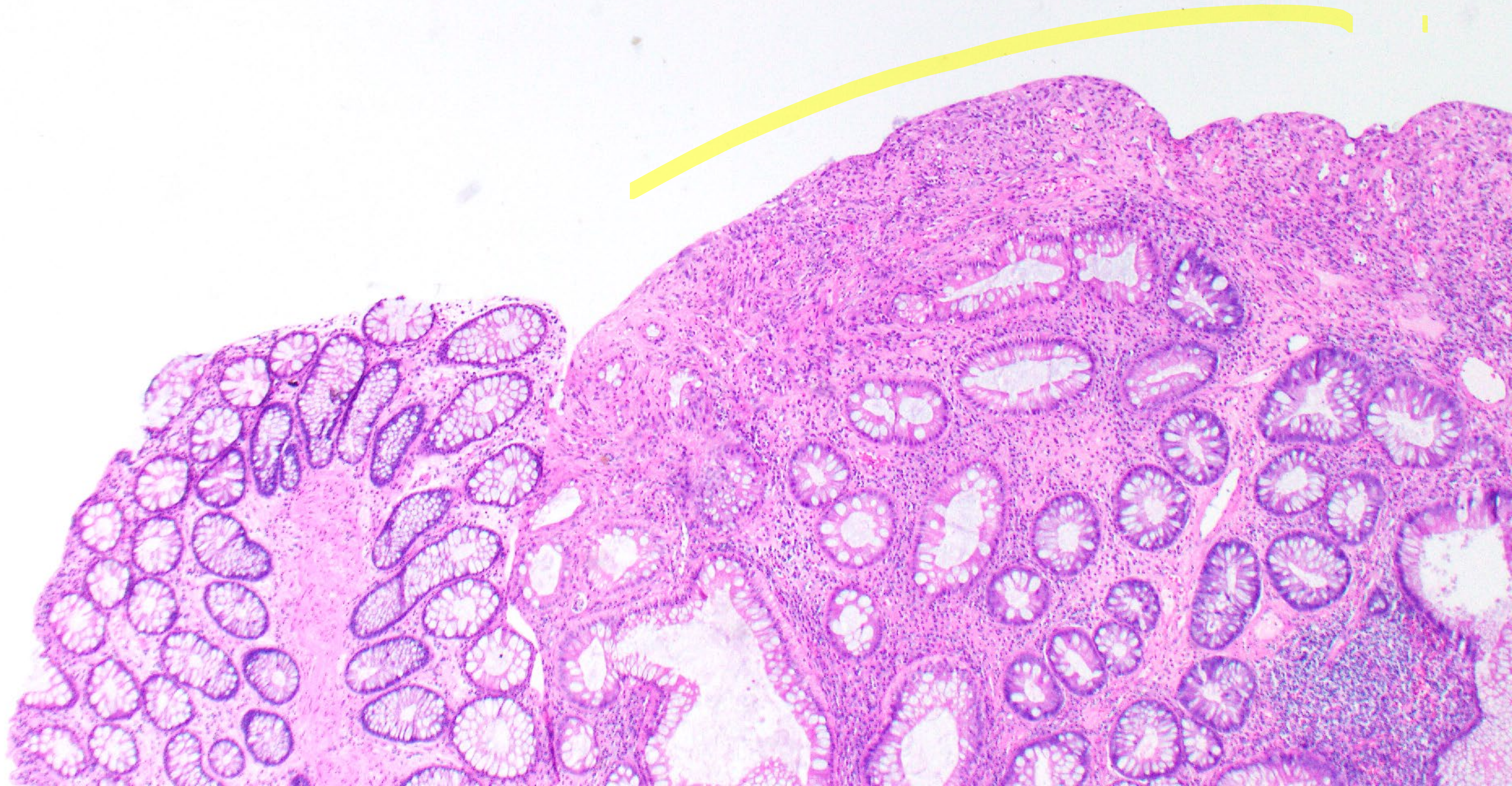




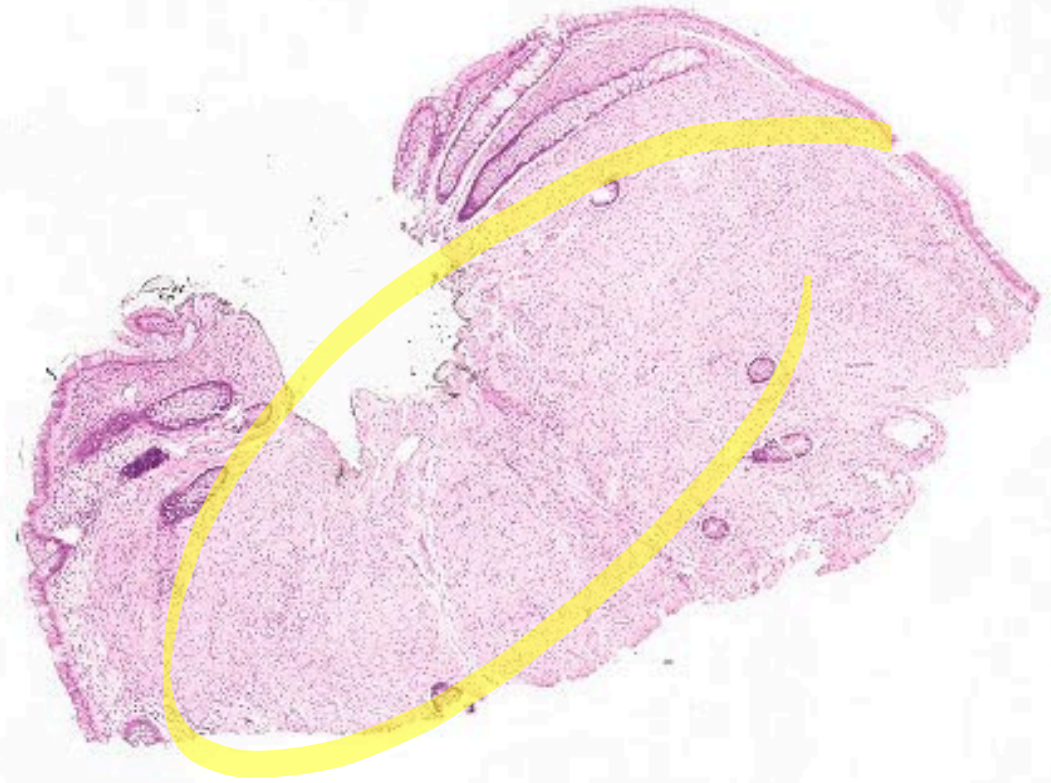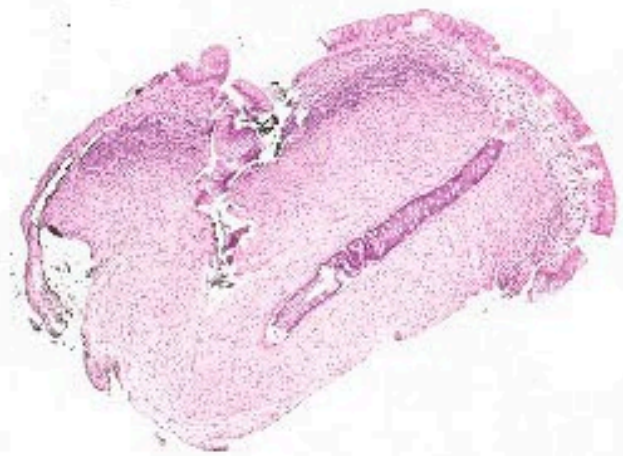


**Granulation tissue**



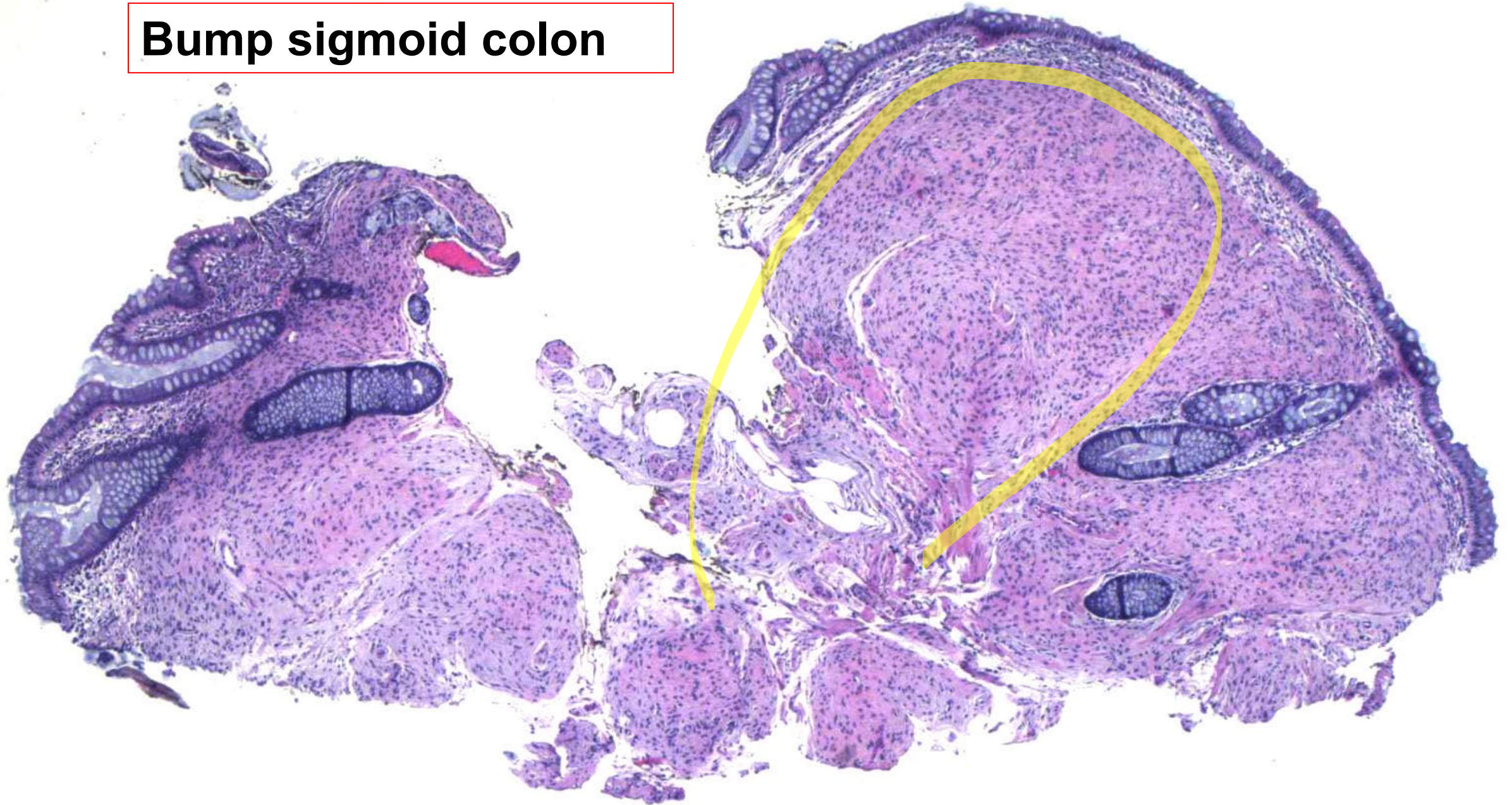






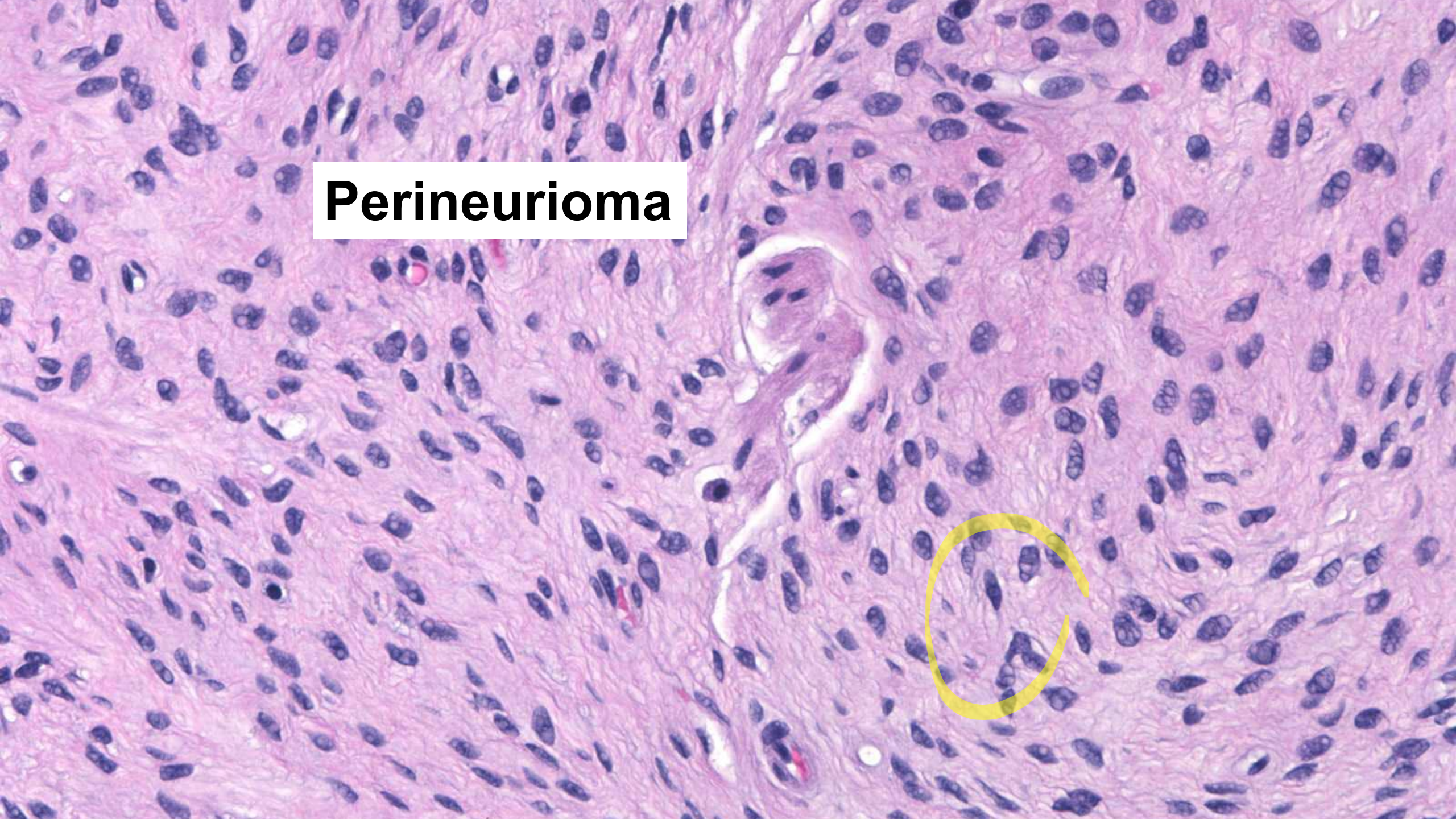


# Bump sigmoid colon





# Perineurioma







Perineurioma

EMA

**Other Perineurioma markers**

Glut1 (not specific)

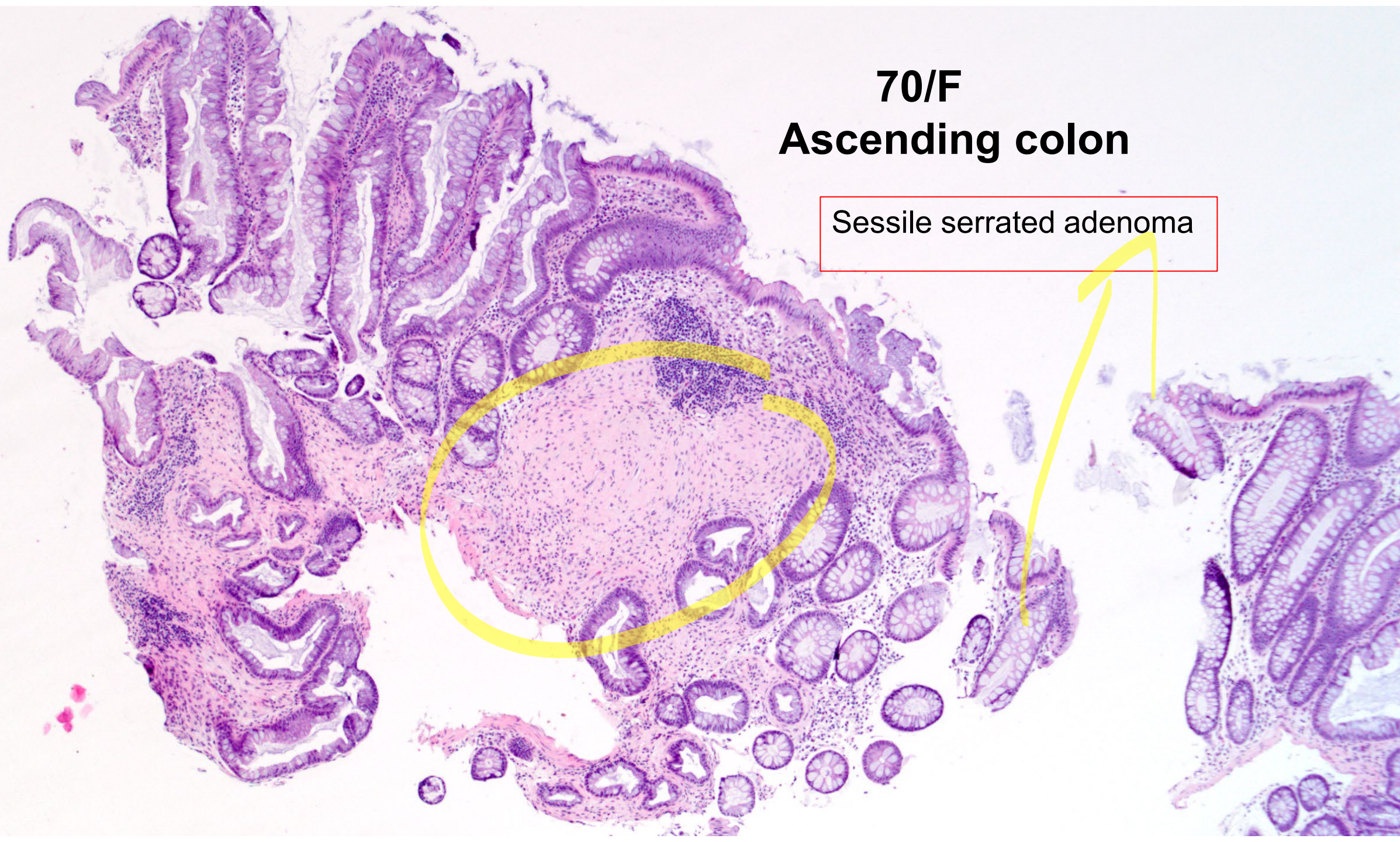
Claudin-1 (not sensitive)



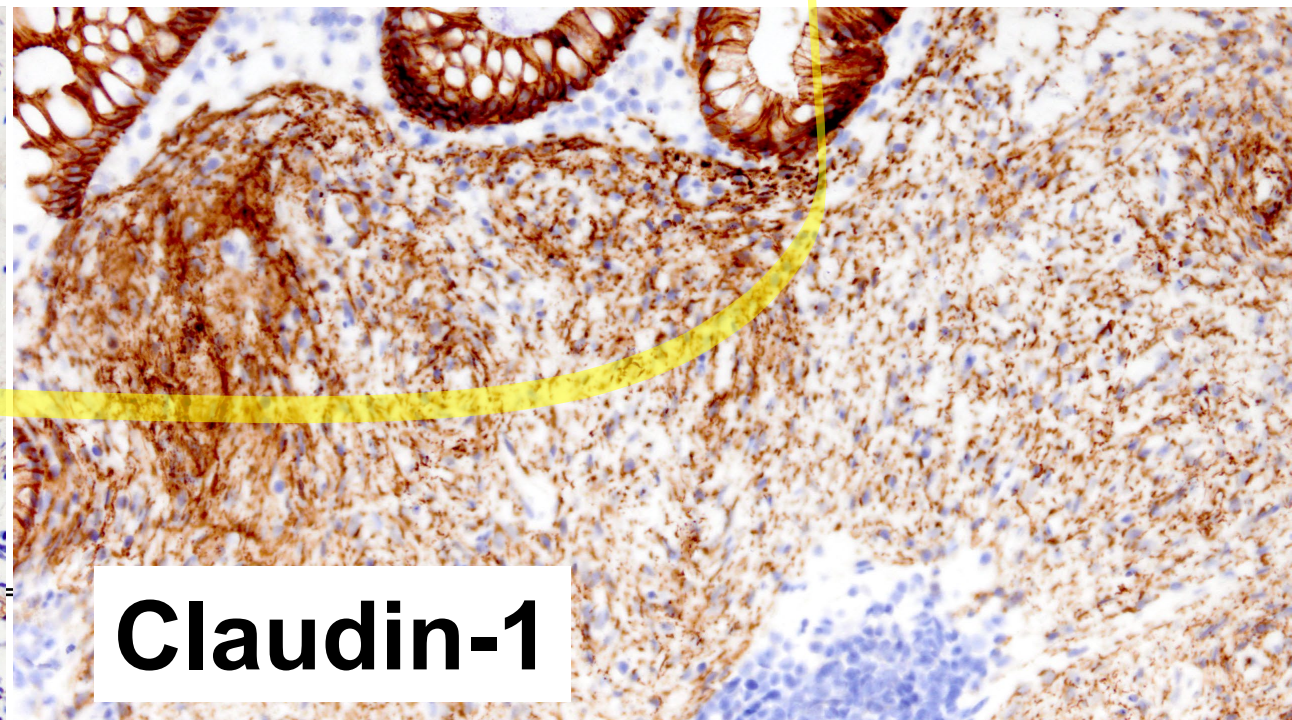
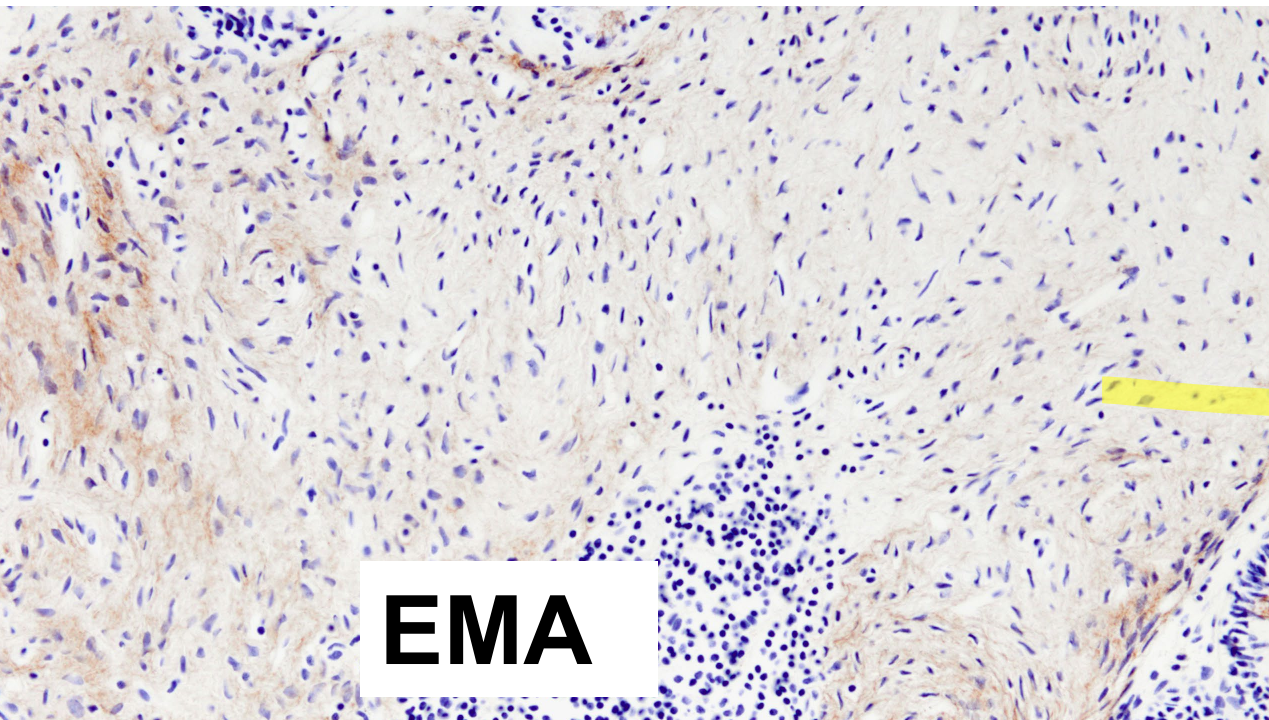
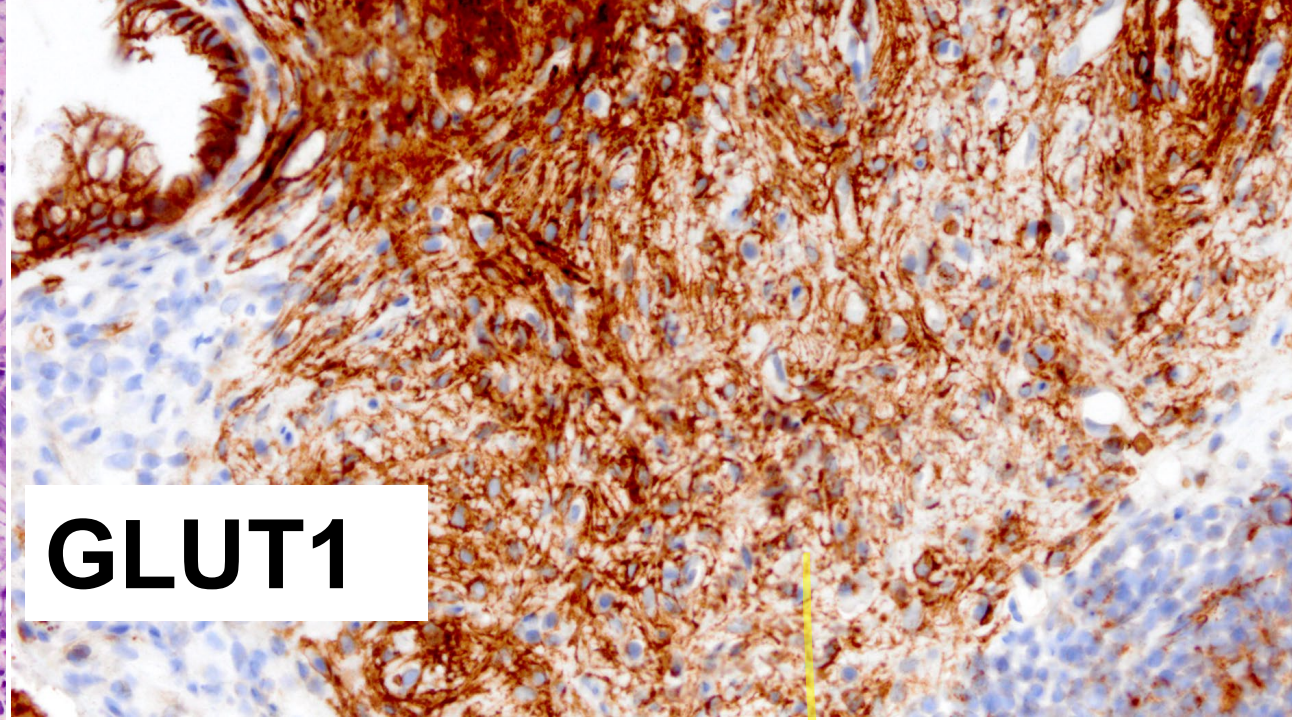
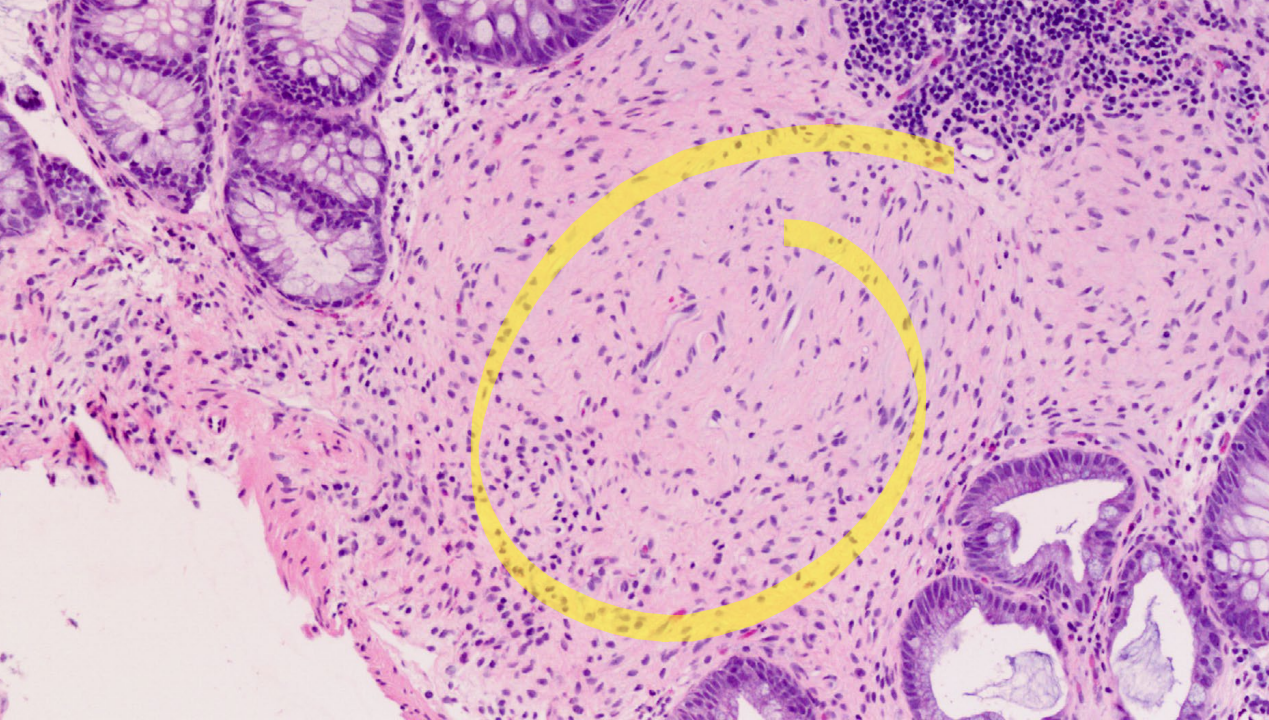
**70/F**

**Ascending colon**

Sessile serrated adenoma

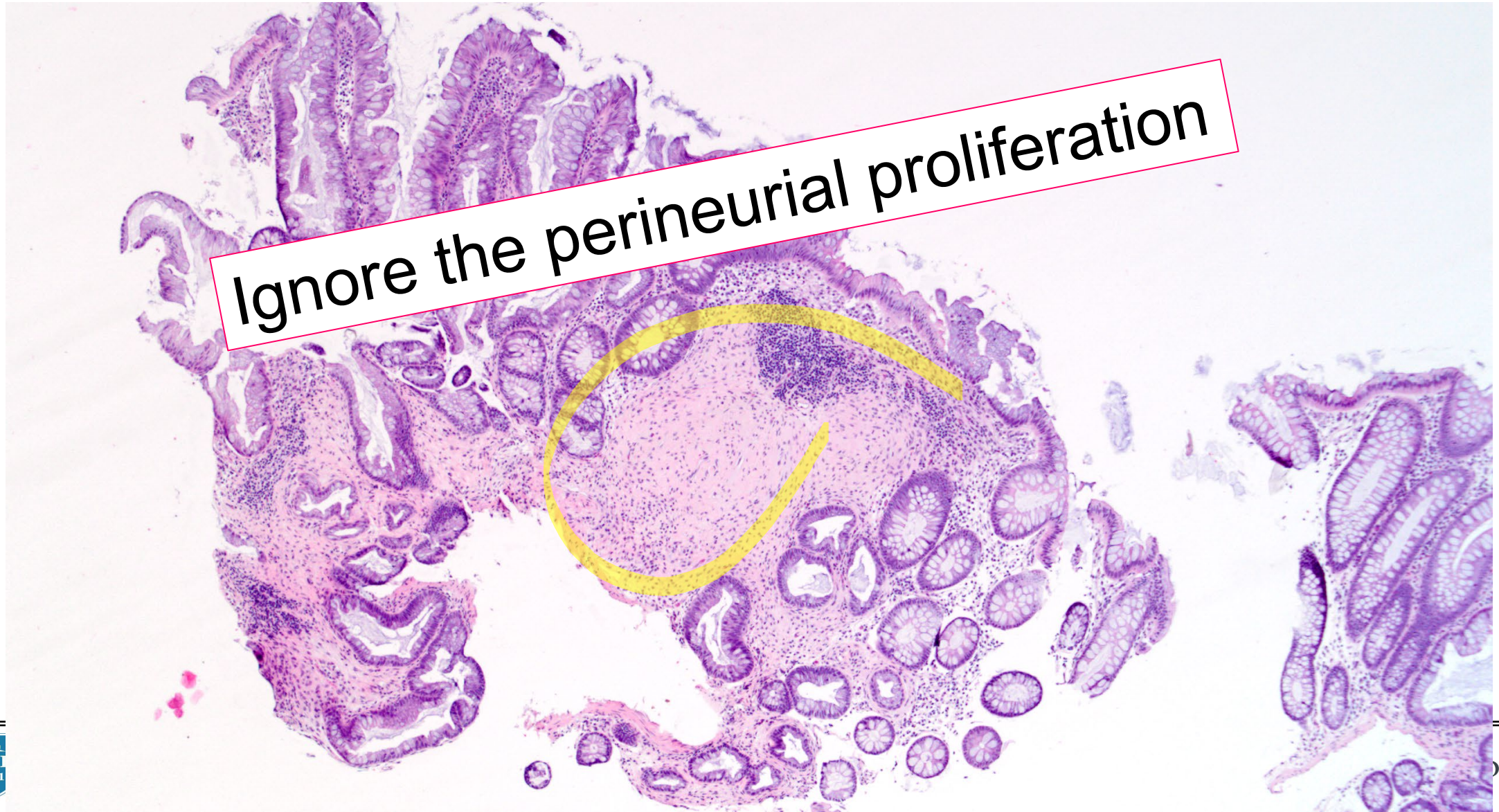






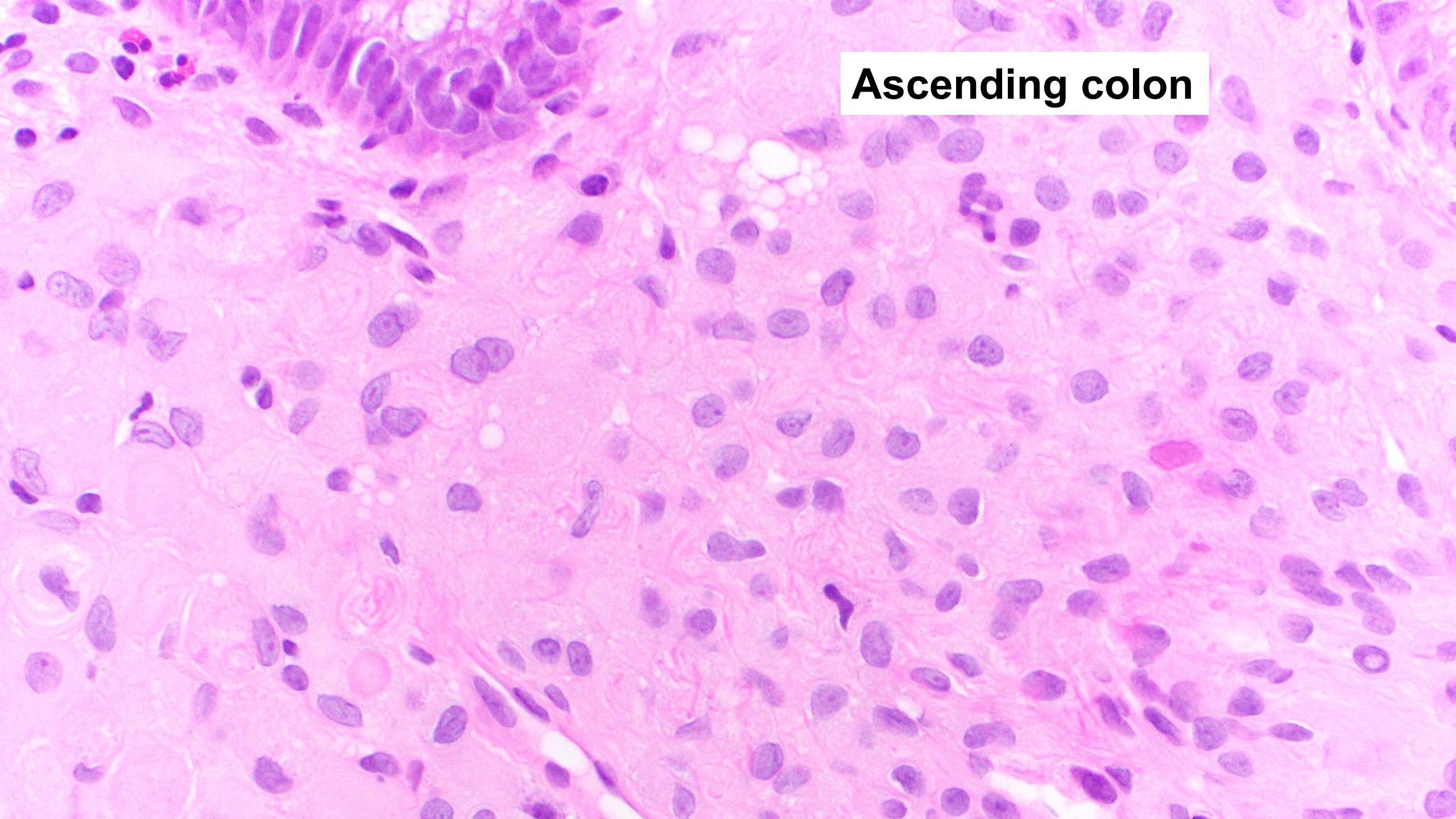


# Perineurial proliferation with Serrated Lesion



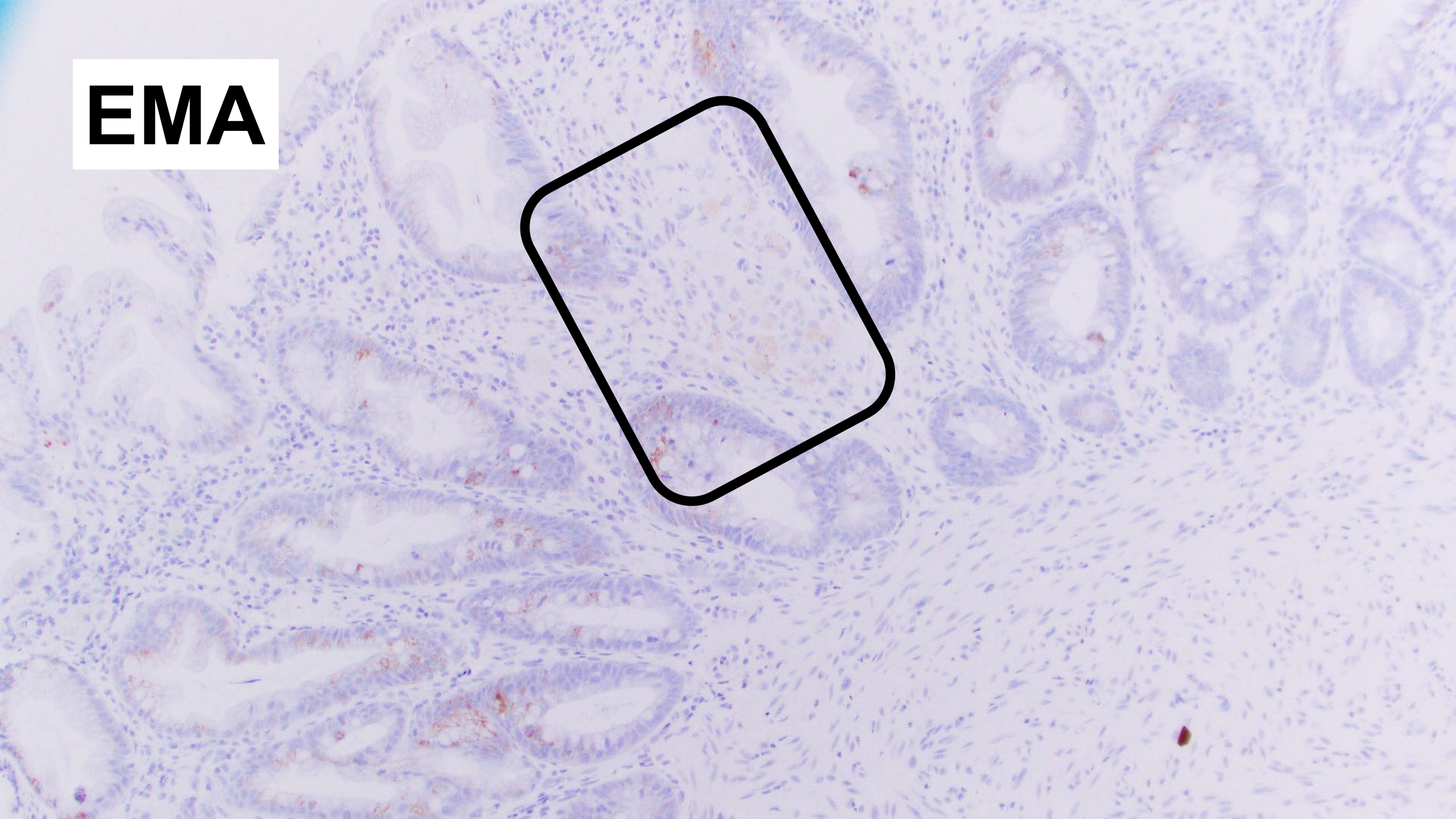


**Ascending colon**



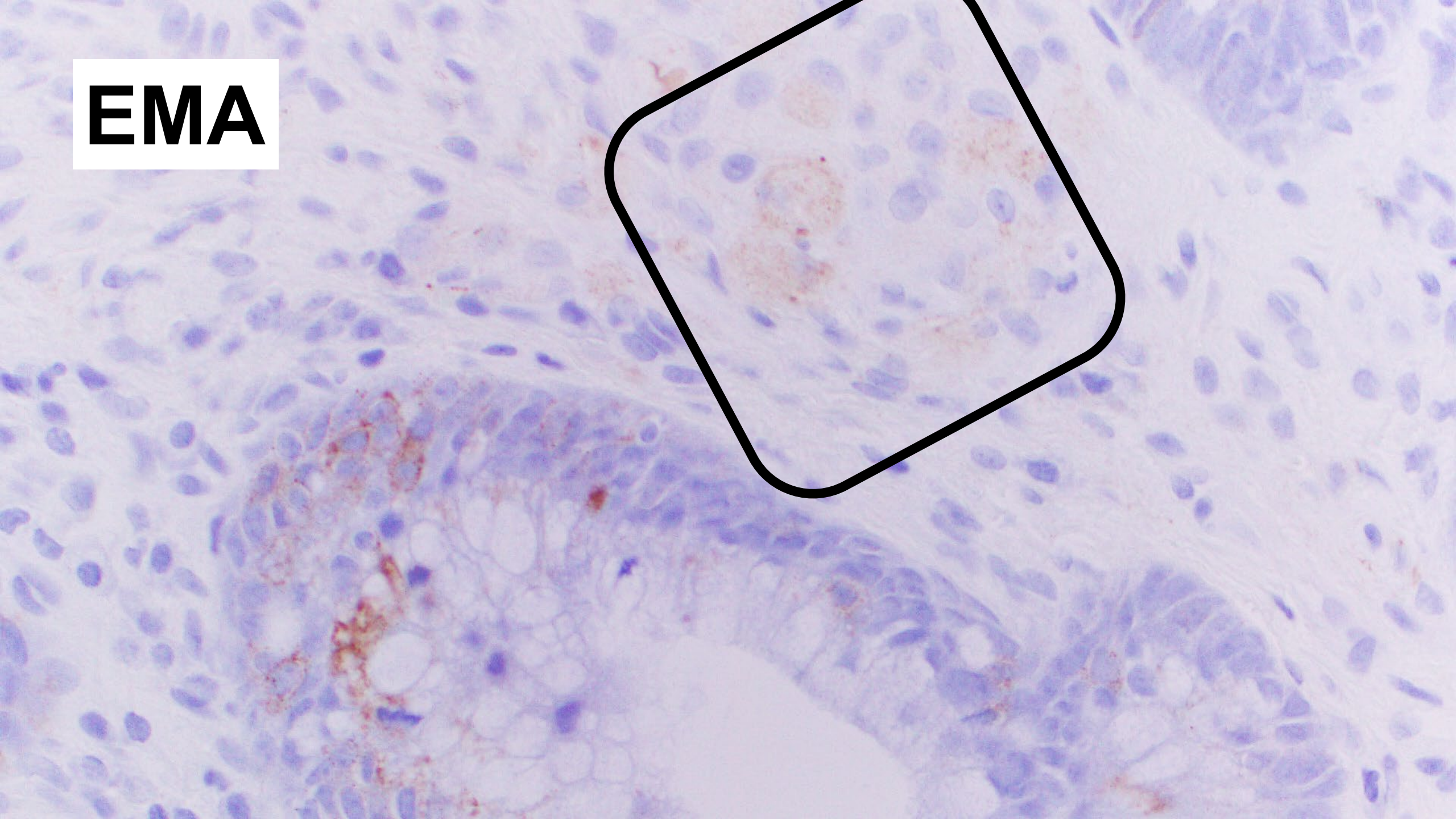


**EMA**

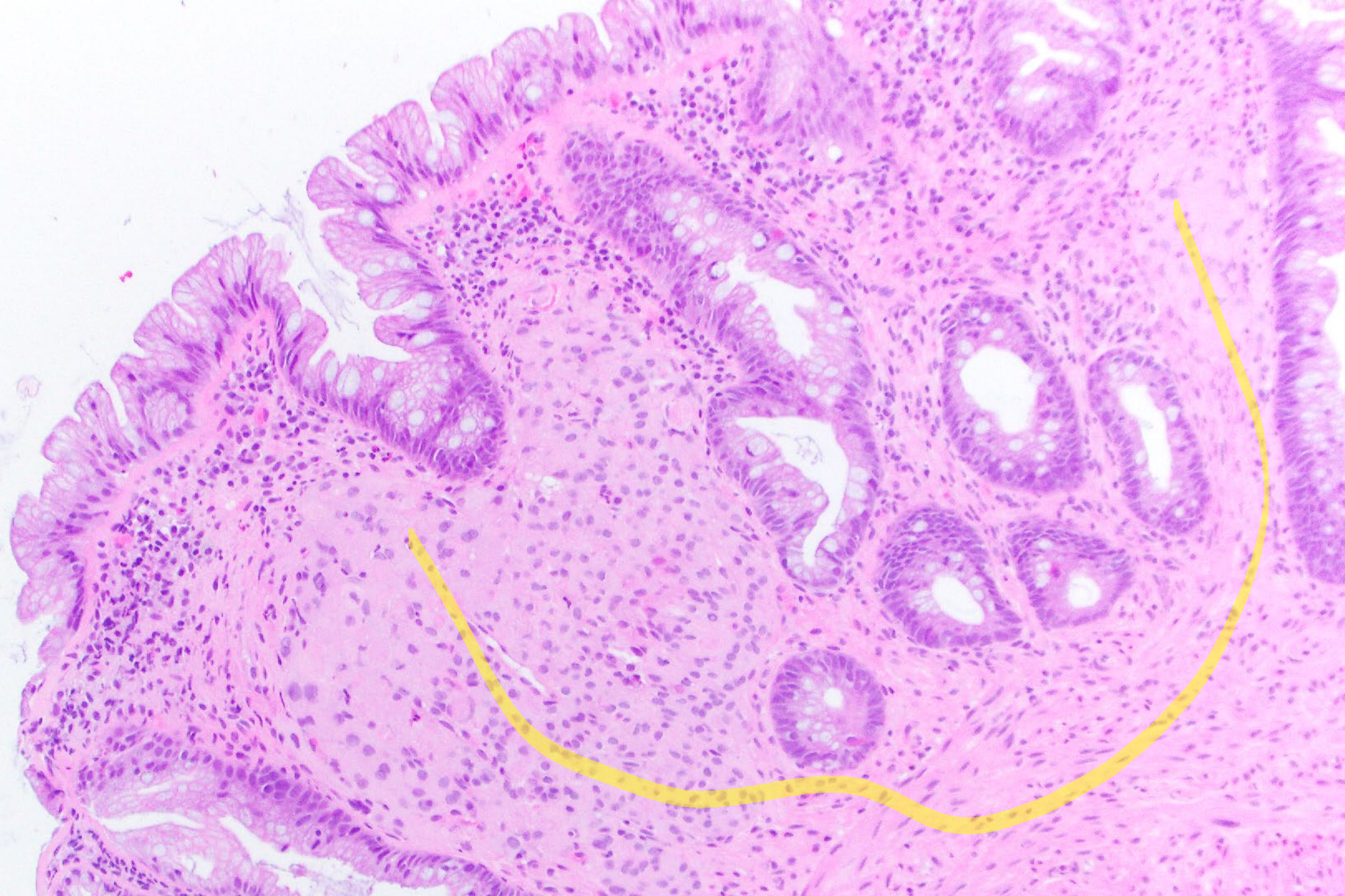




**EMA**

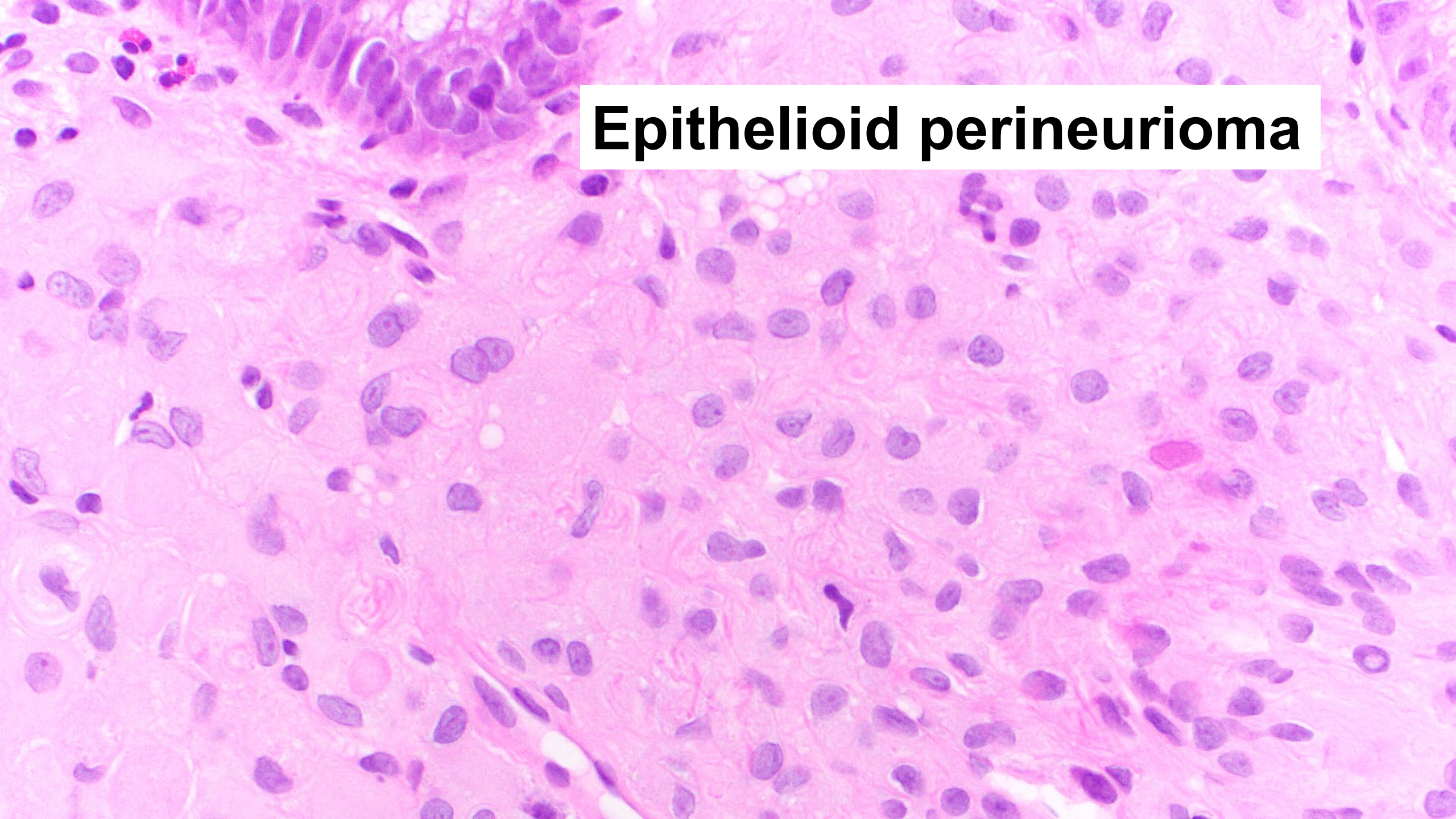




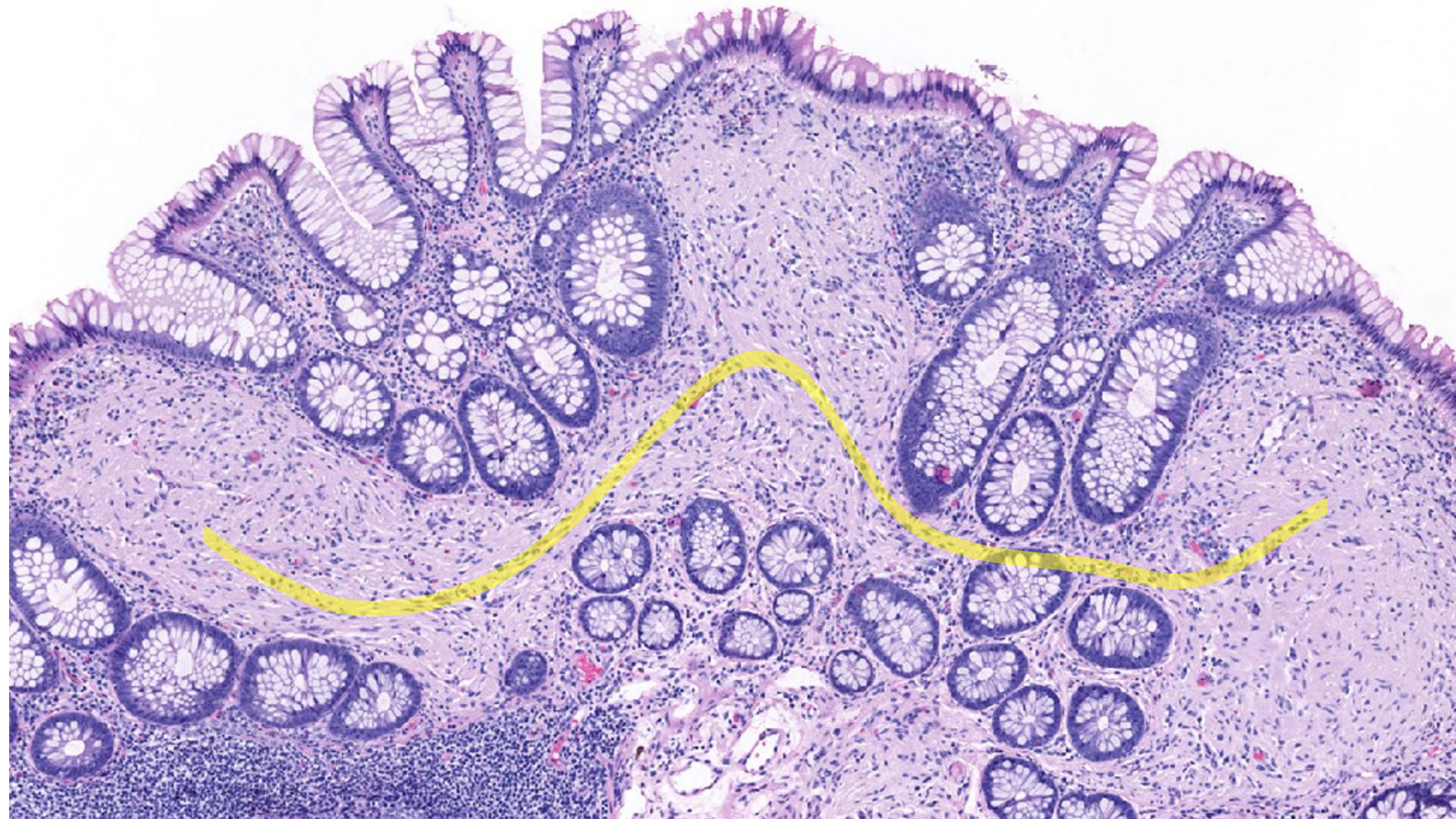




# Epithelioid perineurioma

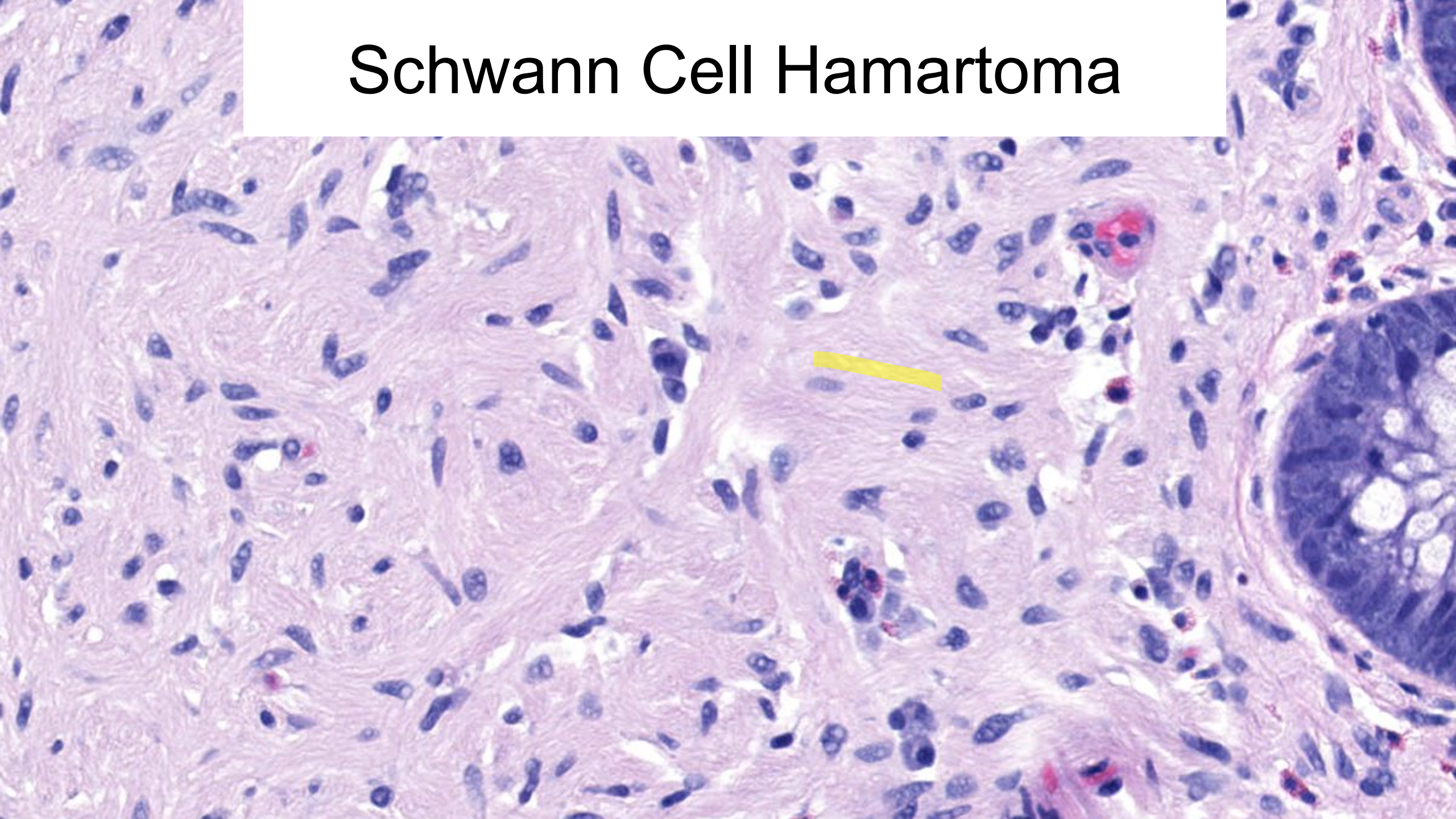




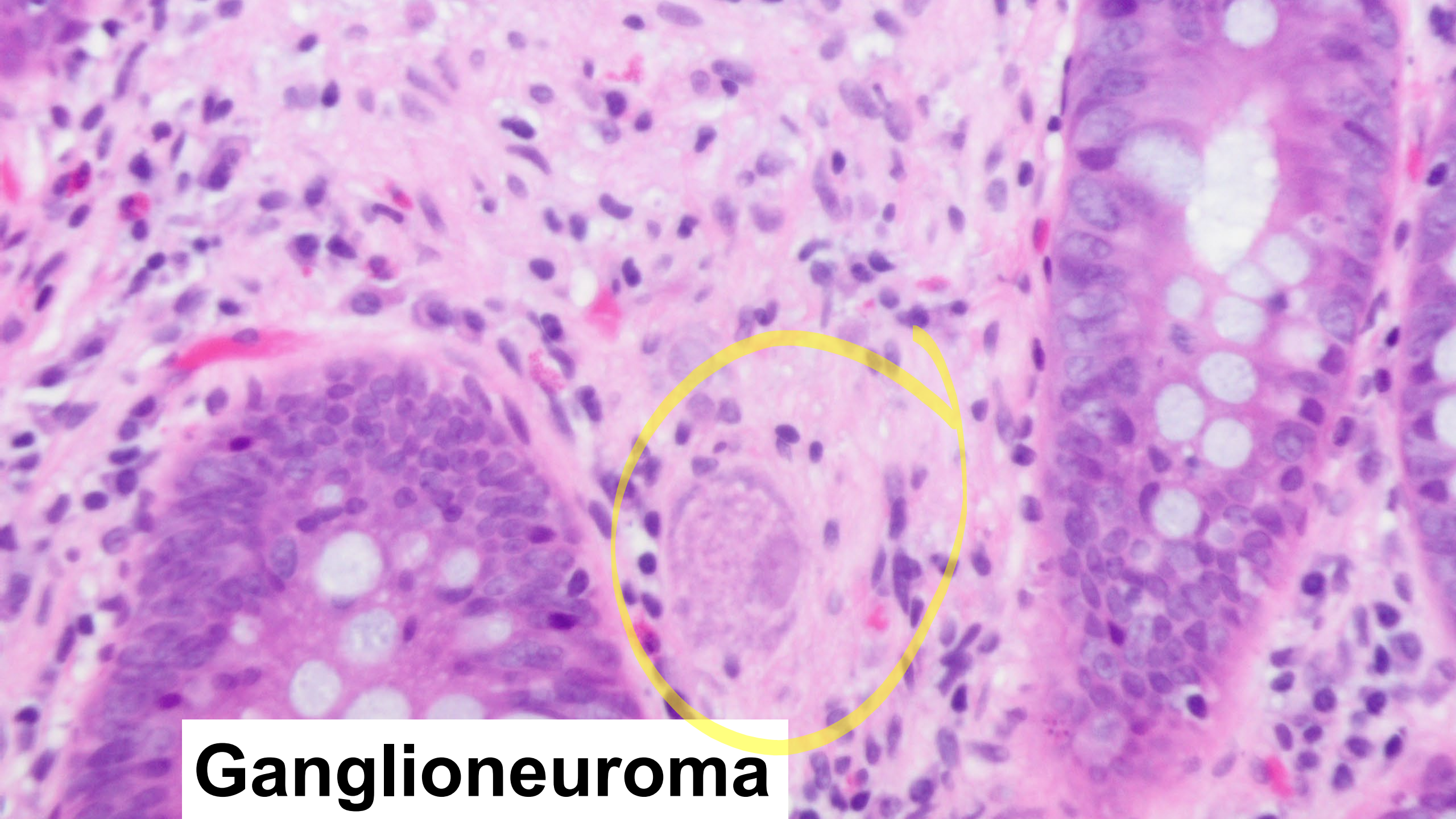




# Schwann Cell Hamartoma

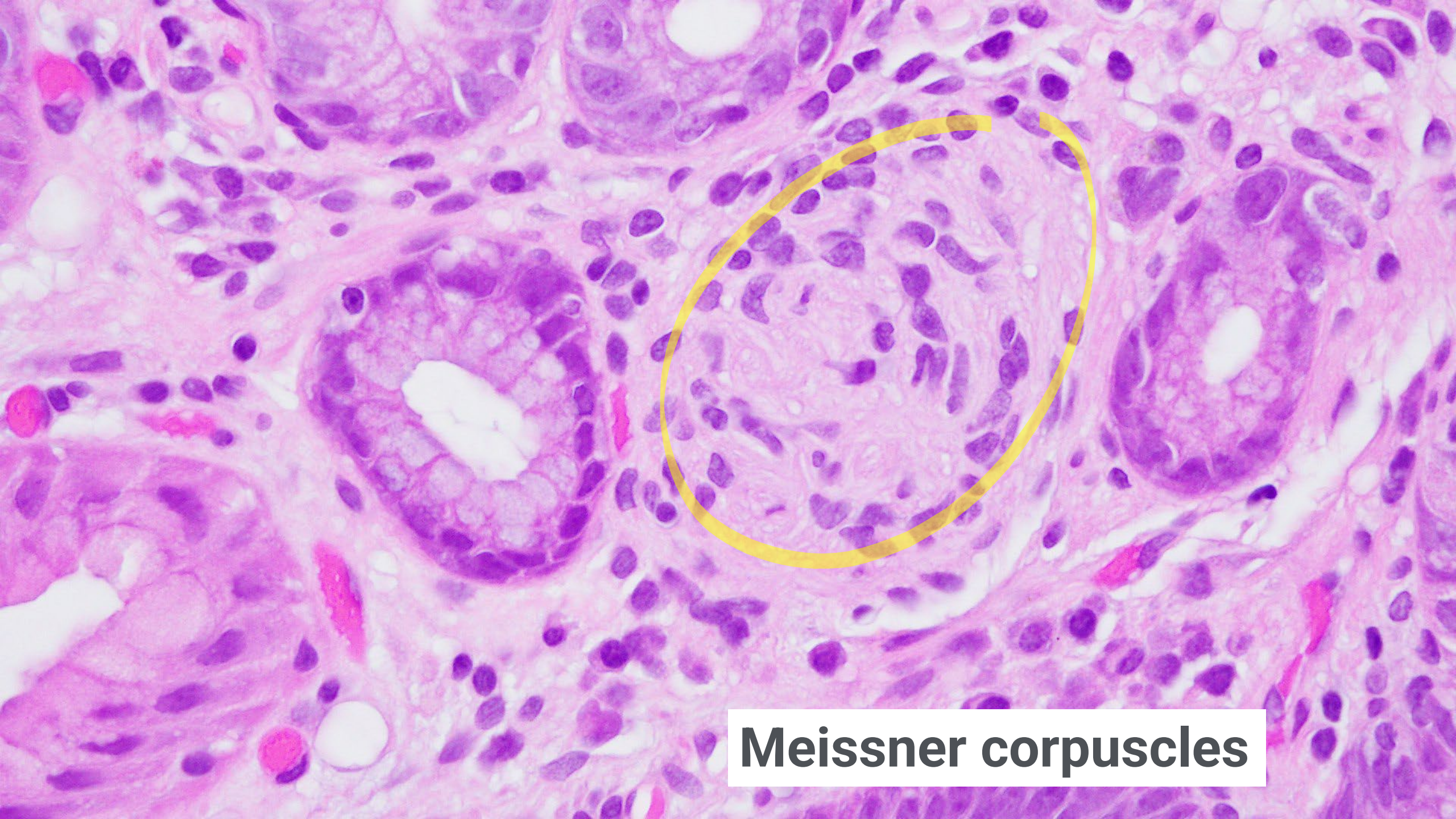






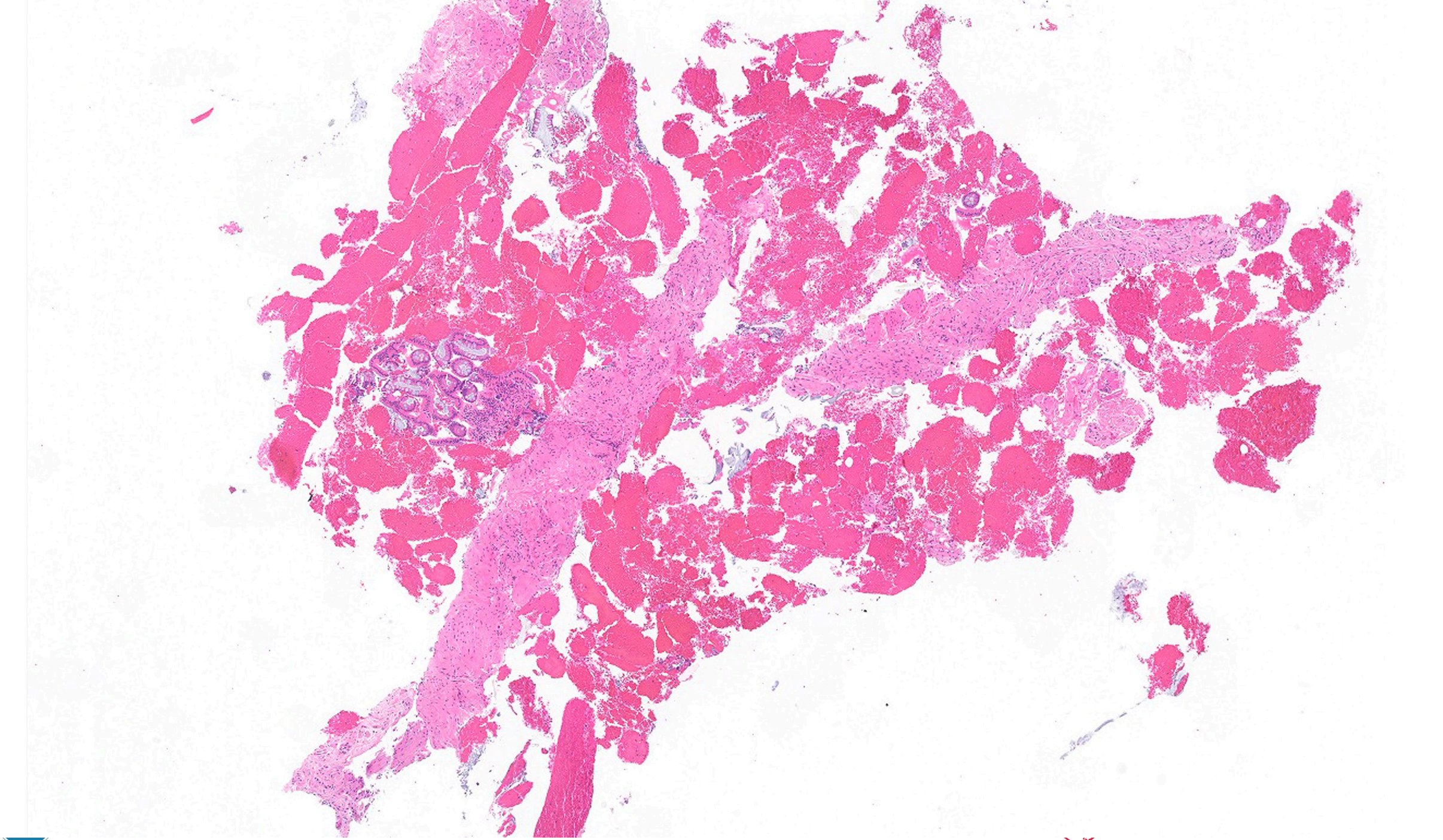
**Ganglioneuroma**



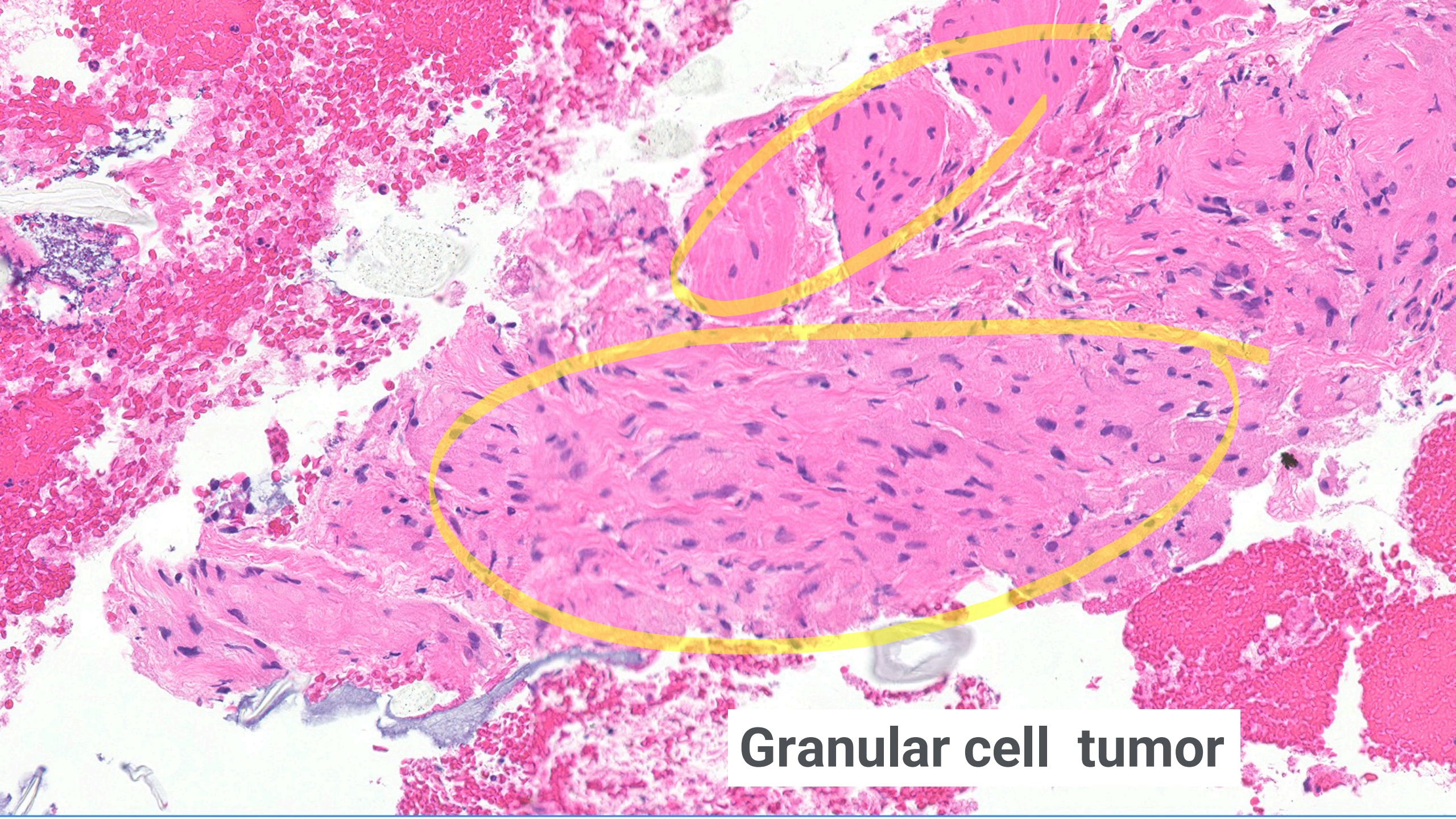


**Meissner corpuscles**





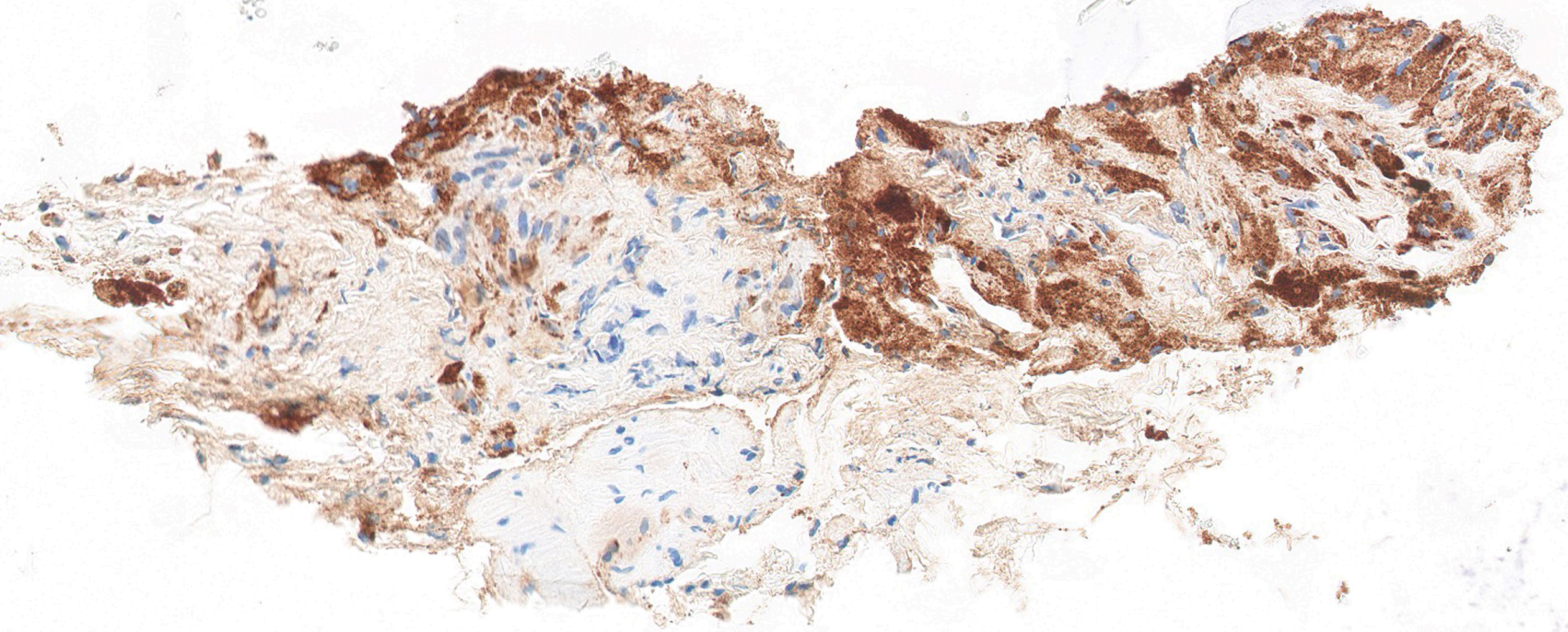




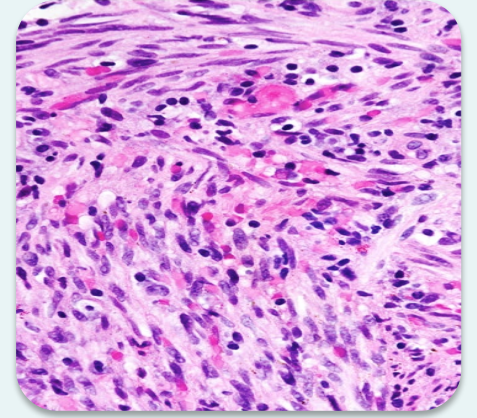
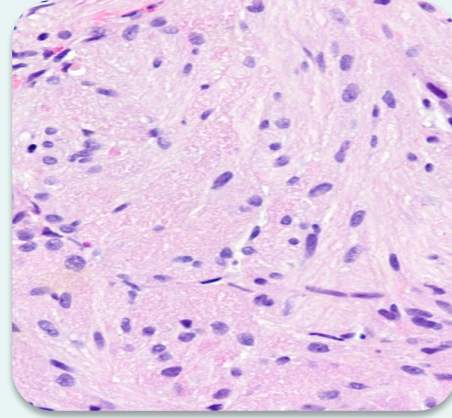
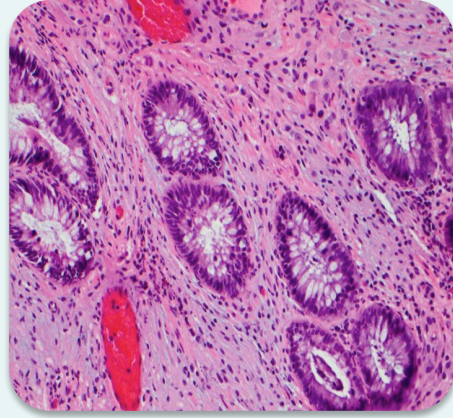
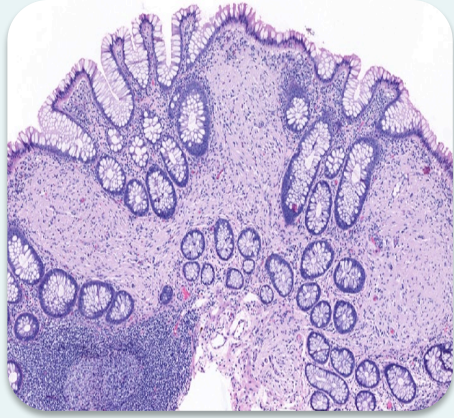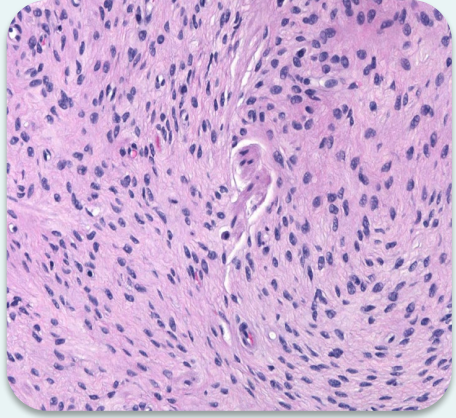
**Granular cell tumor**



S100







**Perineurioma**

**Schwann Cell H**

**Ganglioneuroma**

**Granular cell T**

**Kaposi Sarcoma**

**S100  
Negative**

**S100  
Positive**

**S100  
Positive**

**S100  
Positive**

**S100  
Negative**

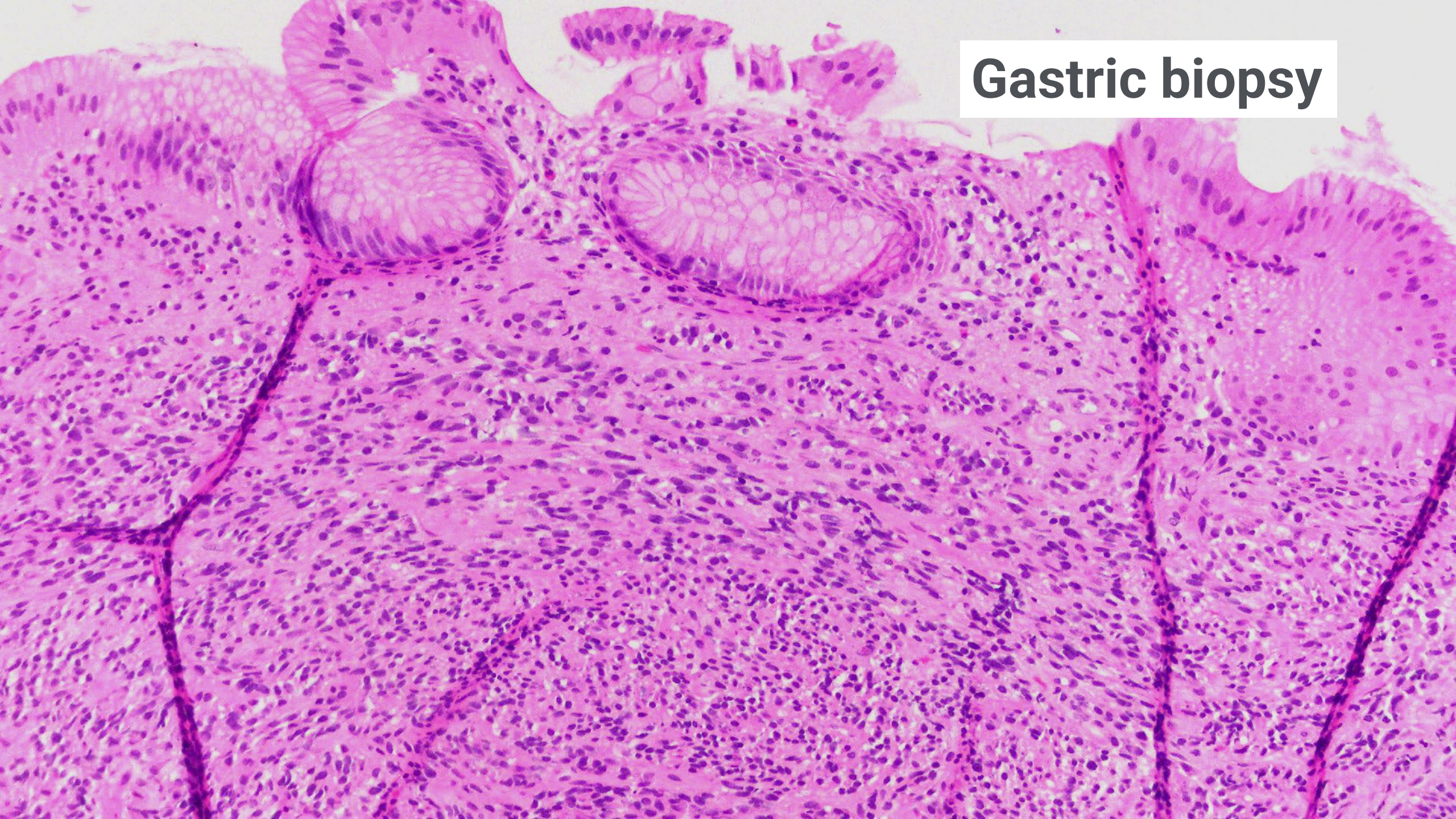
**EMA  
Positive**

**HHV8 Positive**

# Mucosal spindle cell lesions



# Gastric biopsy



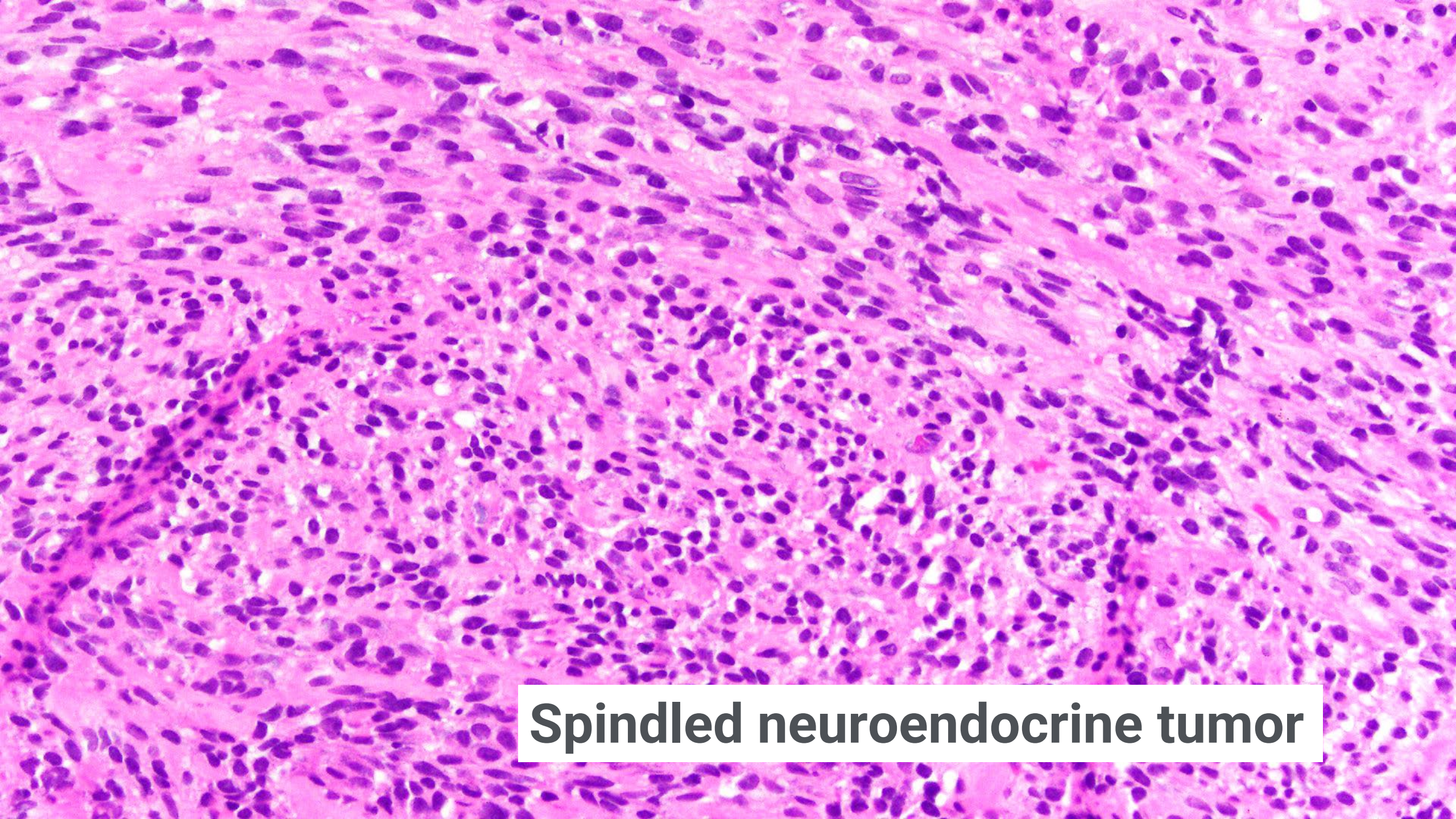


A histological slide showing a spindled neuroendocrine tumor. The tumor cells are arranged in nests and cords, with a characteristic spindled morphology. The cells are stained with hematoxylin and eosin (H&E), showing blue nuclei and pink cytoplasm/extracellular matrix. The tumor is surrounded by a dense, fibrous stroma. The overall appearance is that of a well-differentiated neuroendocrine neoplasm.

**Chromogranin**

**Spindled neuroendocrine tumor**





**Spindled neuroendocrine tumor**



# Submucosal Tumors

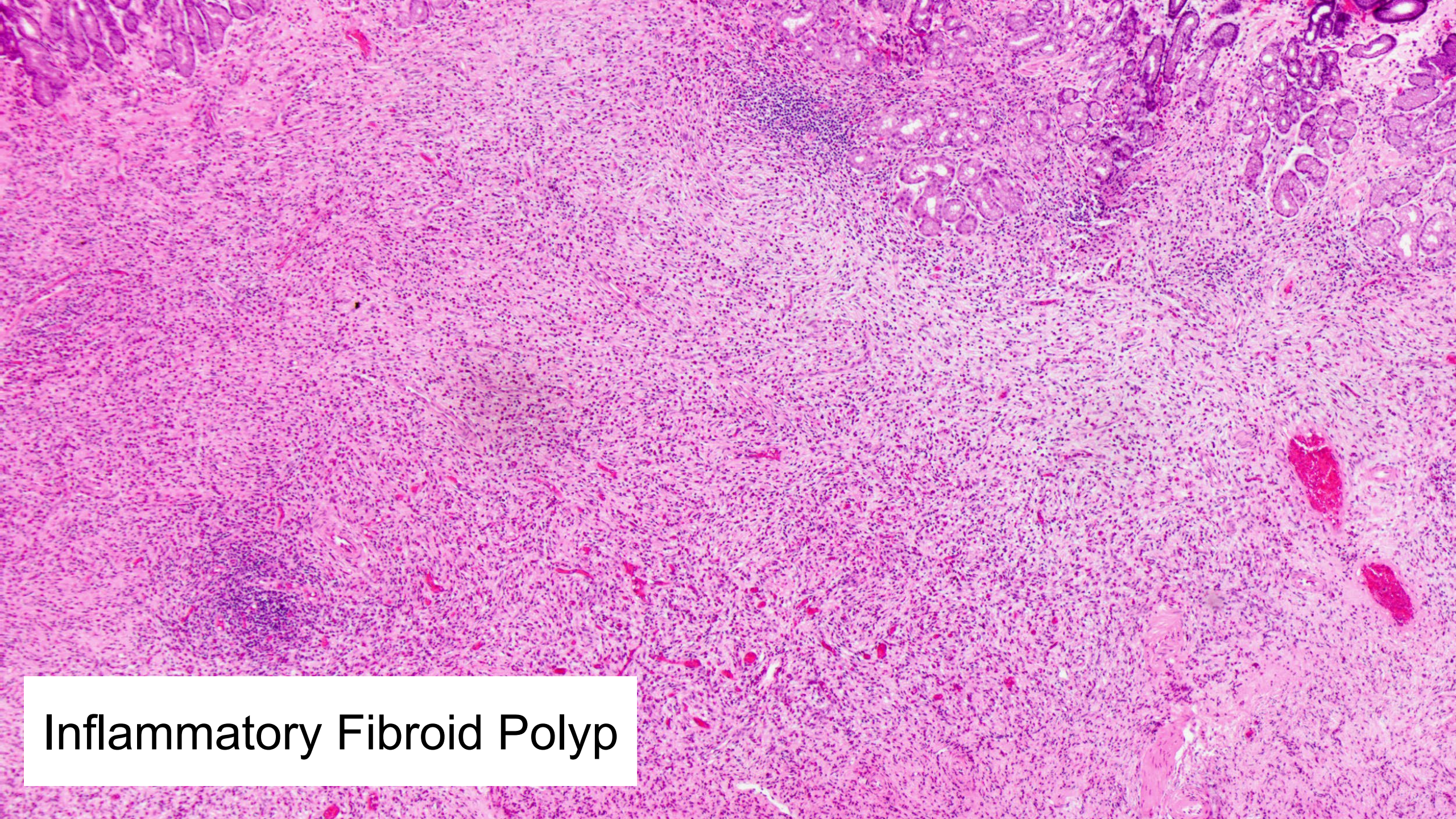




# Inflammatory Fibroid Polyp

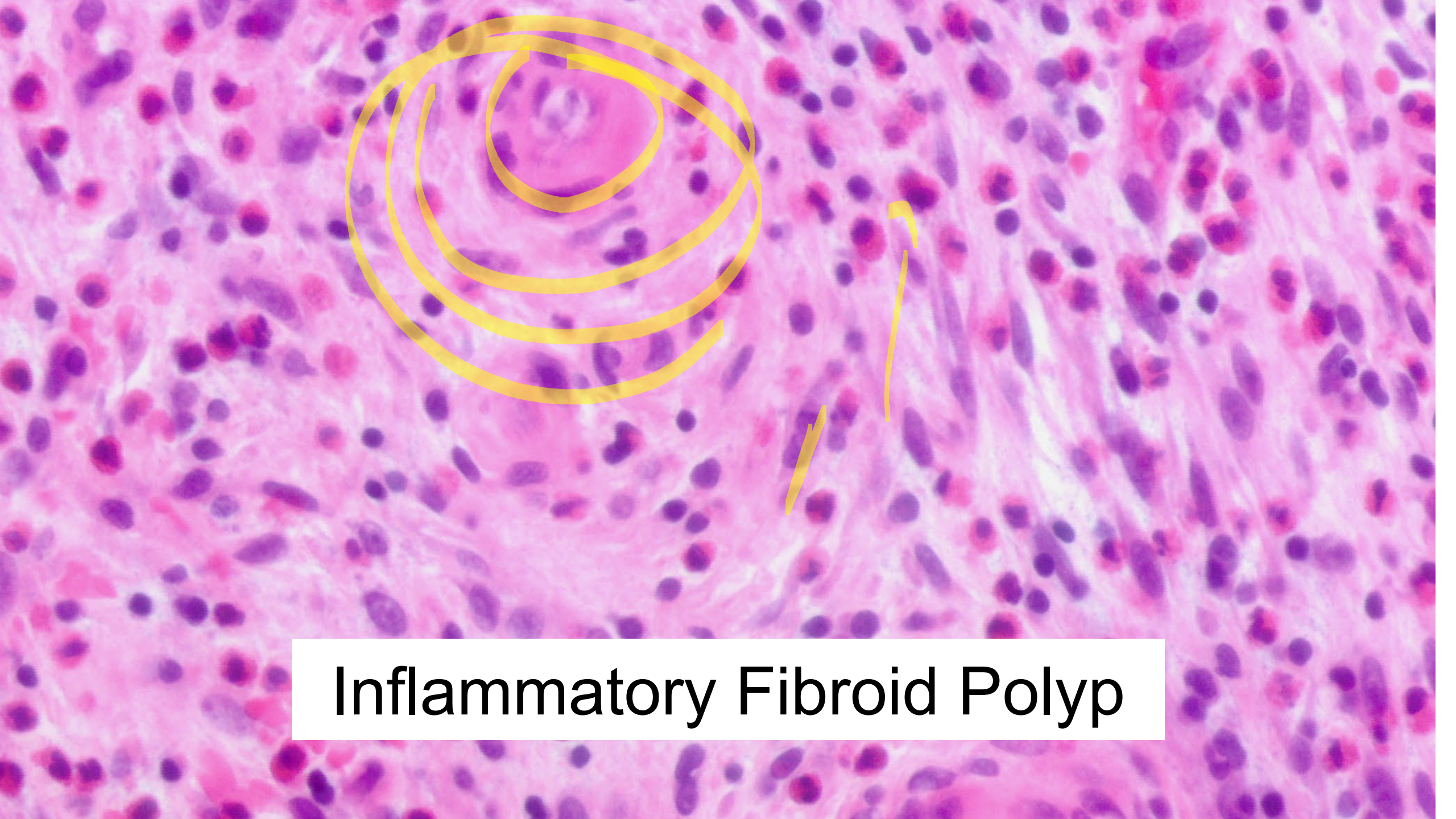
- Benign stromal tumor
- Gastric antrum > distal ileum >> esophagus, colon, proximal small bowel
- Activating PDGFRA mutations in over half cases





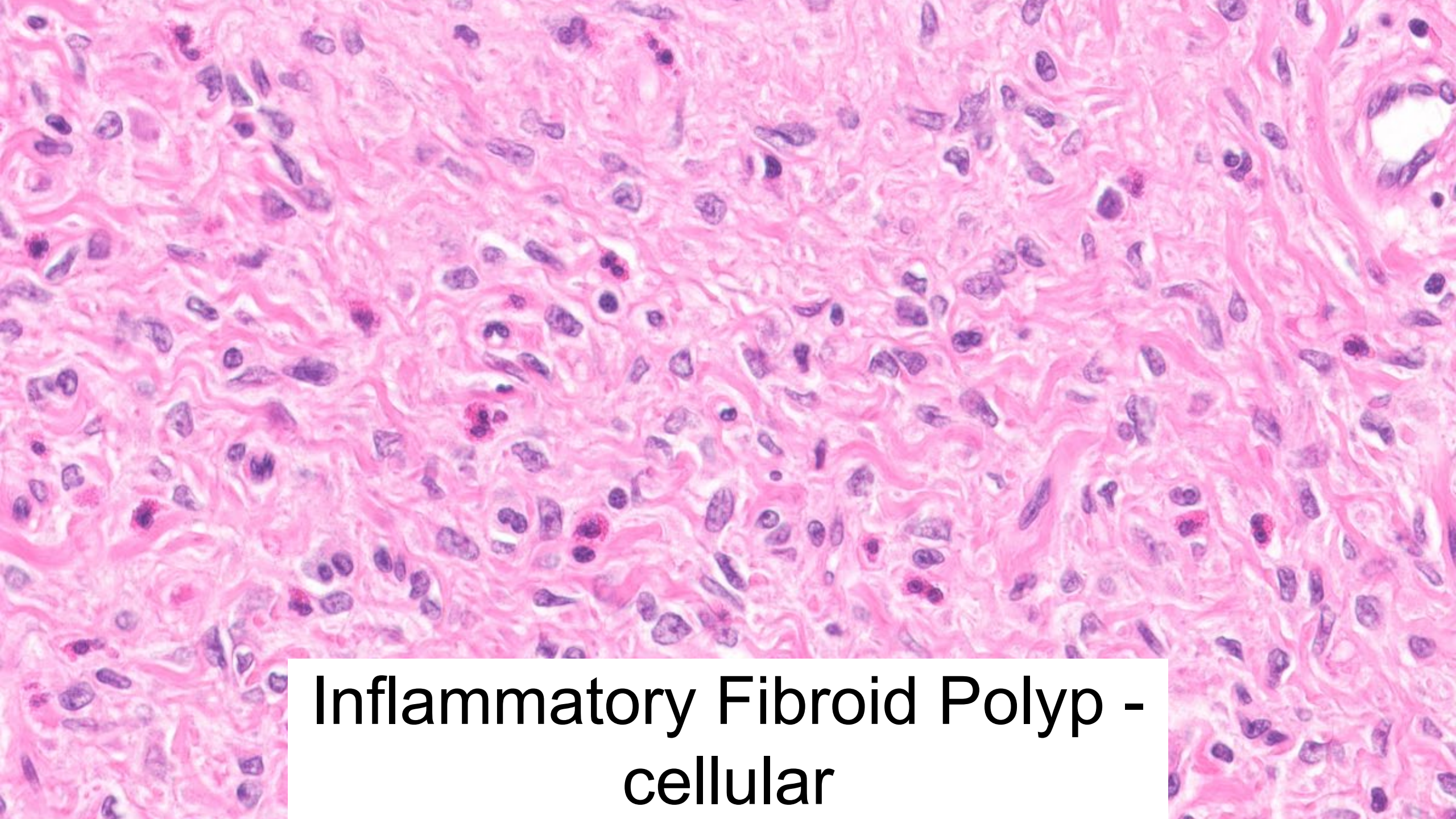
Inflammatory Fibroid Polyp





Inflammatory Fibroid Polyp





**Inflammatory Fibroid Polyp -  
cellular**



# Inflammatory Fibroid Polyp

A high-magnification photomicrograph of an inflammatory fibroid polyp. The tissue is characterized by a dense, cellular reaction. The stroma is composed of numerous spindle-shaped cells, likely fibroblasts, which are arranged in a somewhat disorganized pattern. The cells have elongated nuclei and are surrounded by a network of fine, eosinophilic (pink) fibers. The overall appearance is that of a highly cellular, fibrous lesion.

PDGFRA



# The World of Fusions



MASSACHUSETTS  
GENERAL HOSPITAL



HARVARD  
MEDICAL SCHOOL



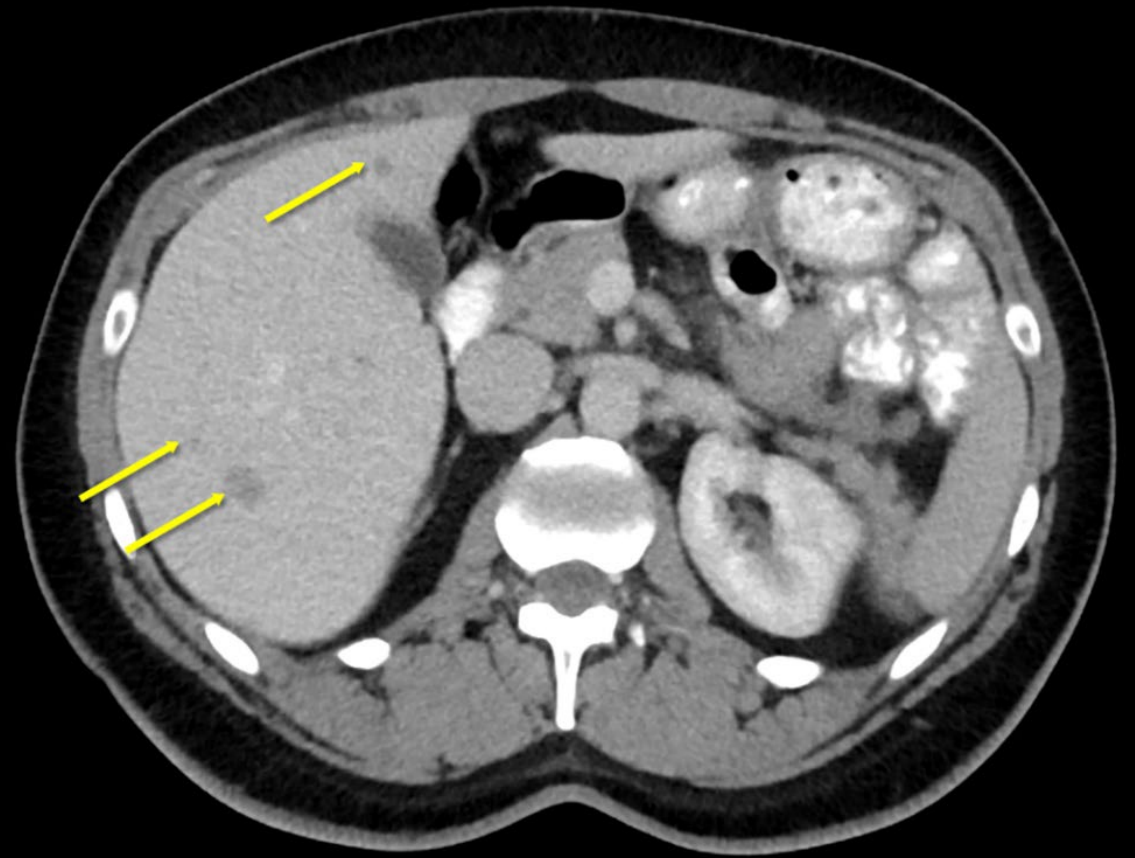
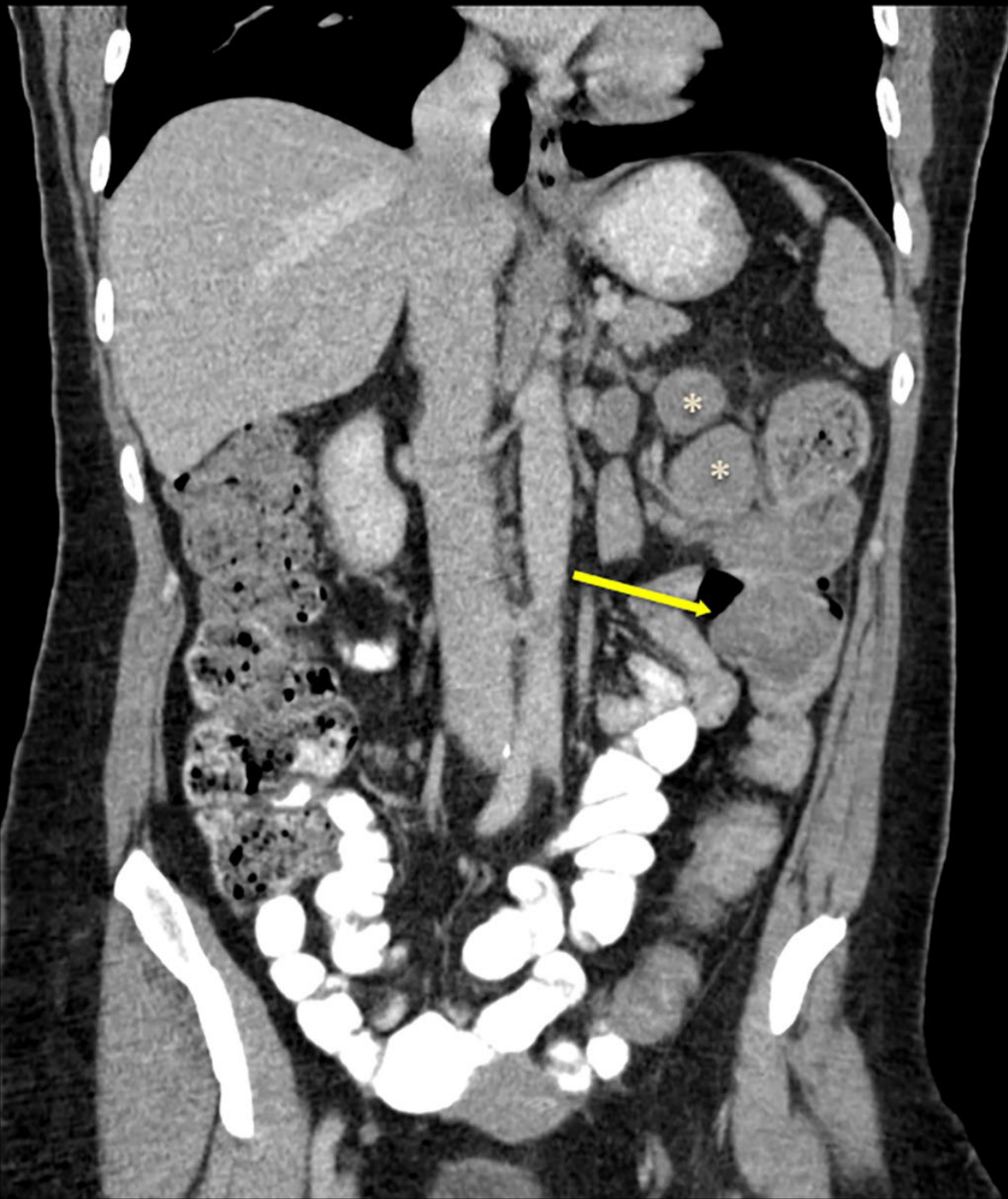
# NUTM1-Rearranged Sarcoma

- Extremely rare
- No age or sex predilection
- Spindled, epithelioid/rhabdoid and hyalinized/nested patterns
- Express keratins (weak, patchy) and NUTM1 protein
- Negative for other tested markers; SMARCB1-retained
- *MDX4-NUTM1*
- *summucoxa*
- Aggressive sarcomas with locoregional/distant metastases and poor outcome

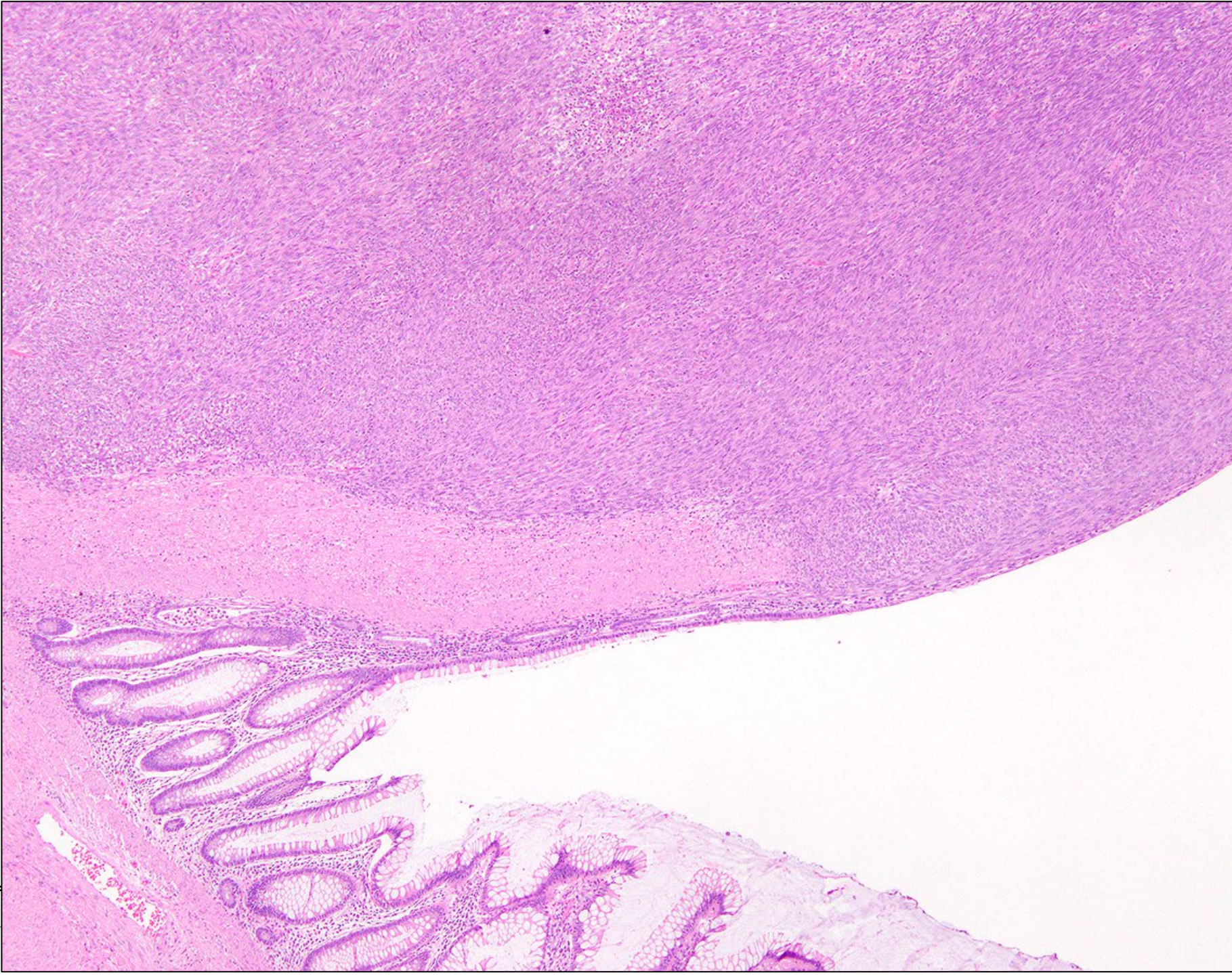




# Andrew Folpe

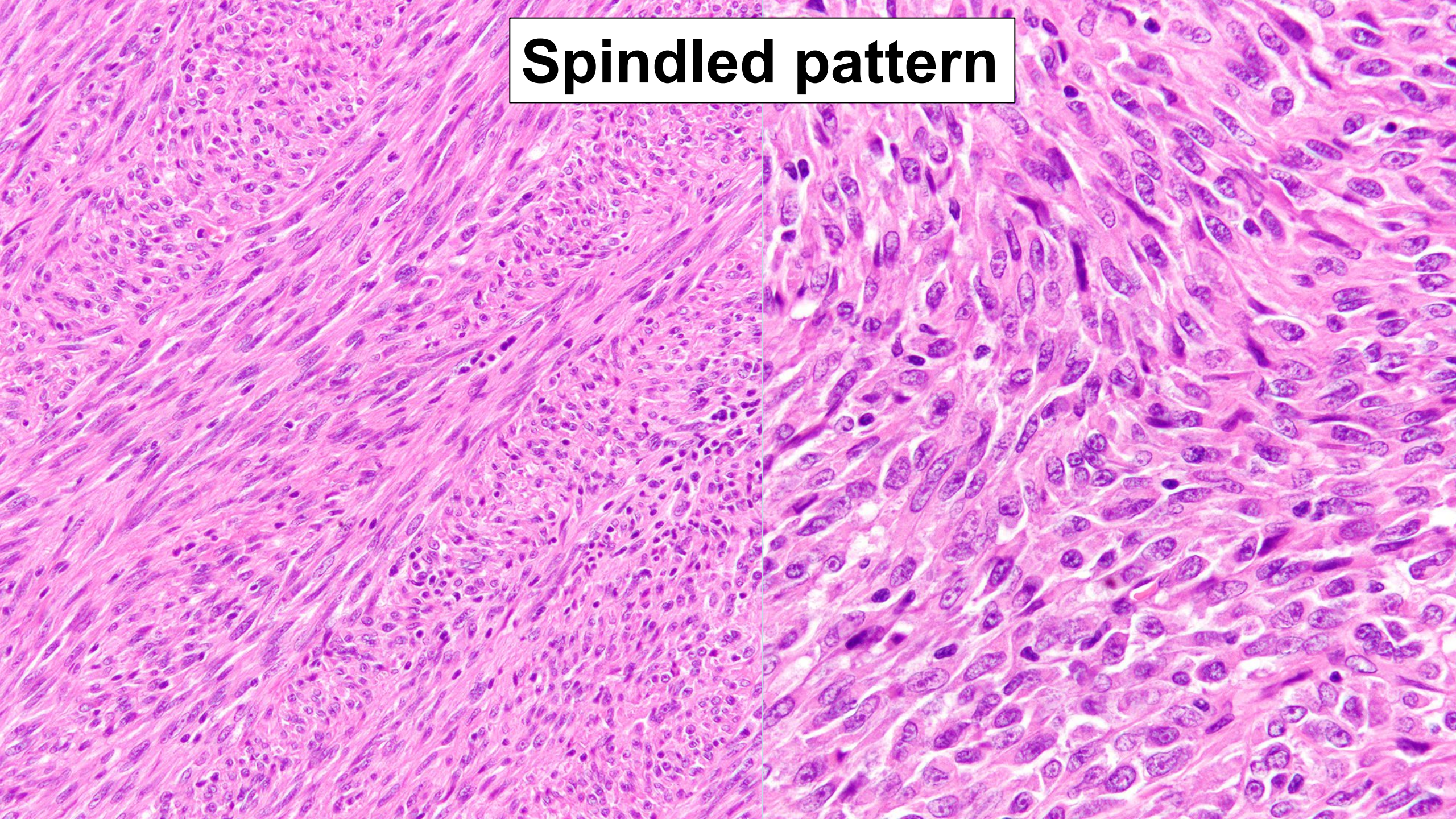






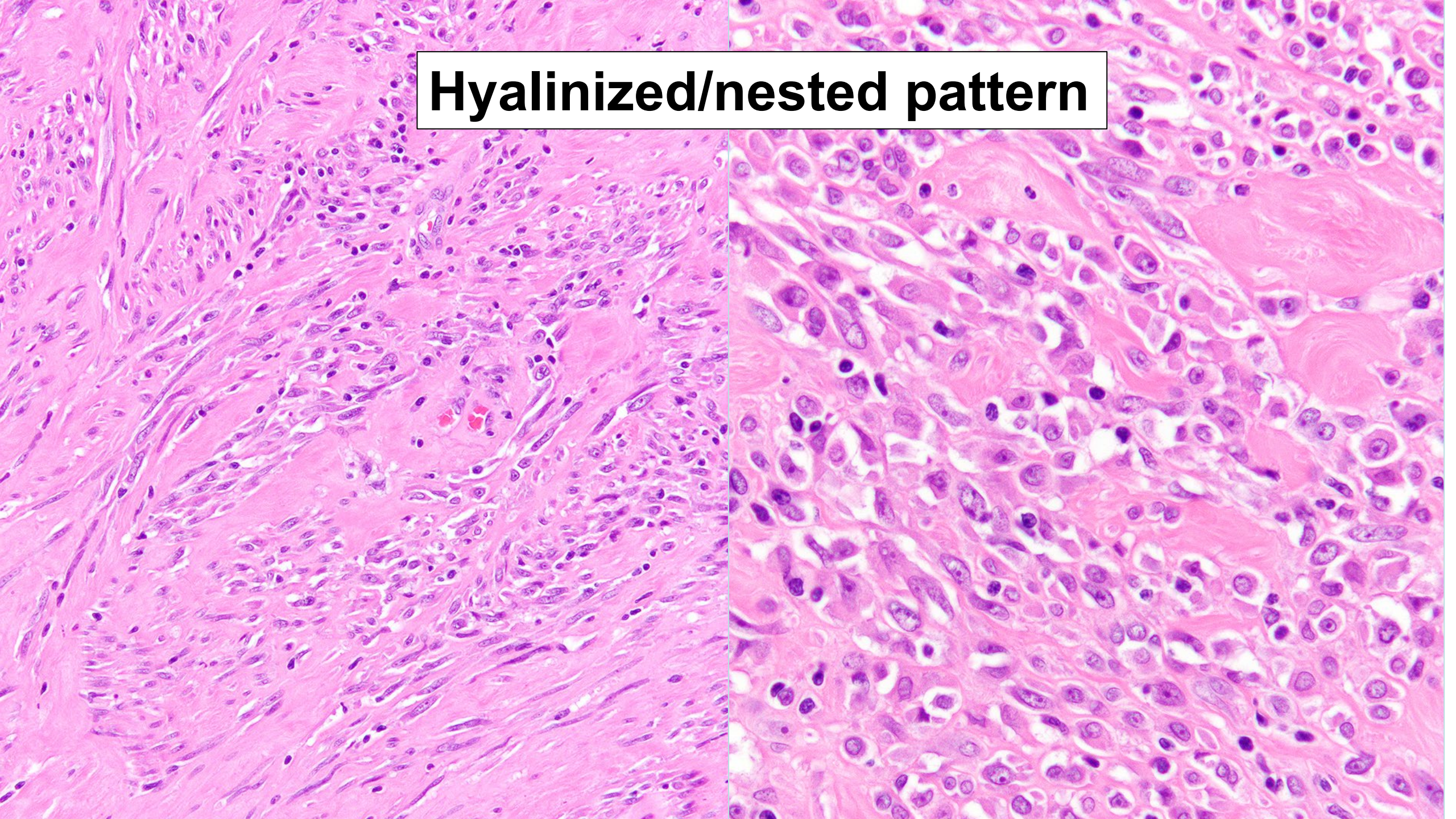


# Spindled pattern



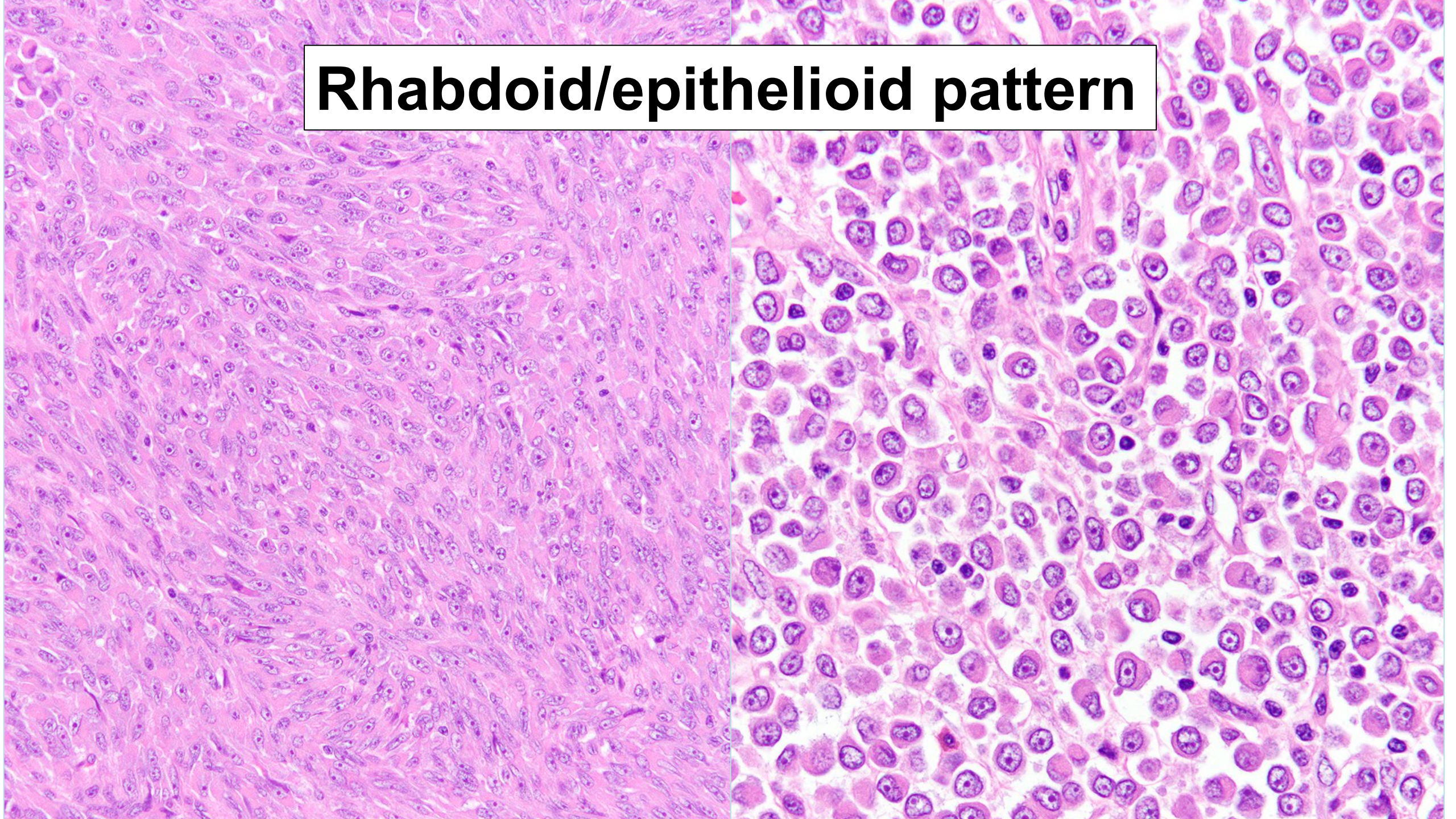


# Hyalinized/nested pattern

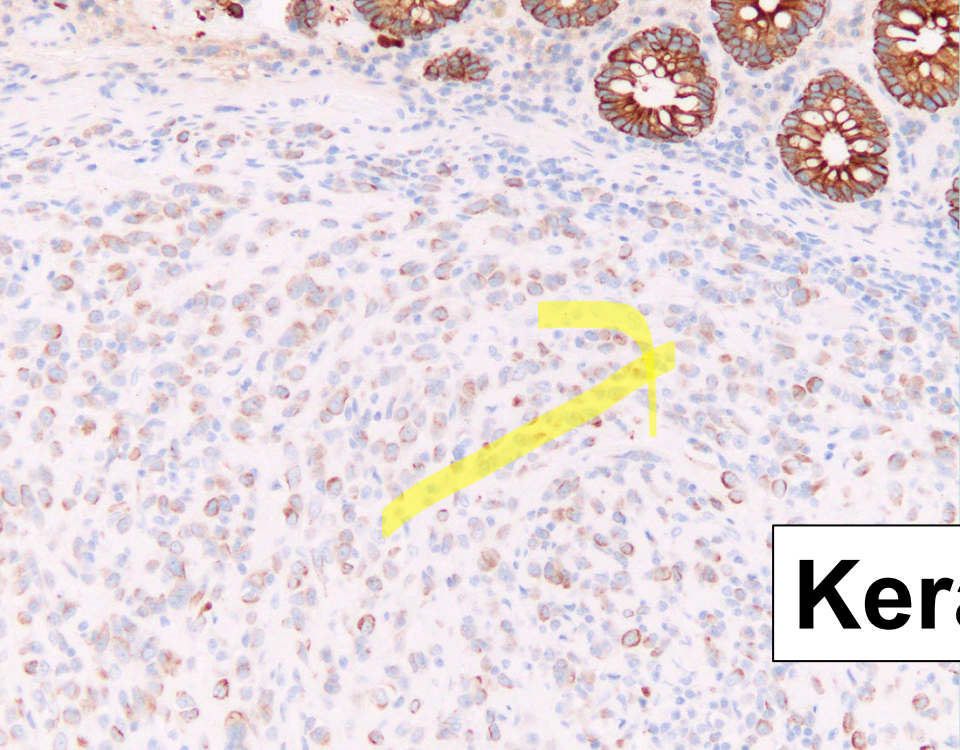




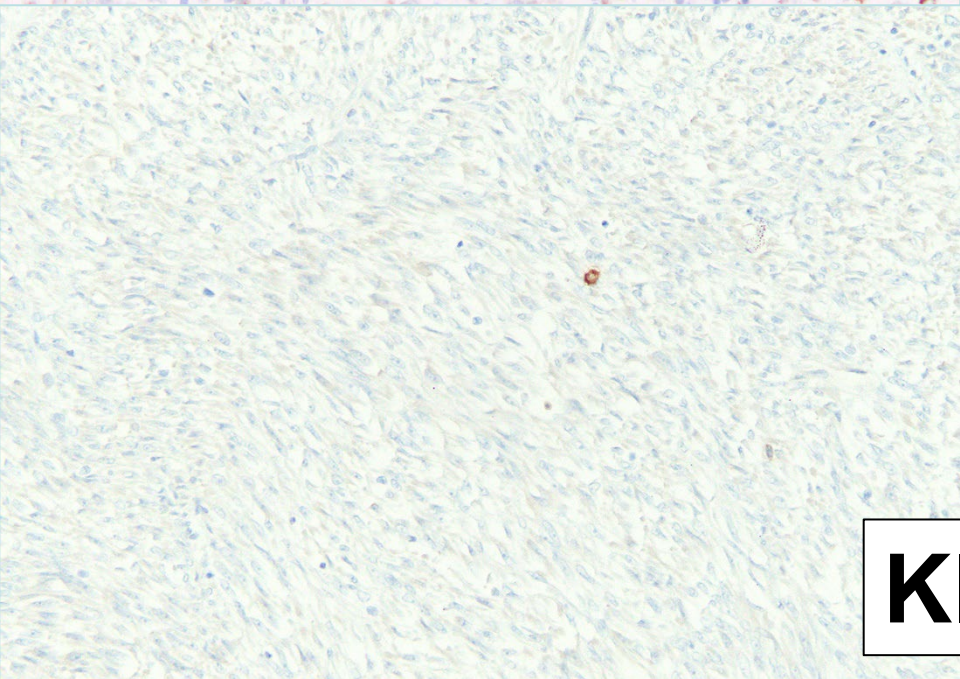
# Rhabdoid/epithelioid pattern





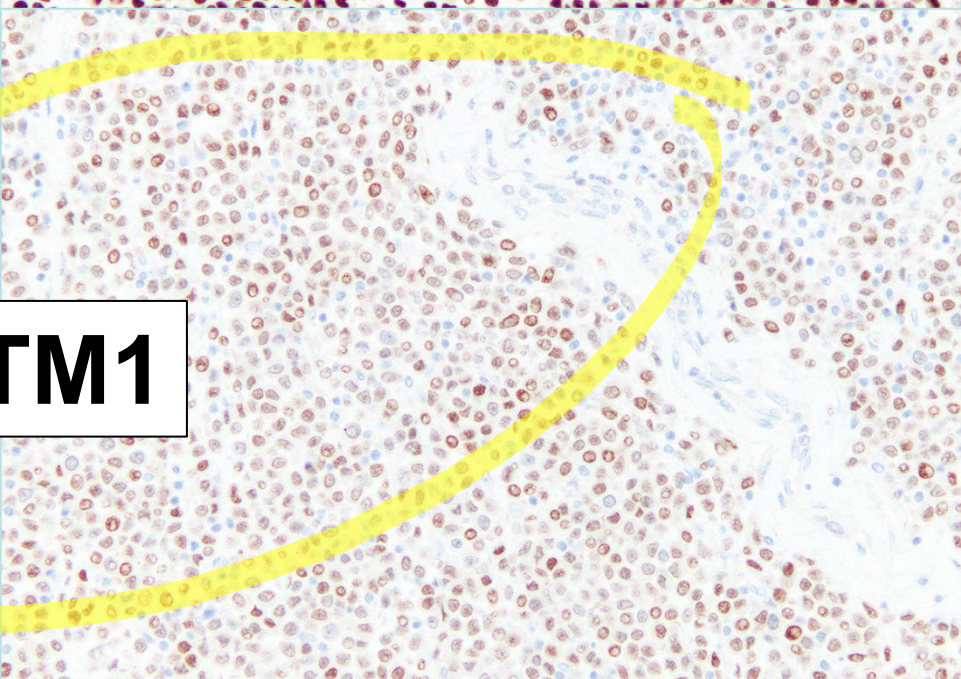
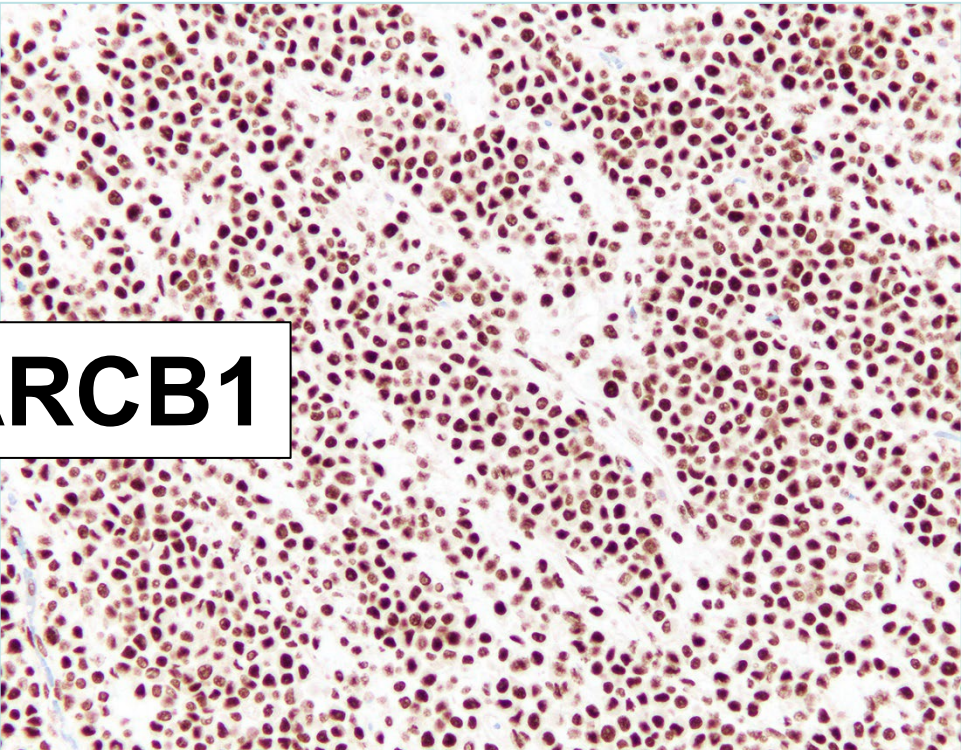


**Keratin**

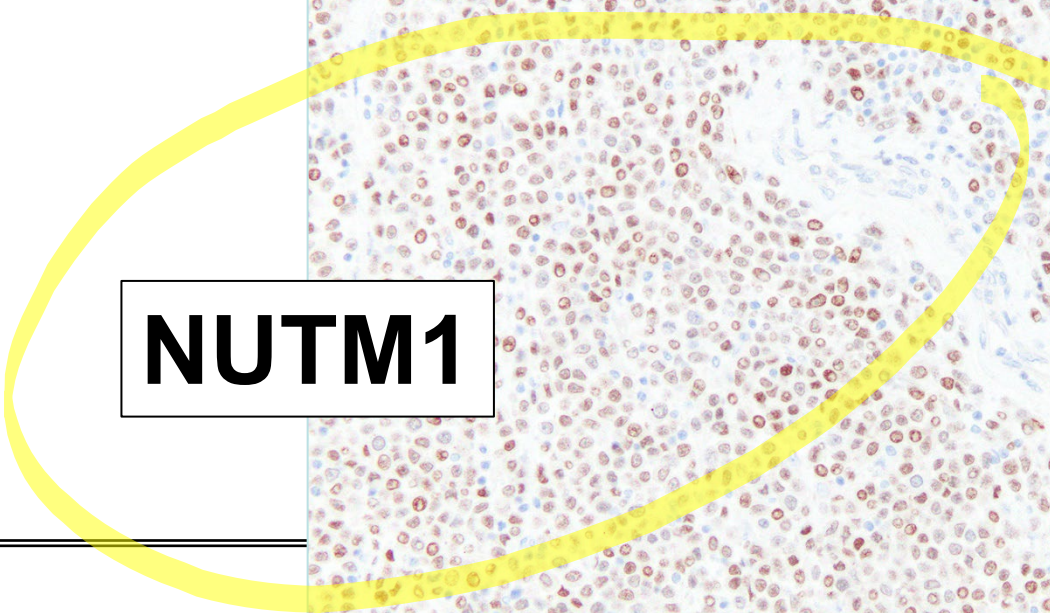

**KIT**

**SMARCB1**



**NUTM1**





# NUTM1-Rearranged Sarcoma

NUTM1







<https://www.youtube.com/c/vikramdeshpandePathology>

**@Vik\_Deshpande**



MASSACHUSETTS  
GENERAL HOSPITAL



HARVARD  
MEDICAL SCHOOL